SAKARYA ÜNİVERSİTESİ

TÜBİTAK

Türk Histoloji ve Embriyoloji Derneği THED Ankara 1990

niche 2024

16th NATIONAL AND 2nd INTERNATIONAL CONGRESS OF HISTOLOGY AND EMBRYOLOGY

26-28 SEPTEMBER 2024

SAKARYA UNIVERSITY



ATLAX

CONGRESS BOOK

nichecongress.com turkhistolojiembriyoloji

CONGRESS BOOK

EDITOR

Prof. Dr. Gamze TANRIÖVER
Congress President

Turkish Society of Histology and Embryology
THED

2024

16TH NATIONAL AND 2ND INTERNATIONAL CONGRESS OF HISTOLOGY AND EMBRYOLOGY
(NICHE 2024)

26-28 September 2024
SAKARYA/TÜRKİYE

This book is subject to copyright. All copyrights reserved. No part of this publication may be stored, reproduced or transmitted in any form or by any means, electronic, mechanical, reprographic or photographic, without the prior written permission of the publisher.

Personal contributions to this publication and any liabilities arising therefrom are the responsibility of the authors. The publisher is not liable for any possible damages that may result from the content obtained from this publication.

https://www.nichecongress.com

CONGRESS CHAIRMAN

- **Prof. Dr. Gamze TANRIÖVER**
  Akdeniz University Faculty of Medicine, Department of Histology and Embryology

CONGRESS ORGANISING COMMITTEE

- Prof. Dr. Gamze TANRIÖVER
  Akdeniz University Faculty of Medicine
  Department of Histology and Embryology

- Prof. Dr. Altuğ YAVAŞOĞLU
  Ege University Faculty of Medicine
  Department of Histology and Embryology

- Prof. Dr. Alev Gürol BAYRAKTAROĞLU
  Ankara University Faculty of Veterinary Medicine
  Department of Histology and Embryology

- Prof. Dr. Fevziye Figen KAYMAZ
  İstinye University Faculty of Medicine
  Department of Histology and Embryology

- Prof. Dr Feyzullah BEYAZ
  Erciyes University
  Faculty of Veterinary Medicine Histology and Embryology

- Prof. Dr Aylin YABA UÇAR
  Yeditepe University
  Faculty of Medicine, Department of Histology and Embryology

- Dr. Süleyman EROL
  Republic of Turkey Ministry of Health Etlik Zübeyde Hanım Gynaecology and Obstetrics E.A.

- Assistant Prof. Süheyla Esra ÖZKOÇER
  Gazi University
  Faculty of Medicine, Department of Histology and Embryology

- Assistant Prof. Çağla Zübeyde KÖPRÜ
  Yüksek İhtisas University
  Faculty of Medicine, Department of Histology and Embryology

- Assoc. Prof. Dr. Gamze GÜNEY ESKİLER
  Sakarya University Rector Consultant
  Sakarya University Faculty of Medicine

- Prof. Dr. Elvan ŞAHİN
  Sakarya University
  Faculty of Medicine Histology and Embryology

CONGRESS SCIENTIFIC COMMITTEE

- Prof. Dr. Adem KARA
  Erzurum Technical University Molecular Biology and Genetics
- Prof. Dr. Ahmet Çevik TUFAN
  Gülhane Faculty of Medicine
- Prof. Dr. Aydın GİRGİN
  Bingöl University Faculty of Veterinary Medicine
- Prof. Dr. Aysel GÜVEN BAĞLA
  Çanakkale Onsekiz Mart University
- Prof. Dr. Aysel KÜKNER
  Near East University Faculty of Medicine
- Prof. Dr. Ayşegül UYSAL
  Ege University
- Prof. Dr. Ayten TÜRKKANI
  Gülhane Faculty of Medicine
- Prof. Dr. Berrin TARAKÇI GENÇER
  Fırat University Faculty of Veterinary Medicine
- Prof. Dr. Bülent AHISHALI
  Koç University
- Prof. Dr. Ebru KARADAĞ SARI
  Kafkas University Faculty of Veterinary Medicine
- Prof. Dr. Elif GÜZEL MEYDANLI
  İstanbul University Faculty of Medicine
- Prof. Dr. Elvan ŞAHİN
  Sakarya University Faculty of Medicine
- Prof. Dr. Engin YENILMEZ
  Karadeniz Technical University
- Prof. Dr. Feriha ERCAN
  Marmara University
- Prof. Dr. Feyzullah BEYAZ
  Erciyes University
- Prof. Dr. Fikret GEVREK
  Gaziosmanpaşa University Faculty of Medicine

- Prof. Dr. Gözde ERKANLI ŞENTÜRK
  Cerrahpaşa University
- Prof. Dr. Gulcin ABBAN METE
  Pamukkale University
- Prof. Dr. Hülya ÇETİN
  Pamukkale University
- Prof. Dr. Hüseyin AKTUĞ
  Ege University
- Prof. Dr. İlknur KESKİN
  İstanbul Medipol University
- Prof. Dr. Kemal ÖZBİLGİN
  Celal Bayar University
- Prof. Dr. Mehmet Faruk AYDIN
  Balıkesir University Faculty of Veterinary Medicine
- Prof. Dr. Melda YARDIMOĞLU YILMAZ
  Kocaeli University
- Prof. Dr. Meltem Kuruş
  İzmir Katip Çelebi University
- Prof. Dr. Meral KOYUTÜRK
  Cerrahpaşa University Faculty of Medicine
- Prof. Dr. Mukaddes Eşrefoğlu
  Bezmiâlem Vakıf University Faculty of Medicine
- Prof. Dr. Narin LİMAN
  Erciyes University Faculty of Veterinary Medicine
- Prof. Dr. Nuray ACAR AYDEMIR
  Akdeniz University Faculty of Medicine
- Prof. Dr. Nurettin CENGİZ
  Bandırma Onyedi Eylül University
- Prof. Dr. Özhan EYIGÖR
  Bursa Uludag University
- Prof. Dr. Petek KORKUSUZ
  Hacettepe University
- Prof. Dr. Saffet ÖZTÜRK
  Akdeniz University
- Prof. Dr. Sait POLAT
  Çukurova University

- Prof. Dr. Seda VATANSEVER
  Celal Bayar University
- Prof. Dr. Selma YILMAZER
  Haliç University
- Prof. Dr. Selçuk TUNİK
  Dicle University
- Prof. Dr. Selen AKYOL BAHÇECİ
  İzmir Katip Çelebi University
- Prof. Dr. Sema TİMURKAAN
  Fırat University Faculty of Veterinary Medicine
- Prof. Dr. Serap ARBAK
  Acıbadem University
- Prof. Dr. Serap CİLAKER MIÇILI
  Dokuz Eylul University
- Prof. Dr. Serpil ÜNVER SARAYDIN
  Cumhuriyet University Faculty of Medicine
- Prof. Dr. Sevda ELİŞ YILDIZ
  Kafkas University
- Prof. Dr. Sevinç INAN
  İzmir Economy University
- Prof. Dr. Süheyla GONCA
  Kocaeli University
- Prof. Dr Yeter TOPÇU TARLADAÇALIŞIR
  Trakya University
- Prof. Dr Yiğit UYANIKGİL
  Ege University
- Assoc. Prof. Dr Başak YAVUZ
  İzmir Demokrasi University
- Assoc. Prof. Dr. Eda AÇIKGÖZ
  Van Yuzuncu Yil University
- Assoc. Prof. Dr Fatma FIRAT
  Afyonkarahisar University
- Assoc. Prof. Dr. Gül İpek GÜNDOĞAN
  İstanbul Yeni Yuzyil University
- Assoc. Prof. Dr İsmail CAN
  Kafkas University Faculty of Medicine

- Assoc. Prof. Dr. Leman SENCAR
  Çukurova University
- Assoc. Prof. Dr. M. Başak TUNALI
  İstanbul University Faculty of Veterinary Medicine
- Assoc. Prof. Dr. Merve AÇIKEL ELMAS
  Acıbadem University
- Assoc. Prof Dr Nazlı Ece ORDUERİ
  Biruni University
- Assoc. Prof. Dr. Neşe ÇÖLÇİMEN
  Van Yuzuncu Yil University
- Assoc. Prof. Dr. Özlem Tuğçe ÇİLİNGİRKAYA
  Marmara University
- Assoc. Prof. Dr. Seda ÖZBAL
  Dokuz Eylul University
- Assoc. Prof. Dr. Semin GEDİKLİ
  Atatürk University Faculty of Veterinary Medicine
- Assoc. Prof. Dr Tolga MERCANTEPE
  Recep Tayyip Erdogan University
- Assoc. Prof. Dr. Tuba DEMİRCİ
  Atatürk University
- Assoc. Dr Tuba PARLAK AK
  Munzur University Department of Nutrition and Dietetics
- Assoc. Prof. Dr Yurdun KUYUCU
  Çukurova University
- Assoc. Prof. Dr. Züleyha DOĞANYİĞİT
  Yozgat Bozok University
- Assoc. Prof. Dr. Züleyha ERİŞGİN
  Giresun University
- Assistant Prof. E. Nazlı HAYIRLI ÖZYOL
  Hitit University
- Assistant Prof. Elif GELENLİ DOLANBAY
  İstanbul Medeniyet University Faculty of Medicine
- Assistant Prof. Gizem İLTER AKTAŞ
  Yüksek İhtisas University Faculty of Medicine
- Assistant Prof. Hale BAYRAM
  Maltepe University

- Assistant Prof. Işınsu ALKAN
  Nevşehir Haci Bektas Faculty of Medicine
- Assistant Prof. İhsan KARABOĞA
  Kırklareli University
- Assistant Prof. Nazlı CAN
  Muğla Sıtkı Koçman University
- Assistant Prof. Nilüfer ULAŞ AYTÜRK
  Çanakkale Onsekiz Mart University
- Assistant Prof. Oya KORKMAZ
  Malatya Turgut Ozal University Faculty of Medicine
- Assistant Prof. Pakize Nur AKKAYA
  Balikesir University
- Assistant Prof. Seçil Nazife PARLAK
  Ağrı İbrahim Çeçen University
- Dr Assistant Prof. Seda YAKUT
  Mehmet Akif Ersoy University Faculty of Veterinary Medicine
- Dr Assistant Prof. Semih TAN
  Ordu University
- Assistant Prof. Süheyla Esra ÖZKOÇER
  Gazi University Faculty of Medicine
- Assistant Prof. Tuba ÖZDEMİR SANCI
  Yıldırım Beyazıt University
- Dr Assistant Prof. Zeliha YETİM
  Hamidiye International Medical Faculty

Dear Members of the Turkish Histology and Embryology Family,

16th National and 2nd International Congress of Histology and Embryology (NICHE2024; 16th **N**ational and 2nd **I**nternational **C**ongress of **H**istology and **E**mbryology) will be organised by the Turkish Society of Histology and Embryology between 26-28 September 2024 at Turgut Özal Culture and Congress Centre hosted by Sakarya University. We are very pleased to invite you to our congress.

After all the misfortunes experienced in the previous periods; as the 17th Term Executive Board of the Turkish Society of Histology and Embryology, we are making great efforts to organise this congress face to face. At the end of a long period of forced separation, I would like to share the information that we will continue our 16th National Histology and Embryology Congress in our International Congress, which we will organise face-to-face, as in the old days, and that it will be held in a separate hall in Turkish.

In addition to the conferences of valuable researchers who have a say in their fields, our congress, which will include sessions where the results of current research will be shared and expert scientists from abroad will be invited, will be held with your valuable participation. In this sense, we are experiencing the joy and excitement of meeting you in the beautiful atmosphere of Sakarya.

NICHE2024; In the 16th National and 2nd International Histology and Embryology Congress, it is aimed to create a scientific environment with interdisciplinary contributions on current issues that are of great interest to us such as developmental biology, molecular biology and cell biology, stem cells, cellular therapies, regenerative medicine, assisted reproduction techniques, tumour biology, biomedical engineering and neuroscience, neuroendocrinology.

Our congress will be organised in accordance with the international congress conditions, and the condition that abstract and full text papers will be included in the congress booklet and presented as published full text will be fulfilled.

I would like to invite you to NICHE2024; 16th National and 2nd International Congress of Histology and Embryology, which we are sure will be scientifically enriched with your participation and the knowledge and experiences you will share, and I present my deepest love and respect.

Prof. Dr. Gamze TANRIÖVER
Congress President

PROF. DR. EMİN KANSU



Hacettepe University, Cancer Institute, Basic Oncology Department
"Nobel Prizes and Significance of Curiosity in Science"

PROF. DR. ALP CAN



Ankara University Faculty of Medicine Histology and Embryology Department
"The History of Histology from Today's Perspective"

PROF. DR. EMRE YAKŞİ



Kavli Institute for Systems Neuroscience, NTNU, Trondheim, Norway
"The Importance of Astroglia in the Generation and Propagation of Epileptic Seizures"

PROF. DR. ERTUĞRUL KILIÇ



Istanbul Medeniyet University, Faculty of Medicine, Dept. of Physiology
"The Effect Of Post-Weaning Social Isolation On The Development Of Brain Injury And Inflammation"

PROF. DR. NİYAZİ ACER



İstanbul Arel University, Faculty of Medicine, Department of Anatomy, İstanbul
"Automated Segmentation of Thalamic Nuclei Using FreeSurfer and CAT12"

PROF. DR. YASEMİN GURSOY ÖZDEMİR



Koç University Hospital, Faculty of Medicine
"Neuroinflammation and Blood Brain Barrier in Experimental Allergic Encephalomyelitis Model"

DR. ŞEVİN TURCAN



University of Heidelberg, Department of Neurology, Germany
"Molecular Heterogeneity in IDH Mutant Gliomas"

PROF. DR. KORAY ÖZDUMAN

Professor and Chair of Neurosurgery Acibadem University, School of Medicine Istanbul-Turkey
"Our Current Understanding of Glioma Biology"



PROF. DR. TUĞBA BAĞCI ÖNDER

Koç University, Faculty of Medicine
"Epigenetic Regulation of Therapy Response in Glioblastoma"



PROF. DR. AYDAN BULUT KARSLIOGLU

PhD Max Planck Institute for Molecular Genetics , Berlin
"Adjusting The Timing of Mammalian Development"



PROF. DR. DENNY SAKKAS

CSO at Boston IVF, Waltham MA, USA
"Live imaging of human embryos: What Lies Below the Surface?"



ASSOC. PROF. JOSHUA JOHNSON

Division of Reproductive Sciences Department of Obstetrics and Gynecology University of Colorado Denver (AMC), USA
"Understanding Patterns of Female Reproductive Aging"



PROF. DR. NUREDDIN ASHAMMAKHI

Institute for Quantitative Health Science and Engineering (IQ), Michigan State University, USA
"Integrating Technologies To Lead Innovations And Applications For Personalised Health"



PROF. DR. AHMET ÇEVİK TUFAN



University of Health Sciences, Gulhane Faculty of Medicine, Department of Histology and Embryology, Ankara, Turkey.
"Stem Cell Applications in Bone Fracture Healing"

PROF. DR. KAMİL CAN AKÇALI



Director, Ankara University Stem Cell Institute
"Promise of Health For All: Induced Pluripotent Stem Cells (iPSCs)"

PROF. DR. YANNIS MISSIRLIS



Laboratory of Biomechanics and Biomedical Engineering Mechanical Engineering & Aeronautics Dept. University of Patras, Greece
"Information Flow in Cells, Tissues And Tissue Engineering"

PROF. DR. ÜMİT ALİ KAYIŞLI



South Florida Morsani College of Medicine
"Recent Methodological Advancements in Molecular Histology and Embryology"

DR. İSMAİL EŞ



University of Oxford, Institute of Biomedical Engineering
"Minimally Invasive Biomedical Tools For The Treatment Of Neurological Conditions"

PROF. DR. DAVOR JEZEK



University of Zagreb, Croatia
"Leydig Cells in Men With Non- Obstructive Azoospermia"

DR. MURAT BAŞAR



Yale University, School of Medicine
"Non-Invasive Methods For Predicting Implantation Potential And Ploidy Status in Pre-Implantation Embryo"

PROF. DR. SAFFET ÖZTÜRK



Department of Histology and Embryology, Akdeniz University School of Medicine
"The Relationship Between Female Fertility Loss During Ovarian Aging And DNA/Histone Methylation Changes"

ASSOC. PROF. DR. FERDA TOPAL ÇELİKKAN



Ankara University Faculty of Medicine Histology and Embryology Department
"Exosomes Derived From Human Umbilical Cord Multipotent Stromal Cells Enhance Angiogenesis"

PROF. DR. AYTEN TÜRKKANI



Health Sciences University Gülhane Faculty of Medicine Department of Histology Embryology
"The Role of Exosomes in Infertility"

PROF. DR. HÜSEYİN AKTUĞ



Ege University, Faculty of Medicine, Department of Basic Medical Sciences, Department of Histology and Embryology
"Cell Dynamics and Cell Behaviour"

PROF. DR. NURAY ACAR AYDEMIR



Akdeniz University, Faculty of Medicine, Department of Histology and Embryology
"Deciphering the Implantation Code: Clues from Mouse Models"

PROF. DR. SEDA VATANSEVER



Department of Histology and Embryology, Manisa Celal Bayar University, Faculty of Medicine
"Relationship of Exosome which is the Rising Star in Medicine with Cell Death"

PROF. DR. SİNAN ÖZKAVUKÇU



Bahceci Health Group
"Embryo Staging and Selection Methods"

ASISST PROF. HAKAN DARICI



Istinye University, Faculty of Medicine, Department of Histology and Embryology
"Alternative Uses of The Stem Cells: Modelling and Treating Diseases With Genetically Modified Stem Cells"

DR. CAN KÖSE



Izmir City Hospital, IVF Centre Embryology Laboratory
"Sperm Selection Methods"

ASSOCIATE PROFESSOR DR. EVRİM ÜNSAL



Department of Medical Genetics, Faculty of Medicine, Yüksek İhtisas University
"Genetic Diagnosis Methods in IVF"

Education Session - Information Meeting on Medical Speciality and RCC

PROF. DR. DİLARA ZEYBEK



Hacettepe University, Faculty of Medicine, Department of Histology and Embryology
"Working Report of Assessment and Evaluation (Exam) Commission of The Medical Specialty Qualification Executive Board- Turkish Histology and Embryology Society"

PROF. DR. OYA EVIRGEN



Ankara University, Faculty of Medicine, Department of Histology Embryology
"Speciality Education and Turkish Society of Histology and Embryology Medical Speciality Qualification Executive Committee Working Report"

Education Session - Postgraduate Education Information



PROF. DR. AYŞEGÜL UYSAL

Ege University, Faculty of Medicine, Department of Histology and Embryology
"Quality Processes in Doctoral Education"



PROF. DR. SAİT POLAT

Çukurova University Faculty of Medicine Histology and Embryology Department
"Current Perspective on Doctoral Education in Health Sciences of Turkey"



PROF. DR. ŞAHİN SIRMALI

Sanko University, Faculty of Medicine, Department of Histology and Embryology
"University Reform in Turkey"

Index

2ND INTERNATIONAL CONGRESS OF HISTOLOGY AND EMBRYOLOGY 26

Live Imaging Of Human Embryos: What Lies Below The Surface? 27

Exosomes Derived From Human Umbilical Cord Multipotent Stromal Cells Enhance Angiogenesis 28

Minimally Invasive Drug Delivery Systems And Electrical Stimulation For Neurological Applications 33

Relationship Of Exosome Which Is The Rising Star Medicine With Cell Death 34

The Relationship Between Female Fertility Loss During Ovarian Aging And Dna/Histone Methylation Changes 35

Current Perspective On Doctoral Education In Health Sciences In Türkiye 36

Histological Evaluation Of The Effects Of Intermittent Fasting On Testicular Damage In The Rat Absence Epilepsy Model 39

Histopathological Evaluation Of Alteration Endothelial Cells Of Lungs Vessels Under Influencing Macrophage Migration Inhibitor Factor (Mif) 40

Effect Of Rutin On Chemerin And Enos Expressions İn An Experimental Hypertension Model İn Kidney Tissues Of Rats 41

Evaluation Of Microsatellite Instability (Mlh-1, Pms-2) In Granulosa Cells Of Patients Undergoing In Vitro Fertilization Treatment 42

Synergıstıc Targetıng Of Kras-Mutant Cancers Through Combined Inhibıtıon Of Ldha And Fda-Approved Antıcancer Agents 43

The Effect Of Thymol On Lıver Damage Caused By Subchronıcal Cadmıum Exposure In Rats 44

Modulatory Effects Of Rosa Canına Seed Oıl On Junctıonal Protein Expressıon In The Duodenal Mucosa Of Epıleptıc Rats 45

Assessment Of The Impact Of Amniotic Fluid (Af) As A Perfusion Solution In Pig Livers Experiencing Hypothermic Oxygenated Machine Perfusion (Homp) 46

Investıgatıon Of Hıstological Alteration Caused By N-Methylnitrosoure-Induced Breast Cancer Model On The Ovarian Tissues 48

Hydroxychloroquine Induces Reticulon 4 Expression In Prostate Cancer Cells 49

Lovastatin Synergizes With Got1 Inhibitor To Kill Cancer Cells 50

Therapeutic Effects Of Mesenchymal Stem Cell Conditioned Medium In Rat Varicocele Model 51

Investigation The Effects Of Nimodipine On Experimental Testicular Torsion/Detorsion Model 52

Therapeutic Potential Of Nicotinamide Riboside In Mitigating Muscle Tissue Degeneration Associated With Polycystic Ovary Syndrome: A Histopathological Evaluation 53

Effects Of Tfg-B1 On Aβ-40 And A- B- Γ Secretase Expression In Hippocampus And Prefrontal Cortex In Experimental Alzheimer's Diseases 54

Evaluating The Impact Of Covid-19 On Placental Pathology And Maternal-Foetal Health: A Histopathological And Clinical Analysis..... **Hata! Yer işareti tanımlanmamış.**

The Effects Of Systemic Boric Acid Administration On Embryonic Development İn Pregnant Rats With Experimentally Induced Periodontitis 58

Synergistic Effect Of Benztropine And Ldha Inhibitor In Pancreatic Cancer: A Novel Therapeutic Approach 59

The Human Umbilical Cord Is Not Covered By A Single Layer But A Distinctive Multilayered Epithelium .. 60

The Effect Of Total Progressive Sperm Density On Pregnancy Prediction In Couples Undergoing Iui For Male Infertility 62

Enhanced Efficacy Of Doxorubicin By Electroporation: Effects On Lung Cancer Cell Viability And Morphology..... 64

The Effect Of Activated Platelet Rich Plasma On In Vitro Spermatogenesıs In Testis Organoids..... 65

Comparative Analysis Of Ethanol Extracts From Rheum Ribes L. On The Viability Of Tm3 Leydig Cells Under Normoxic And Hypoxic Conditions 66

Immunohistochemical Localization Of Tgf-A And Tgf-B1 In The Goose (Anser Anser) Eye..... 67

Role Of $Cd4^{+}Cxcr5^{+}$ T Follicular Helper Cells In Autoimmune Hepatitis: Increased Cell Population With Downregulated Il-21 Expression..... 68

The Histone Lysine Methyltransferases And Their Target Methylation Marks Exhibit Dynamic Expression During Ovarian Aging 69

Combining Leflunomide And Sorafenib: A Promising Strategy Against Colorectal Cancer..... 71

Preclinical Findings Highlight Brcc3 As A Potential Target For Parkinson's Disease: Evidence From Rotenone-Induced Experimental Rat Model..... 72

Nicotinamide Mononucleotide Alleviates Sepsis-Induced Liver Injury In A Rat Model Of Cecal Ligation And Puncture..... 74

Vitex Agnus-Castus L. Oil Modulates Tlr Expression In Sk-Ut-1 Cell Line: A Promising Therapeutic Avenue For Uterine Leiomyosarcoma 75

Aldehyde Dehydrogenase Inhibitor 673a Induces Er Stress-Mediated Apoptosis In Ovarian Cancer Stem Cells..... 76

Buparlisib Enhances The Anticancer Activity Of Radiotherapy In Metastatic Castration Resistant Prostate Cancer 78

Intrahippocampal And Intranasal Application Of Human Umbilical Cord Mesenchymal Stem Cell Derived Exosomes In The Experimental Rat Alzheimer Model 79

Investigation Of The Effect Of Electromagnetic Field Exposure On Catsper Gene Expression Levels 80

Investigation Of The Role Of P97/Vcp In Autophagic Degradation Of Androgen-Binding Protein In Sertoli Cells 81

Indoximod And Melatonin Regressed Tumor Progression And Metastasis Synergistically Restricting Immunosuppressive Tumor Microenvironment 82

Exploring The Therapeutic Potential Of Matcha Tea In Neuroblastoma: Impact On Gap43 And Map2 Expression 83

Short-Term And Long-Term Therapeutic Effects Of Elabela On Torsion-Induced Testis Damage In Rats Via The Alleviation Of Oxidative Stress 84

Evaluation Of Tap73 Pathway In Temozolomide Resistant Cell Line In View Of Cell Proliferation And Apoptotic Pathways 85

Evaluation Of The Effect Of Donafenib And Radiotherapy For The Survival Potential Of Temozolomide-Sensitive And Resistant Gbm Cells 86

Investigation Of The Effect Of Hypoxia On Vegf And Kisspeptin Protein Levels In Invasive Bladder Cancer Cells 87

Expression Of Aquaporin 8 And 5 Molecules In Chondrocytes Of Articular Cartilage In Rats With Type-2 Diabetes Mellitus 89

The Role Of Hippo Signaling Pathway And Cell Polarity In Varicocele-Induced Apoptosis 90

Anti-Psoriatic Effects Of Bergenin And Stem Cell Administration In An Imiquimod-Induced Psoriasis-Like Mouse Model: Targeting Nlrp3 Inflammasome Complex And Nrf2/Keap1/Sirt1 Pathways 91

Investigation Of The Impact Of Systemic Ursodeoxycolic Acid Application On Periodontal Tissues In Rats With Experimental Periodontitis 93

The Effects Of Xenin-25 On Indomethacin-Induced Gastric Ulcers In Rats 94

Determination Of Curcumin Protective Effect On Neurotoxicity Induced By Glioblastoma-Derived Exosomes 95

Advancing Cancer Research: Evaluating Immunotherapy Efficacy Using Patient-Derived Organoids 96

Effect Of Lipopolysaccharide-Induced Acute Systemic Inflammation On Depression-Like Behavior In Rats And Epha4 Expression In Histological Layers Of The Hippocampus 97

Allocation And Ultrastructural Characteristics Of Macrophages Within Lung Tissue 98

Identification Of The Phoenixin Receptor Gpr-173 In Rat Lacrimal Gland 99

$P2y_2$ Receptor Expression In Nucb2/Nesfatin-1 Oxytocin And Vasopressin Neurons In Supraoptic And Paraventricular Nuclei Of The Rat Hypothalamus 100

Effect Of Naringin And Prednisolone Treatment On Blood-Testis Barrier In Experimental Rheumatoid Arthritis Model 102

The Effect Of Prepubertal Di-2-Ethylhexyl Phthalate Exposure On Hippocampus In Rats 103

Synergistic Inhibition Of Hct-116 Colorectal Cancer Cell Viability By Targeting Glut1 And Solifenacin: A Novel Therapeutic Strategy 104

Capsaicin Augments Cisplatin Efficacy In Nsclc: 106

Investigation Of The Protective Effects Of Vitamin A And Omega-3 Fatty Acids In The Hippocampal Formation By Epha4 And Ephb2 Expression In An Experimental Neuroinflammation Model In Rats 108

The Effect Of Nutrition Rich In Vitamin A And Fish Oil On Ovarian Tissue In A Model Of Systemic Inflammation In Rats 109

Beneficial Effects Of Adipose Tissue-Derived Stromal Vascular Fraction On Busulfan-Induced Testicular Damage 110

Histological, Biochemical, And Genetic Investigation Of Liver Aging In Rat 111

Investigation Of The Effect Of Curcumin On The Ovary In An Experimental Sepsis Model In Rats 112

Antioxidant Capacity Of Thymoquinone And Carvacrol Against The Molecular And Immunohistochemical Studies Of Cadmium Toxicity İn The Liver Tissue Of Rat 113

Histological Investigation Of The Effect Of Quercetin On Testicular Damage Caused By Methotrexate 115

Investigation Of The Effects Of Fisetin And Pirfenidone On Cardiac Tissue In Bleomycin-Induced Idiopathic Pulmonary Fibrosis Model In Rats 116

Protective Effects Of Carvacrol In Mimic In Vitro Endothelial Inflammation Model 118

The Histologic Effects Of Early Administration Of Equine Hyperimmune Serum On The Trachea Of K18-Hace2 Mice Exposed To Sars-Cov-2 120

In Vitro Investigation Of The Effects Of Hypothalamic Neuropeptide Spexin On Human Glioblastoma Cells. 121

Confocal Analysis Reveals Lack Of Glur2 Or Glur7 Expression In Mch And Gababr Neurons Within The Lateral Hypothalamic Area 122

Effects Of Prophylactic Vitamin D Application On Neuronal Activation And Behavioral Hyperactivity In Mice Exposed To Sevoflurane On Postnatal Day 10 123

Investigation Of The Aqp5 Molecule Expression In The Lenses Of Diabetic Rats 124

Moringa Oleifera Ameliorates Valproate Induced Pancreas Damage By Inhibiting The Interaction Via Histochemical And Biochemical Alterations 125

Evaluation Of The Relationship Of Blood Lipid Profile With Semen Quality And Icsi Parameters In Idiopathic Male Infertility: A Retrospective Study 126

Investigation Of The Effect Of Nesfatin-1 Peptide On Cellular And Molecular Mechanisms Disrupted In Neonatal Hyperoxic Brain Injury 128

Antiproliferative And Ros-Inducing Effects Of Thymus Thracicus Velen. Extracts' Solvents On Various Cell Lines 129

Circadian Rhythm Gene Dysregulation In Nafld To Nash Progression: A Patient-Based Study 130

Neuropeptide W Ameliorates Brain Damage Induced By Chronic Unpredictable Stress In Rats 131

Evaluation Of Potential Protective Effects Of Neuropeptide W On Testicular Damage Induced By Chronic Psychological Stress In Rats 133

The Impact Of Dysregulated Circadian Rhythm Gene Expression On Recurrence And Prognosis In Hbv-Mediated Hepatocellular Carcinoma Following Liver Transplantation 135

Differential Expression Of Beclin1 And Enos In The Cardiac Tissue Of Anatolian Ground Squirrels During Pre-Hibernation And Hibernation Periods 136

Expression Of Bcl2 And Bax Proteins In Anatolian Ground Squirrel Hearts: A Comparative Analysis Between Pre-Hibernation And Hibernation Periods 138

Fabrication And Characterization Of Msc-Loaded Alginate/Spirulina Microsponge As A Topical Drug Delivery System For Skin Rejuvenation 140

The Effects Of Pioglitazone On Metabolic Syndrome In Kidney Tissue 142

Curcumin-Activated Apoptosis İn Endoplasmic Reticulum Stress-İnduced Brain Tumour 143

Investigation Of The Apoptotic Effect Of The Commercial Eldermafill Exo Kit On Mda-Mb-231 Cells 144

Evaluation Of Regulatory T Cells And Exosomes In The Placental Tissue Of Patients With Maternal Hypothyroidism 145

Immunohistochemical Demonstration Of Glutamate And Gaba Receptors In Orexin-A Neurons 147

Elabela Ameliorates Ischemia/Reperfusion- Induced Hepatic Damage 148

Myrtus Communis Lessens Ionizing Radiation-Induced Ileum, Colon, Liver And Pancreatic Damage In Rats 150

Immunohistochemical Assessment Of The Distribution And Quantification Of Immunocompetent Cells In The Rats' Lungs 151

Rottlerin Application Slowed The Migration Of Glioblastoma Cells 153

Effect Of Normobaric Intermittent Hypoxia On Bone Tendon Junction Healing: A Rat Model 154

A New Approach To The Treatment Of Glioma Tumors; Could It Be Indoximod? 155

Mitochondrial And Apoptotic Proteomic Profile Of Mesenchymal Stem Cells In Endometriosis 156

Do Microplastics Effect Tight Junction Proteins At Sertoli Cells? 158

Establishment Of An Imiquimod-Induced Psoriasis-Like In Vitro Model In $CaCl_2$-Differentiated Human Keratinocytes: Morphological, Biochemical, And Molecular Approaches 160

Effects Of Pseudoephedrine On Rat Fetal Bone Development 162

The Effects Of Intermittent Fasting On Urinary System Functions In Genetic Absence Epileptic Rats In Terms Of Gender Differences 163

16. ULUSAL HISTOLOJİ VE EMBRİYOLOJİ KONGRESİ 165

İmplantasyon Şifresinin Çözülmesi: Fare Modellerinden İpuçları 166

Mikro-Tese İle Sperm Elde Edilen Nonobstrüktif Azospermik Erkekler Ve Kriptozoospermik Erkeklerde Icsi Sonuçlarinin Retrospektif Değerlendirilmesi 167

Nar Ve Aronya Ekstrelerinin Sıçanlarda L-Argininle Oluşturulan Pankreas Hasarı Üzerine Tedavi Edici Etkileri 168

Formaldehitin Yol Açtığı Organ Hasarı Üzerine Timokinonun Etkilerinin İncelenmesi 169

Doksorubisin Kaynaklı Kardiyotoksisitede Üzüm (Vitis Vinifera L.) Çekirdeği Ekstraktının Koruyucu Etkisinin Araştırılması....171

Mcf-7 Ve Mda-Mb-231 Meme Kanseri Hücrelerinin Metastatik Karakterine Silymarin'in Etkisinin 2 Boyutlu Ve 3 Boyutlu Kültür Yöntemleriyle Karşılaştırmalı Olarak Değerlendirilmesi 173

Yumurta Tavuklarında Diyet Kalsiyum, Fosfor Ve Mikrobiyal Fitazın Bağırsak Morfolojisi Üzerindeki Etkileri 174

Sıçanlarda Siklofosfamid İle Oluşturulan Deneysel Ovaryum Hasarı Üzerine Gallik Asit'in Etkileri 175

Moringa Oleifera İnsan Glioblastoma Hücre Hatlarındaki Akt-Foxo3a-Bim Yolağına Etki Eder Mi? 177

Streptozotosin Ile Sıçanlarda Oluşturulan T1dm Modelinde Carvacrol'ün Pankreas Hücrelerindeki Pi3k/Akt Yolağı, Glut-2 Ve Insulin Ekspresyon Düzeyine Etkilerinin Araştırılması 178

Erken Ve Geç Başlangıçlı Preeklampsi Vakalarında Tigit, Pvrig, Cd155, Cd112 Ekspresyonlarının Değerlendirilmesi....179

Preeklampsinin Göbek Kordonu Mezenkimal Stroma Hücrelerinin Vegfr-2 İfadesi Üzerine Etkisi....181

İnsan Göbek Kordonu Multipotent Stroma Hücreleri Kaynaklı Ekzozomların İn-Vitro Hipoksik Ve Normoksik Koşullarda Endotel Hücreleri Üzerinde Anjiyogenez Etkinliğinin Sınanması Ve Karşılaştırılması 183

Dehidroepiandrosteron İle İndüklenen Sıçan Polikistik Over Sendromu Modelinde Phoenixin-14 Peptidinin Ovaryum Morfolojisi Üzerine Etkileri 185

Deneysel Epilepsi Modelinde Korteks Ve Hipokampüste Nöroplastin, Traf6, Glua1, Gaba(A/B) Reseptörleri Üzerine Rutinin Etkilerinin Immünohistokimyasal Ve Moleküler Analizi....186

Anoreksijenik Peptit Sentezleyen Nöronlarda Östrojen Reseptör Ekspresyonunun Immünohistokimyasal Olarak Belirlenmesi 188

Bleomisin Ile Indüklenmiş Deneysel Deri Hasar Modelinde Alfa Lipoik Asidin Potansiyel Etkilerinin Değerlendirilmesi....189

Sıçanlarda Metotreksat Ile Oluşturulan Testis Hasarına Karşı Lactobacillus Rhamnosus Gg'nin Olası Koruyucu Etkilerinin Incelenmesi 190

Rspo-1 Nöronlarında Glutamaterjik Sistemin Aktive Edici Etkisi 192

Glioblastoma Hücrelerinde Ilaç Direncinin Aşılması: Cdk4/6 Inhibisyonunun Etkisi 194

Kadmiyum Uyarılı Testis Hasarına Karşı Timokinon'un Koruyucu Etkisi 195

Genetik Absans Epilepsili Sıçanlarda Aralıklı Açlığın Nörogenez Üzerine Etkilerinin Incelenmesi.....197

Deneysel Over Torsiyonu Modelinde Iskemi-Reperfüzyon Hasarına Karşı Mirisetin'in Over Ve Oosit Üzerine Etkileri 199

Streptozotosin Ile Indüklenmiş Diyabetik Rat Modelinde Hidroksitirozolün Pankreas Beta Hücrelerindeki Pi3k/Akt Yolağı, Insülin Ve Glut-2 Ekspresyonu Üzerine Etkileri.....200

7. Gün Blastosist Gelişimi: Risk Faktörlerinin Analizi Ve Geç Gelişimin Predikte Edilmesi 201

İmplantasyon Ve Desidualizasyon Süreçlerinde Kromozomal Yolcu Kompleksinin Yaşlanmaya Bağlı Olası Değişikliklerinin Araştırılması 203

Monosodyum Glutamat İle Oluşturulan Karaciğer Hasarinda Ferulik Asitin İyileştirici Etkisi.....204

Sıçanlarda Siklofosfamid Ile Oluşturulan Böbrek Ve Mesane Hasarına Karşı Klorojenik Asit'in Etkileri* ..205

Postnatal 21 – 49. Günler Arasında Uygulanan 900 Mh Z Elektromanyetik Alanın Farklı Gelişim Dönemlerindeki Erkek Sıçanların Testis Morfolojisine Etkisi 207

Bisfenol-S'nin Siçan Ovaryum Dokusu Üzerindeki Etkilerinin Elektron Mikroskobu Ile Incelenmesi.....209

Abamektin Maruziyetinin Zebra Baliği Ovaryum Dokusu Üzerindeki Histopatolojik Etkisi: Işik Mikroskobi İncelemesi 211

Metconazol'ün Erkek Balb/C Fare Karaciğer Dokusunda Toksikolojik Analizi.....213

Yüksek Yağli Diyet İle Oluşturulmuş Karaciğer Yağlanmasi Modelinde Pyrroloquinoline Quinone Uygulamasinin Histolojik Değerlendirmesi 214

Glioblastoma Tedavisi İçin Nano-Mikro Gözenekli Spirulina Yüklü İlaç Taşiyici Biyomateryalin Geliştirilmesi 216

FULL TEXT BOOK 218

Doksorubisin Kaynaklı Kardiyotoksisitede Üzüm (Vitis Vinifera L.) Çekirdeği Ekstraktının Koruyucu Etkisinin Araştırılması.....219

Evaluation Of Microsatellite Instability (Mlh-1, Pms-2) In Granulosa Cells Of Patients Undergoing In Vitro Fertilization Treatment.....227

Preeklampsinin Göbek Kordonu Mezenkimal Stroma Hücrelerinin Vegfr-2 İfadesi Üzerine Etkisi.....234

İnsan Göbek Kordonu Multipotent Stroma Hücreleri Kaynaklı Ekzozomların İn-Vitro Hipoksik Ve Normoksik Koşullarda Endotel Hücreleri Üzerinde Anjiyogenez Etkinliğinin Sınanması Ve Karşılaştırılması 241

Comparative Analysis Of Ethanol Extracts From Rheum Ribes L. (Işkin) On The Viability Of Tm3 Leydig Cells Under Normoxic And Hypoxic Conditions.....253

Nicotinamide Mononucleotide Alleviates Sepsis-Induced Liver Injury In A Rat Model Of Cecal Ligation And Puncture.....262

Vitex Agnus-Castus L. Oil Modulates Tlr Expression In Sk-Ut-1 Cell Line: A Promising Therapeutic Avenue For Uterine Leiomyosarcoma 268

Investigation Of The Effect Of Electromagnetic Field Exposure On Catsper Gene Expression Levels 278

Exploring The Therapeutic Potential Of Matcha Tea In Neuroblastoma: Impact On Gap43 And Map2 Expression 285

The Role Of Hippo Signaling Pathway And Cell Polarity In Varicocele-Induced Apoptosis 294

2ND INTERNATIONAL CONGRESS OF HISTOLOGY AND EMBRYOLOGY

ABSTRACT BOOK

Invited Speaker

LIVE IMAGING OF HUMAN EMBRYOS: WHAT LIES BELOW THE SURFACE?

DENNY SAKKAS
Boston IVF, IVI Global Research Alliance, Waltham MA, USA
denny.sakkas@yale.edu

Abstract: The need to identify the most viable embryo following in vitro fertilization (IVF) was established early in the history of human IVF. The stalwart of identifying the best embryos has been morphology. Other techniques have however seen wide acceptance, including the use of Preimplantation Genetic Testing, even though concerns exist over the invasive nature of the technique. Non-Invasive assessment has aimed to examine whether morphological determinants exist during the preimplantation stages that relate to an embryo's viability, or whether we can quantitatively measure factors in the media. Live imaging technologies have advanced dramatically in the past decade. Techniques such as Fluorescent Lifetime Imaging Microscopy (FLIM) allow us to non-invasively establish the metabolic blueprint of an embryo. The analysis of metabolic function, through examination of spent medium or through novel microscopies, could provide the basis for selecting the embryo with the highest viability. More recently, the finding that DNA is present in spent media has opened the door for noninvasive chromosomal screening of the embryo. Live imaging using SPY fluorochromes has allowed us to visualize key preimplantation embryo features. We have observed that blastocysts bud nuclear DNA from trophectoderm cells and that this is increased by the biopsy technique. This presentation will examine the current state of research on noninvasive technologies, including noninvasive chromosomal screening and novel optical methods. In conclusion, I will discuss how live imaging techniques have changed our understanding of the complexities of human embryo preimplantation development.

Invited Speaker

EXOSOMES DERIVED FROM HUMAN UMBILICAL CORD MULTIPOTENT STROMAL CELLS ENHANCE ANGIOGENESIS

FERDA TOPAL ÇELİKKAN
Ankara University, Faculty of Medicine, Department of Histology and Embryology
ferdatopal@gmail.com

Abstract: All cells produce small vesicles. Exosomes are cell-derived and nano-size biovesicles released into surrounding extracellular space upon fusion of multivesicular bodies (MVB) and covered by the plasma membrane. These vesicles are shown to carry cargos of proteins which are cell-specific, genetic materials and lipids, and are receive selectively by adjacent or distant cells far from their extricate, reprogram recipient cells onto their bioactive compounds (1).

In exosome research history, in1981, Trams et al. noticed a group of vesicle-like organizations with diameters 30–1000 nm under transmission electron microscopy (2). In 1987, Later, Johnstone et al. classified a vesicle-like structure and isolated from sheep reticulocytes these membrane-covered vesicles by ultracentrifugation at 100,000*g* for 1.5 hour (3). These membrane-bound structure enriched in proteins with various functions, such as tetraspanins (CD9, CD63, CD81) indicated to as the transmembrane 4 superfamily proteins, which take part in cell permeation, attack, and fusion events, heat shock proteins (HSP70, HSP90), as part of syntheses by cells in response to exposure to stressful conditions and involved in antigen binding and presentation, MVB formation proteins that are involved in exosome release (Alix, TSG101) proteins responsible for membrane fusion and transport (annexins and Rab) (1).

EVs are categorized three types based on their mechanism of size and release: exosomes (less than 150 nm in diameter), microvesicles (150-1000 nm) and apoptotic bodies (>1000 nm) (4). The biogenesis of exosomes from the microvesicles existing intracellular compartment and endosomal sorting complex (ESCRT) essential for transport mechanism in the carrying of vesicle cargo to cell membrane (5). Exosomes and microvesicles exhibit distinct characteristics, including differences in their biogenesis and release pathways. However, they also demonstrate substantial overlap in their bio-physicochemical properties, such as size range, density, and the presence of specific surface proteins. (6). These vesicles play a pivotal role in intercellular communication between adjacent and distant cells, both in physiological and pathophysiological processes. Exosomes are developed within multivesicular bodies and are subsequently released by fusion with the cell membrane. Exosomes gain access to cells via three principal pathways: membrane fusion with the target cell, receptor-ligand-mediated internalization, and endocytosis. (7).

Why work with exosomes? There are three things that kind of attracted us to exosome in general. Firstly, being cellular communication. Second, They are staring to become important to disease research including potential for diagnostic and therapeutic. Third, is research has shown as much of the content such as. Traditionally if you want to work with this structure you are looking for rare targets. So the best way to do this is to extract your exosomes, isolate them concentrate them. Exosomes are secreted into the extracellular space. It is essential to ascertain the size distribution and quality of the isolated exosomes. There are many methods available, best suited to their research question and focus more on quantity, rather than specificity, of EVs (8).

The method of isolation employed will determine the yield and relative specificity of the resulting EV preparation. The isolation of exosomes has historically been a laborious and time-consuming process, necessitating numerous centrifugation steps at exceedingly high speeds. Alternative methodologies have been devised that offer a more streamlined workflow and faster turnaround time, albeit with the potential for the isolation of both exosomes and microvesicles. Each technique possesses distinctive advantages and challenges, and it is incumbent upon the researcher to select the most suitable approach based on their specific system and intended outcomes (9). Precipitation is a common methods of exosome isolation. Samples containing EVs are incubated with a buffer that changes their solubility or sedimentation rate. EVs are accumulated at the bottom of the tube. This method is the fastest turn arounds and most straight forward workflows. Polyethylene glycol (PEG), sodium acetate and organic solvents were used. Precipitation results in a large volume of isolated EVs with no specificity for EV subtype or specific proteins (10). Ultrafiltration is the process the fluid passing over a semi-permeable membrane, allowing some substances to pass through while others are retained (11). Size-exclusion chromatography (SEC) separates macromolecules based on their size. To accomplish this, the sample is passed through a porous column and molecules are isolated in fractions (12). Considered the gold standard for EV isolation, ultracentrifugation on relies on vesicle size and density (13). To further improve upon the specificity of EV isolation, many researchers use density gradient centrifugation. There are two general types of density gradient centrifugation for EV isolation: continuous and stepwise gradients. The continuous density gradient centrifugation involves underlaying a sucrose gradient of a singular density to the sample prior to ultracentrifugation. For stepwise density gradient centrifugation, sample is overlayed on layers of iodixanol with different densities (14). Immunoaffinity capture technique relies on the antigen-antibody interaction. Antibodies directed at target of interest (eg CD9, CD63) are coated either in a 96-well plate or conjugated to a bead. Sample is applied directly into coated well, or into sample with coated beads, and EVs are allowed to bind. In a final step, EVs can be eluted from the antibody and used in downstream functional and phenotypic analysis (15). Many methods available to confirm the presence of EVs after isolation. No matter the chosen method of detection, it is important to compare the isolated EV preparation to a known sample containing EVs of interest. Exosomes trigger functional changes in the recipient cells such as suppressing the inflammatory response, promoting vascular regeneration, regulating cell proliferation and migration, accelerating epithelial regeneration, inhibiting oxidative stress damage and facilitating collagen remodeling (16). The study of this process in vitro or in vivo may be conducted using a variety of animal-free angiogenesis assays and models, which focus on different stages of blood vessel formation. (17). The content and effects of exosomes are subject to variations according to environmental factors, the type of cells released and their metabolic status. Bioactivity and protein content of exosomes is altered by oxygen tension (18).

Our lab team have been researched that exosomes derived from human umbilical cord multipotent stromal cells (hUC-MSC) enhance angiogenesis. Study examination procedures are; (1) hUC-MSC expansion, (2) exosome isolation from hUC-MSC and exosome characterization, (3) exosome derived from hypoxic and normoxic conditioned hUC-MSC and (4) angiogenesis experiment on HUVEC; tube formation assay. First procedure was P_0 and P_1 hUC-MSCs propagation using human umbilical cord explant cultures. hUC-MSCs at P_3 highly (>95%) expressed the MSC surface markers CD73, CD90, CD105 and negatively (<1%) expressed CD34, CD45 shown in flow cytograms. If I might suggest, the process of differential centrifugation comprises a series of centrifugation steps, each involving an increase in both centrifugal force and duration. This approach may be helpful in facilitating the separation of vesicles and cells. In the initial centrifugation steps, it is observed that cells

and larger vesicles settle out at a faster rate, while the majority of smaller vesicles remain in the supernatant and settle out in the subsequent, faster rotation steps. Following the encouraging proliferation of hUC-MSC in P_3 by 70-80%, the culture was continued for 48 hours in culture medium with exo-free FBS. The culture medium was carefully collected and transferred to ultracentrifuge tubes, and the necessary steps were performed in the appropriate rotor of the ultracentrifuge device. These included 2,000*g* for 30 minutes and 10,000*g* at +4°C for 30 minutes, after which the supernatants were collected. These steps facilitate the removal of cell residues, apoptotic bodies and microvesicles, which may be beneficial for the process. A further 1.5 hour was allowed for the pellet to settle at +4°C before the supernatant was discarded and the pellet was resuspended in PBS. A final 90 minutes was allowed for the pellet to settle at +4°C before the identification and quantification experiments were initiated on the pellet in the tubes containing exosomes.
In order to demonstrate the shape, diameter and surface properties of the exosomes, we obtained scanning electron microscopy (SEM) images by fixing the samples with glutaraldehyde (GA), spreading them on a coverslip and coating them with 6-7 nm thick gold-palladium. We hope that this method provides a suitable demonstration of the exosomes' shape, diameter and surface properties. In order to measure the size and number, we employed the Tunable Resistive Pulse Sensing (TRPS) method, as outlined in the general information. In order to ascertain the quantity of protein within the exosome content, we decided to employ the MicroBCA (bicinchoninic acid assay). This is a colorimetric assay that has the potential to quantify the total protein concentration of dilute protein solutions in the range of 0.5 to 20 µg/mL, operating on the principle of copper reduction. The absorbance at 562 nm is measured and the amount of protein is determined in accordance with the standards, if that is acceptable. Western blot analysis was used to demonstrate the presence of CD9 and CD63, which are known to be highly expressed on the exosome membrane. Hypoxic condition was confirmed by HIF1α labelling in nucleus of hUC-MSC and VEGFR-2 expression of hUC-MSC was observed as the capacity of angiogenic promoting. Exosome protein content was higher in normoxia than in hypoxia (≅two fold). Six angiogenesis experimental groups were set up as Control (negative) Endothelial Basal Medium (EBM) group, Control (positive) Endothelial Growth Medium (EGM) group, 50-Exo_{21} (with 50 µg/mL exosome under normoxic condition), 200-Exo_{21} (with 200 µg/mL exosome obtained under normoxic condition), 50-Exo_1 (with 50 µg/mL exosome obtained under hypoxic condition) and 200-Exo_1 (with 200 µg/mL exosome obtained under hypoxic condition). The frozen HUVEC were thawed at 37°C and subsequently plated in DMEM/Ham's F-12 culture medium. Once the cells had reached 60-70% confluency, the culture medium was changed with D-PBS and replaced with FBS-free DMEM Ham's F12 for 24-36 hours before angiogenesis experiments. Twenty-four-well plates were coated for every group with Matrigel® (3 mg/mL) and HUVECs were seeded as 20,000 cells/cm2 for a period of 18 hours under normoxic condition for tube formation assay on this plates. Tube formation was observed using the Hoffman modulation contrast technique at 18. hour and captured. Analyzation processes were executed using Image J Angiogenesis Analyzer software. In vitro angiogenic parameters were HUVEC cytoplasmic extensions-total length, cytoplasmic branches-number of branches, cell to cell interactions-number of nodes, mesh area-number of nodes. F-actin and VEGFR-2 expressions in angiogenically differentiating cells on 4-well culture plates. On the statistically evaluation of the angiogenic parameters, the Exo_{21} groups were greater than that of the Exo_1 groups.

Conclusive Remarks; The hUC-MSC-derived exosomes protein content obtained under hypoxic preconditioning was to be lower than that of exosomes obtained under normoxic preconditioning. The two protein concentrations were selected according to use in existing literature. No notable difference was found between the two exosome concentrations observed

within two oxygen groups. The hypoxia groups was found to be inferior to normoxia groups. It was observed that VEGFR-2 expression, which plays a role in the initiation of tube formation, was increased in the normoxia groups and was decreased in the hypoxia group.

In Summary; Hypoxia-preconditioned exosomes did not demonstrate differential effects at varying concentrations, notable differences emerged at different oxygen concentrations. The expression of VEGFR-2 level per cell was found to be significantly higher in the normoxia group. It is hypothesized that one of the mechanisms of action is through the VEGFR-2 molecule carried via exosomes. A more targeted exosome isolation approach is required.
Our research was supported by Ankara University, Scientific Research Projects Coordination Office, TTU-2022-2303, TSG-2022-2545 and Turkey Science and Technology Projects, 121S821.

References

1. Zhang Y, Liu Y, Liu H, Tang WH. Exosomes: biogenesis, biologic function and clinical potential. Cell Biosci. 2019;9:19.
2. Trams EG, Lauter CJ, Salem N, Jr., Heine U. Exfoliation of membrane ecto-enzymes in the form of micro-vesicles. Biochim Biophys Acta. 1981;645(1):63-70.
3. Johnstone RM, Adam M, Hammond JR, Orr L, Turbide C. Vesicle formation during reticulocyte maturation. Association of plasma membrane activities with released vesicles (exosomes). J Biol Chem. 1987;262(19):9412-20.
4. Gurung S, Perocheau D, Touramanidou L, Baruteau J. The exosome journey: from biogenesis to uptake and intracellular signalling. Cell Commun Signal. 2021;19(1):47.
5. Agarwal S, Agarwal V, Agarwal M, Singh M. Exosomes: Structure, Biogenesis, Types and Application in Diagnosis and Gene and Drug Delivery. Curr Gene Ther. 2020;20(3):195-206.
6. Alashkar Alhamwe B, Potaczek DP, Miethe S, Alhamdan F, Hintz L, Magomedov A, et al. Extracellular Vesicles and Asthma-More Than Just a Co-Existence. Int J Mol Sci. 2021;22(9).
7. Liang Y, Duan L, Lu J, Xia J. Engineering exosomes for targeted drug delivery. Theranostics. 2021;11(7):3183-95.
8. Zhang Y, Bi J, Huang J, Tang Y, Du S, Li P. Exosome: A Review of Its Classification, Isolation Techniques, Storage, Diagnostic and Targeted Therapy Applications. Int J Nanomedicine. 2020;15:6917-34.
9. Chen J, Li P, Zhang T, Xu Z, Huang X, Wang R, et al. Review on Strategies and Technologies for Exosome Isolation and Purification. Front Bioeng Biotechnol. 2021;9:811971.
10. Ansari FJ, Tafti HA, Amanzadeh A, Rabbani S, Shokrgozar MA, Heidari R, et al. Comparison of the efficiency of ultrafiltration, precipitation, and ultracentrifugation methods for exosome isolation. Biochem Biophys Rep. 2024;38:101668.
11. Shu S, Allen CL, Benjamin-Davalos S, Koroleva M, MacFarland D, Minderman H, et al. A Rapid Exosome Isolation Using Ultrafiltration and Size Exclusion Chromatography (REIUS) Method for Exosome Isolation from Melanoma Cell Lines. Methods Mol Biol. 2021;2265:289-304.
12. Sidhom K, Obi PO, Saleem A. A Review of Exosomal Isolation Methods: Is Size Exclusion Chromatography the Best Option? Int J Mol Sci. 2020;21(18).
13. Akbar A, Malekian F, Baghban N, Kodam SP, Ullah M. Methodologies to Isolate and Purify Clinical Grade Extracellular Vesicles for Medical Applications. Cells. 2022;11(2).

14. Lobb RJ, Becker M, Wen SW, Wong CS, Wiegmans AP, Leimgruber A, et al. Optimized exosome isolation protocol for cell culture supernatant and human plasma. J Extracell Vesicles. 2015;4:27031.
15. Greening DW, Xu R, Ji H, Tauro BJ, Simpson RJ. A protocol for exosome isolation and characterization: evaluation of ultracentrifugation, density-gradient separation, and immunoaffinity capture methods. Methods Mol Biol. 2015;1295:179-209.
16. Li Y, Zhu Z, Li S, Xie X, Qin L, Zhang Q, et al. Exosomes: compositions, biogenesis, and mechanisms in diabetic wound healing. J Nanobiotechnology. 2024;22(1):398.
17. Laschke MW, Gu Y, Menger MD. Replacement in angiogenesis research: Studying mechanisms of blood vessel development by animal-free in vitro, in vivo and in silico approaches. Front Physiol. 2022;13:981161.
18. Jiang H, Zhao H, Zhang M, He Y, Li X, Xu Y, et al. Hypoxia Induced Changes of Exosome Cargo and Subsequent Biological Effects. Front Immunol. 2022;13:824188.

Invited Speaker

MINIMALLY INVASIVE DRUG DELIVERY SYSTEMS AND ELECTRICAL STIMULATION FOR NEUROLOGICAL APPLICATIONS

İSMAİL EŞ

Institute of Biomedical Engineering, Old Road Campus Research Building, University of Oxford, Oxford, United Kingdom
ismail.es@eng.ox.ac.uk

Abstract: Modern healthcare often requires patients to undergo multiple hospital visits and procedures, which makes treatment and monitoring time-consuming and inefficient. An innovative approach involves integrating bioelectronics into healthcare systems, that allows diagnostic tests and therapeutic interventions to be performed in a single device, directly on the patient. Bioelectronic devices, ranging from deep brain stimulators to cardiac monitors, offer electronic control over drug delivery. This precision improves patient outcomes by controlling when, where, and how much drug is administered, ultimately minimizing side effects and maximizing therapeutic benefits. As Oxford University Bioelectronics Group, our research focuses on the development of minimally invasive biomedical tools, including a microfluidic ion pump for seizure control in rodents. This device, shaped like a tiny needle, releases ions such as GABA with a pumping efficiency of 90%, significantly decreasing the intensity of seizures in animal models. We currently employ advanced techniques such as femtosecond laser to further decrease the footprint of the device to make it even less invasive. In addition, we have designed electrocorticography (ECoG) and spinal cord stimulators (SCS), which employ pneumatically actuated soft robotics. These devices expand through microfluidic channels after insertion. The SCS prototype, initially 1.5 mm in diameter, expands to 10 mm when air is introduced, then allowed it to fit precisely into spinal cord structures. In human cadaver trials, the insertion of the SCS showed successful deployment and expansion, with minimal tissue damage. Methodologically, the ion pump was optimized for high ion transport efficiency, and the soft robotics used in the SCS were designed to ensure safe expansion within delicate tissues.

Invited Speaker

RELATIONSHIP OF EXOSOME WHICH IS THE RISING STAR MEDICINE WITH CELL DEATH

HAFİZE SEDA VATANSEVER[1,2]

[1]Manisa Celal Bayar University, Faculty of Medicine, Department of Histology and Embryology, Manisa, Türkiye.
[2] Near East University, DESAM Research Institute, Nicosia, Cyprus.
sedavatansever@yahoo.com

Abstract: Exosomes are a population of ekstrasellular vesicules (EVs) secreted by most cell types through the endocytic pathway. They are produced in the endosomal compartment of most eukaryotic cells, including dendritic cells, macrophages, various kinds of stem cells, and even cancer cells. Their specific composition and functional effects are modulated by the activation state of parent cells and microenvironmental stimuli.
Once produced, exosomes are subsequently released into the extracellular space by fusion with the plasma membrane. When cells undergo programmed cell death, key regulatory proteins also control exosome generation and release, which encapsulate cell death signals within exosomes for intercellular communication. Exosomes originating from distinct programmed cell death pathways exhibit marked heterogeneity and can dynamically regulate physiological and pathological processes. Apoptotic cells release exosomes that convey proapoptotic signals to adjacent cells or that carry anti-inflammatory molecules such as IL-10 and TGF-β, in addition to immunosuppressive proteins. Additionally, these exosomes may contain molecules that negatively regulate inflammatory signaling, contributing to immune homeostasis. Conversely, exosomes from cells undergoing pyroptosis or necroptosis typically enhance inflammatory signaling, potentially leading to a cytokine storm and exacerbating inflammation. Understanding the differential composition and release mechanisms of exosomes in various programmed cell death pathways is crucial for advancing our knowledge of cell death processes and identifying new therapeutic avenues for controlling it. In addition to their role in cell death, exosomes from cells undergoing different programmed death modes also influence the tumor microenvironment. Exosome-based cancer immunotherapeutic strategies involve blocking exosome generation from tumor cells, leveraging native exosomes, and engineering exosomes for intervention. However, the better understand the heterogeneity and various physicochemical properties of exosomes, the more their potential for diagnostic and therapeutic use can be addressed.

Keywords: Exosome, cell death, signaling pathway

Invited Speaker

THE RELATIONSHIP BETWEEN FEMALE FERTILITY LOSS DURING OVARIAN AGING AND DNA/HISTONE METHYLATION CHANGES

SAFFET ÖZTÜRK

Department of Histology and Embryology, Akdeniz University School of Medicine, Antalya, Türkiye.
sozturk@akdeniz.edu.tr

Abstract: Recent data indicate a gradual fertility decline in worldwide, developed country, and our country. This phenomenon is presumed to be attributable to socioeconomic factors and the career planning of couples. Ovarian aging process, which encompasses structural and physiological changes, plays a vital role on this decline. Additionally, the number of primordial and other follicle types decrease in proportion to ovarian aging. The primary factors contributing to ovarian aging are genomic instability, telomere shortening, and epigenetic alterations. Epigenetic alterations include DNA methylation and histone modifications. The process of DNA methylation involves the addition of a methyl group to the fifth carbon atom of cytosine nucleotides within CpG islands, which is carried out by DNA methyltransferases.

It was reported that global DNA methylation levels in CpG islands decreased in germinal vesicle (GV) oocytes due to ovarian aging in comparison to the young group. However, global DNA methylation in non-CpG islands increased in GV oocytes derived from aged mice when compared to young counterparts. Meanwhile, transcriptome levels of aging GV oocytes decreased despite of reducing DNA methylation levels. A parallel investigation on human oocytes revealed a decrease in the transcription levels of the genes having roles in translational control and meiosis. These alterations in DNA methylation dynamics may disrupt the transcriptional regulation in the genes as well as in repetitive DNA regions, thereby contributing to age-related fertility loss.

Another fundamental epigenetic mechanism is histone methylation, which is formed by histone methyltransferases in histones H3 and H4. It can be seen in lysine and arginine amino acids, and it occurs single, double, or triple methylation in lysine amino acids. Histone methylation can be observed in different locations at varying methylation levels in active and repressed genes. Histone methylation marks are known to be associated with a number of processes, including transcriptional regulation, RNA processing, gene suppression, DNA repair and genome stability, DNA replication, and DNA recombination.

Many studies revealed a decline in methylation marks, including transcription-related H3K4me2, H3K36me3, H3K79me2, and transcription repression-related H3K9me2, H3K9me3, and H4K20me3, in both GV and metaphase II (MII) oocytes with advancing maternal age. The results demonstrated a reduction in the density of H3K4me2 in aging human and mouse GV oocytes relative to their younger counterparts. Moreover, the level of CXXC1 protein, which plays a role in establishing this methylation mark, was also decreased. In our studies, we found that expression of SETD1B, SETDB1, SETD2, and CFP1 proteins, which are effective in establishing these methylations, as well as H3K9me2 and H3K36me3 methylation mark levels in the primary, secondary, or primordial follicles of aged group.

In conclusion, there is evidence that DNA and histone methylation show age-related changes. These changes are associated with the decline in fertility that occurs with age. In the light of the interactions between these two methylation mechanisms, it is evident that further research is required to elucidate the underlying molecular mechanisms of ovarian aging in the aspect of GV and MII oocytes.

Invited Speaker

CURRENT PERSPECTIVE ON DOCTORAL EDUCATION IN HEALTH SCIENCES IN TÜRKIYE

SAİT POLAT

Çukurova University Faculty of Medicine Histology and Embryology Department
spolat72@gmail.com

Abstract: Today, information technology derives its power from people who are equipped with modern knowledge, can think freely, and have superior brain qualities. The prerequisite for being a country that produces science and technology is to turn scientific thought into a philosophy of life. Therefore, valuing science and scientists is a long process that develops together with the education and culture of societies. It is noteworthy that in recent years, there have been systematic new approaches to doctoral education all over the world and in our country. Doctoral education aims to provide doctoral programs that are more research-oriented, based on collaboration with multidisciplines and sectors, and developed in terms of quality and quantity, and are quite comprehensive. The USA has the highest number of PhD graduates in the world with 71,000 graduates, followed by Germany and the United Kingdom with 28,000 graduates. There is a total increase of 8% in doctoral graduates in OECD countries. The number of doctoral graduates in Türkiye is quite low considering the number of institutions, their diversity and the country's population. The annual number of doctoral graduates in our country is approximately 8,000. In addition to the efforts to increase the number of doctoral graduates, there are significant problems in job placement of graduates in our country, as in other countries. Generally, 80% of doctoral graduates want to stay in academia, so it becomes important to redefine new doctoral fields thematically in a way that will add value to the socioeconomic development of countries. The first doctorate degree in the world was given in Paris in 1150, and Erhard Weigel was recorded as the first doctorate in Leipzig, Germany, in 1652. In 1800, the title of Dr. Phil was given at Humboldt University in Germany, in 1861 the doctorate degree was developed at Oxford University in England, and since 1947 it has spread all over the world. In the Republic of Türkiye, Darülfünun was closed in 1933 and Istanbul University was established in its place. In 1944, the Graduate School of Engineering was organized as ITU. In 1946, Ankara University was founded, and other universities began to be established after 1950. The first doctorate in our country was done at Ankara Agricultural Institute in 1937. The Institute of Agriculture later became Ankara University. The first doctorate was done at Istanbul University in 1939, and at ITU in 1952. Doctoral education was initially carried out according to the German tradition (European classical), but in 1981, the American system was switched to the Higher Education Law No. 2547. Doctor of Philosophy, PhD, Ph.D., or Dphil title; It is defined as the highest academic title where original and independent research results are defended and earned verbally and in writing. The doctoral program provides the student with the necessary skills to conduct independent research, to interpret scientific problems and data by examining them from a broad and deep perspective, to analyze them and to reach new syntheses. In modern terms, a doctorate is defined as an education consisting of research training that takes place through supervised research. Therefore, doctoral education; It has the functions of producing and disseminating information, training scientists and academics who will educate future generations through research and innovation studies, and creating qualified manpower for the sectors. According to the data of the Council of Higher Education (YÖK), there are 129 State and 75 Foundation Universities in our country as of the 2023-2024 academic year. A total of 108933 PhD students are studying in our universities, and 15456 of these students are

studying in the field of Health sciences. On December 13, 2021, YÖK, within the scope of the Research-Focused Mission Differentiation Program; Our universities were evaluated in 32 indicators related to the fields of Research Capacity, Research Quality, Interaction and Cooperation, and 20 state and 3 foundation universities were designated as "Research Universities". 40% of the total doctoral students in our country and 55% of the doctoral students in the field of Health Sciences study at Research Universities. It has been determined that there is a positive correlation between the number and qualifications of PhD students, the number of research studies of universities and the production of knowledge and technology. Education reform was initiated in Europe with the Bologna declaration in 1999, and this process was expanded to include postgraduate education in Berlin in 2003. As a result of the European University Association (EUA) doctoral programs project in 2006, the establishment of the European University Association Doctoral Council (EUA-CDE) in 2008 and the annual meetings, important studies on education have been carried out and doctoral education is the main priority of the European University Association. It was accepted that education would be the basis of a Europe equipped with knowledge. Organization for Doctoral Education in Biomedicine and Health Sciences in the European System - ORPHEUS was established in Zagreb in 2004, and as a result of the meetings held in the following years, a joint book was published in 2012 and doctoral education standards were determined as a) Basic standards, b) Quality development standards. In the light of the information obtained from more than 20 workshops and meetings held with ORPHEUS members at universities and related organizations in the following years, the updated version regarding doctoral education was published in 2020. Standards regarding doctoral education: 1-Research environment, 2-Program outcomes, 3-PhD admission conditions, 4-PhD training program, 5-Consultancy criteria, 6-PhD thesis, 7-Evaluation and 8- Institutional structure. It was found appropriate to use the term recommendations instead of standards. YÖK organized the "Workshop on the Improvement of Doctoral Education" at Hacettepe University in 2022, and more than 250 Rectors, Institute Directors and administrators from all the Universities of our country, as well as faculty members on the subject, attended this workshop. The prominent topics of this workshop were grouped under five themes: Program Opening and Student Admission, Teaching Processes, Consultancy, Administrative Processes and Research and Thesis Process. The President of YÖK stated that they attach great importance to doctoral education and that all kinds of support will be provided to ensure improvements in line with this workshop report and the developments will be followed. In addition, YÖK published the regulation of the Medicine-Science Doctorate Integrated Program (MD-PhD) in the official gazette in 2022, opening the way for successful medical students to continue their doctoral education as well as medical education. In our country, within the scope of Health Sciences Institute (SBE), as of the 2023-2024 academic year, there are approximately 360 doctoral students in the field of Histology and Embryology in state medical and veterinary faculties and foundation university medical faculties, and 38% of these students are studying at Research Universities. In 2015, a "Master's and Doctoral Education Workshop" was held at Ankara University Faculty of Medicine, Department of Histology and Embryology, under the coordination of THED Directorate and myself, and as a result, a report was prepared. According to this report, "Master's and Doctoral Education Program and Study Reports" were prepared and sent to all our departments by the Association Presidency. In our country, in the field of Health Sciences; Doctoral education continues in multidisciplinary programs affiliated with the Faculty of Medicine (Basic and Clinical Medical Sciences), Dentistry, Pharmacy, Veterinary and Health Sciences and Health-related Institutes. Where are we in the field of Health Sciences? What changes are there to existing conditions and codes of practice? When we ask questions; It is seen that some progress has been made in the number of publications and publication quality in SCI indexes, increases in TUBITAK and other funds, the quality of research and the

perspectives of society and management staff on doctoral education and the importance of doctoral studies in the development of the country. In addition, it is also accepted as a common opinion in the doctoral education carried out in accordance with the legislation currently on the agenda, improvements and new regulations should be made in terms of application conditions, number and quality of students, doctoral education supports, staff and other employment problems, consultant selection criteria, quality of doctoral courses and thesis topics, and the publication of theses.

Oral Presentation

HISTOLOGICAL EVALUATION OF THE EFFECTS OF INTERMITTENT FASTING ON TESTICULAR DAMAGE IN THE RAT ABSENCE EPILEPSY MODEL

DAMLA KAYALI[1] | EDA NUR ASLAN[2] | FATMA BEYZA AYKURT[2] | AYBÜKE NUR ÇİLİNGİR[3] | AHMET ANIL KESKİN[2] | [2]ÇAĞAN YARDIMCI | [3]ZARİFE NİGAR ÖZDEMİR-KUMRAL | [4]ÖZLEM TUĞÇE ÇİLİNGİR-KAYA

[1]İstanbul Atlas Üniversitesi | [2]Marmara Üniversitesi Tıp Fakültesi | [3]Marmara Üniversitesi Tıp Fakültesi Fizyoloji Anabilim Dalı |[4]Marmara Üniversitesi Tıp Fakültesi Histoloji Ve Embriyoloji Anabilim Dalı

Abstract

Introduction and Objective**:** Literature indicates an association between epilepsy and abnormal semen analyses. Intermittent fasting (IF) is an effective method for reducing the risk and effects of metabolic disorders. Our study aimed to investigate the reparative effects of IF on testicular damage caused by absence epilepsy (AE), from both morphological and physiological perspectives. The data obtained from our pioneering study in this field will significantly contribute to the existing literature gap.

Materials and Methods: Testicular tissues from control, IF, GAERS (AE), and GAERS+IF (n=20) groups were histologically examined. Sections were stained with Hematoxylin-Eosin for general histopathological evaluation and Periodic Acid-Schiff (PAS) for basal membrane integrity. Apoptosis was assessed using caspase-3, and spermatogenic cells were marked with P-element-induced wimpy testis (PIWI) and deleted in azoospermia-like (DAZL) proteins by immunohistochemistry. Johnsen scoring was performed by measuring seminiferous tubule diameter and epithelium thickness. Levels of oxidative stress markers, including catalase (CAT), malondialdehyde (MDA), glutathione (GSH), myeloperoxidase (MPO), and superoxide dismutase (SOD), were determined by ELISA.

Results: The GAERS group showed significantly lower Johnsen scores, tubule diameters, and epithelium thickness compared to controls ($p<0.0001$, $p<0.0001$, $p<0.01$). After IF treatment, Johnsen scores, tubule diameters, and epithelium thickness values improved compared to those in the GAERS group ($p<0.001$, $p<0.05$, and $p<0.0001$, respectively). PAS staining revealed regular basal membranes in seminiferous tubules of control, IF, and GAERS+IF groups. In contrast, the GAERS group exhibited ondulation in basal membrane structures and irregular PAS staining. Caspase-3 immunoreactivity was significantly higher in the GAERS group than in the IF group, with values in the GAERS+IF group approaching control levels ($p<0.01$, $p<0.05$). The immunoreactivity of PIWI and DAZL was significantly reduced in the GAERS group compared to that in the IF group ($p<0.01$, $p<0.05$), while it increased in the GAERS+IF group. Consistent with histological data, oxidative stress markers showed improvement with IF treatment in the GAERS group ($p<0.05$ for MDA, $p<0.05$, $p<0.05$, $p<0.001$).

Conclusion: Our findings suggest that IF has a reparative effect on testicular damage in the absence epilepsy. These results provide a foundation for future studies using this model and indicate that IF could be a potential therapeutic approach for patients with epilepsy.

Key words: Intermittent fasting, absance epilepsy, testis, oxidative stress, apoptosis

Oral Presentation

HISTOPATHOLOGICAL EVALUATION OF ALTERATION ENDOTHELIAL CELLS OF LUNGS VESSELS UNDER INFLUENCING MACROPHAGE MIGRATION INHIBITOR FACTOR (MIF)

ALIYARBAYOVA AYGUN | SADİQOVA GULNARA | HUSEYNOVA SHAHLA | YİLDİRİM LEYLA | QURBANOVA SHAHANA[1]

[1] *Azerbaijan Medical University*
alyarbayova@gmail.com

Abstract

Introduction. Macrophage migration inhibitory factor (MIF) is an old pleiotropic pro-inflammatory cytokine, playing a decisive role in the regulation of immune responses, participating in acute and chronic inflammation.

Objective. The aim of the research was to evaluate changes on endothelial cells of vessels within lungs under effect of administration of MIF.

Material methods. The object of research were lungs purchased from 60 adult male white rats taken from Scientific Research Center of Azerbaijan Medical University. The experimental animals divided into 3 groups: intact (without any intervention),"comparison" (administration of 0.3ml of physiological solution), "basic" (administration of 1.39µg MIF [MIF Rat, ProSpec (Protein-Specialists) CYT-193, Ness-Ziona, Israel] dissolved in physiological solution; total volume was 0.3ml). Rats excluded from the experiment under ketamine anesthesia after administration of MIF and saline solution into the tail vein in 2 hours, 2, 3, 7, 15, 30 days. Histological analyses of lung tissue were performed on formalin fixed, paraffin embedded, 3.0-5.0µm thick serially sectioned, stained with H&E. Electron microscopic investigation were conducted on ultrathin sections obtained from araldite-epon blocks in 50-70 nm thick were first stained with 2.0% uranyl acetate solution and with 0.6% pure lead citrate in 0.1N NaOH, then examined by JEM-1400 electron transmission microscope (Jeol, Japan).

Results. After 2 hours administration of MIF into circulatory system first target structure was vascular endothelial cells, that create tight barrier to fluid, protein passage between interstisial and vascular area, so one reason for conserving dry alveoli. Under effect of MIF this barrier disrupted and increased vascular permeability resulted in plasmorrhagia into interstisial (created pulmonary edema) area and air spaces (flooding of alveoli). Around small and medium sized vessels detected edematous fluid in ringlike shape. These feature visible on histological examination at acute lung inflammation. On ultrastructural levels observed swollen cytoplasm, abundance pinocytotic vesicles and increased nucleus of endothelial cells, on the surface revealed lot of microcytopodia. On 2-3rd day most capillaries still obstructed by plug of erythrocyte. Normalization in the capillary network begins to be fixed only after the 7th day of the experiment; but even on the 15th and 30th day microresidual feature do not dissolve completely.

Conclusion. Summarizing the data on morphological alteration of endothelial cells at acute lung inflammation induced by intravascular administration of MIF should be considered in experimental lung pathomorphology and implemented to open up new treatment opportunities for recovering the integrity of endothelial barriers of lung vessels, especially microvessels.

Oral Presentation

EFFECT OF RUTIN ON CHEMERIN AND ENOS EXPRESSIONS İN AN EXPERIMENTAL HYPERTENSION MODEL İN KIDNEY TISSUES OF RATS

TUBA PARLAK AK[1] | ZAFER TALAYHAN[2]

[1]Munzur University, Faculty Of Health Sciences, Department Of Nutrition And Dietetics, Tunceli, Turkey
tubaparlakak@gmail.com
[2]Munzur University, Graduate Schools And Institutes, Department Of Biotechnology, Tunceli, Turkey

Abstract

Introduction: NG-nitro-L-arginine methyl ester (L-NAME) causes chronic inhibition of nitric oxide synthase (NOS) enzymes, leading to increased arterial blood pressure and development of hypertension. Rutin (3, 3′, 4′, 5, 7-pentahydroxyflavone-3-rhamnoglucoside), also called rutoside, is an important flavonoid glycoside consumed in the daily diet and found in many food items, vegetables and beverages. CMKLR1 (Chemerin chemokine-receptor 1), known as the receptor of chemerin adipokine, is expressed in vascular endothelial cells and its expression level is regulated by various inflammatory cytokines.

Aim: This study aimed to investigate the effect of Rutin on histopathological changes and the expressions of Chemerin and endothelial nitric oxide synthase (eNOS) in kidney tissue in the experimental hypertension model induced by L-NAME.

Material and Method: In the study, 28 adult Spraque-Dawley male rats were selected, 7 in each group, and divided into a total of 4 groups. Control group; 0.5 ml of olive oil was given daily by oral gavage for 21 days. L-NAME group; L-NAME was given by oral gavage together with olive oil at a daily dose of 50 mg/kg/BW for 21 days. L-NAME+Rutin group; L-NAME was given together with olive oil at a daily dose of 50 mg/kg/BW for 21 days, and subsequently Rutin at a dose of 100 mg/kg/BW was suspended in distilled water and given by oral gavage. Rutin group; Rutin at a daily dose of 100 mg/kg/BW was suspended in distilled water and administered by oral gavage for 21 days. The rats were sacrificed under anesthesia then kidney tissues were taken and evaluated for histological and immunohistochemical examinations.

Results: While significant histopathological changes such as glomerular degeneration, tubular vacuolization, intertubular hemorrhage, and inflammatory cell infiltrationwere detected in the kidney tissues of L-NAME group rats compared to the control group, these changes were found to be attenuated in the L-NAME+Rutin group compared to the L-NAME group. While increased CMKLR1 and decreased eNOS immunoreactivities were detected in the kidney tissues of L-NAME group rats compared to the control group ($p<0.05$), decreased CMKLR1 and increased eNOS immunoreactivities were noted in the L-NAME+Rutin group compared to the L-NAME group ($p<0.05$).

Conclusion: It was concluded that Rutin has regulatory effects on Chemerin and eNOS immunoreactivities as well as kidney damage in the experimental hypertension model.
Keywords: Hypertension, Rutin, Chemerin, eNOS, Kidney, Rat.

Oral Presentation

EVALUATION OF MICROSATELLITE INSTABILITY (MLH-1, PMS-2) IN GRANULOSA CELLS OF PATIENTS UNDERGOING IN VITRO FERTILIZATION TREATMENT

FİLİZ YILMAZ

Hitit University, Faculty Of Medicine, Department Of Histology And Embryology, Corum, drfilizyilmaz@gmail.com

Abstract

Introduction: Infertility may result from a variety of factors, including genetic, epigenetic, endocrine, or environmental changes. A number of studies, both in humans and in animal models, have indicated that genes involved in DNA repair mechanisms and epigenetic factors may be associated with infertility.

Objective: The objective of this study was to immunohistochemically evaluate the expression of MLH-1 and PMS-2 in granulosa cells of infertile patients undergoing in vitro fertilization treatment for microsatellite instability indicating DNA repair damage.

Material and Method: This prospective study was conducted using granulosa cell samples obtained from patients undergoing egg retrieval during ICSI/ET cycles at Hitit University IVF Centre. The study population comprised 50 patients with primary or secondary infertility, aged between 22 and 44 years, who underwent ICSI/ET for a range of infertility-related reasons. The patients were divided into five groups according to aetiology: male factor (n = 10), decreased ovarian reserve (n = 10), polycystic ovary syndrome (n = 10), tubal factor (n = 10), and unexplained infertility (n = 10). The clinical and biochemical data pertaining to the patients were duly recorded. The collected granulosa cells were prepared for examination by means of a smear preparation, which was then fixed with formalin. Once the MLH-1 and PMS-2 immunostaining procedures had been completed, the immune scoring was performed. A correlation analysis was conducted to examine the relationship between MLH-1 and PMS-2 expression levels.

Results: The statistical analysis revealed that age, AMH, FSH, antral follicle count (AFC), number of collected oocytes, number of pronuclei, MLH-1, and PMS-2 expression level were statistically significant ($p < 0.05$). The lowest MLH-1 and PMS-2 immune scores were observed in the group with poor ovarian reserve. Pearson correlation analysis demonstrated a positive correlation between MLH-1, PMS-2 levels and AMH, AFC, the number of oocytes collected.

Conclusion: The reduced expression of MLH-1 and PMS-2 observed in the group with diminished ovarian reserve may be attributable to microsatellite instability. Furthermore, a correlation was identified between MLH-1 and PMS-2 levels, and ovarian reserve indicator tests through correlation analysis. In conclusion, our findings indicate that microsatellite instability in granulosa cells may contribute to the development of decreased ovarian reserve. The data obtained thus far suggest that further research into the pathogenesis of infertility may yield new insights and, consequently, new diagnostic or therapeutic methods for molecules associated with microsatellite instability.

Keywords: Granulosa cell; infertility; MLH-1; PMS-2.

Oral Presentation

SYNERGISTIC TARGETING OF KRAS-MUTANT CANCERS THROUGH COMBINED INHIBITION OF LDHA AND FDA-APPROVED ANTICANCER AGENTS

SABİRE GULER[1] | ONUR ONGUNCAN[2] | ABDULLAH YALÇIN[3]

1Bursa Uludag University, Faculty Of Veterinary Medicine, Department Of Histology And Embryology; Bursa Uludag University Faculty Of Medicine Experimental Animal Breeding And Research Unit Cellular And Molecular Targeting Laboratory
2 Bursa Uludag University, Faculty Of Veterinary Medicine, Department Of Histology And Embryology
3Bursa Uludag University, Faculty Of Veterinary Medicine, Department Of Biochemistry
sabirepr@uludag.edu.tr

Abstract

Introduction: The activation of the KRAS oncogene is a critical driver in the development of various malignancies. Recent research has underscored the critical role of KRAS in the metabolic reprogramming of tumor cells. Specifically, the mutagenic activation of KRAS upregulates the expression of lactate dehydrogenase A (LDHA), an enzyme vital for maintaining the glycolytic phenotype associated with KRAS-driven cancers. While targeting LDHA alone has demonstrated antiproliferative and antitumor effects, the inherent metabolic redundancy and plasticity in KRAS-hyperactivated tumors may diminish the efficacy of therapies aimed at a single metabolic pathway.

Aim: To overcome these limitations, we conducted a pharmacological screening of an anticancer drug library to identify potential synergistic agents that enhance the cytotoxic effects of LDHA inhibition in KRAS-mutant tumor cells.

Material-Method: To inhibit LDHA, we utilized FX-11, a potent small-molecule inhibitor. A library consisting of 1143 FDA-approved anticancer drugs was utilized for both single-agent and combinatorial screenings. The screenings were conducted using the HCT116 cell line, which harbors a KRAS mutation and is representative of colon cancer. Cell viability was determined through the Sulforhodamine B (SRB) assay. Promising combinations were confirmed using the CellTiter-Glo assay. To further validate the findings, synergistic drug combinations were tested in PANC-1 and MIA PaCa-2 cell lines, which are KRAS-mutant pancreatic adenocarcinoma models. Synergy was quantified using the SynergyFinder online tool. The antiproliferative effects of single drugs and their combinations were also evaluated in colony formation assays, and apoptosis was assessed using the TUNEL assay.

Results: A total of six drugs demonstrated enhanced antiproliferative effects in HCT116, PANC-1, and MIA PaCa-2 cell lines when combined with FX-11, compared to the effects of each drug alone. Notably, the combination of LDHA inhibition with masitinib (a tyrosine kinase inhibitor), pinaverium bromide (a calcium channel blocker), mifepristone (a progesterone receptor antagonist), posaconazole (an antifungal), sonidegib (a selective Smo antagonist), and benztropine (an acetylcholine competitor), exhibited significant synergistic effects. These combinations induced apoptosis and completely abrogated the colony formation potential of cancer cells, whereas single agents had minimal impact, suggesting a synthetic lethality by simultaneous inhibitions of LDHA and these drugs.

Conclusion: As a result, the combination of FX-11 with certain FDA-approved anticancer drugs exhibited synergistic effects in KRAS-mutant cancer cell lines, indicating a promising therapeutic strategy for targeting metabolic vulnerabilities in these malignancies.

Oral Presentation

THE EFFECT OF THYMOL ON LIVER DAMAGE CAUSED BY SUBCHRONICAL CADMIUM EXPOSURE IN RATS

SEMANUR ISIK, TENZİLE BEYZA DURMUS, ENGİN YENİLMEZ, ALİ KULABER

Karadeniz Technical University, Faculty of Medicine, Department of Histology and Embryology, Trabzon, Turkiye, drsemanurisik@gmail.com

Abstract

Introduction: Heavy metals, including cadmium(Cd), are among the most serious environmental pollutants because they can cause significant oxidative stress(1). Half-life of Cd is 15-30 years and it accumulates in the liver and renal cortex(2). Experimental animal studies showed that subchronical Cd exposure leads to chronic inflammation and apoptosis in the liver(3). Among plant-derived dietary phytochemicals, thymol(THY) has attracted attention due to its favourable physicochemical and pharmacological properties(4). It has antioxidant, antiapoptotic, anti-hepatotoxic, anti-hyperlipidemic, anti-hyperglycaemic activities(5).

Objective: Our study aimed to histologically assess thymol's effects on liver damage from subchronical cadmium exposure.

Material-Method: In the study, 40 male Sprague Dawley rats were divided into 4 groups. Control(n=10): 90 days of drinking water with 0.08% ethanol. Cd(n=10): 90 days of drinking water with 50 mg/L CdCl2. THY(n=10): 90 days of drinking water with 111.1 mg/L thymol (dissolved in ethanol). Cd+THY(n=10): 90 days of drinking water with 50 mg/L CdCl2 and 111.1 mg/L thymol.

Liver sections were stained with Haematoxylin&Eosin, Masson Trichrome, Periodic Acid-Schiff (PAS) stains. FIJI software and semiquantitative scoring system were used for histopathological evaluations (0: no changes, 1: mild changes, 2: moderate changes, 3: severe changes). Data were analyzed with SPSS 23.0. The Mann-Whitney U test assessed non-normally distributed data, while the Kruskal-Wallis test compared groups. Statistical significance was set at $p<0.05$.

Results: A statistically significant increase was observed in the parameters of fatty changes in hepatocytes, hepatic cord irregularity and unclear hepatocyte boundaries in Cd group compared to control and THY groups. A significant improvement was observed in Cd+THY group in terms of unclear hepatocyte boundaries compared to Cd group. The number of hepatocytes containing double nucleus and hypereosinophilic hepatocytes increased significantly in the Cd group compared to the control group. Hepatocyte and central vein diameter decreased significantly in THY group compared to Cd group. There was no statistically significant difference between the groups in the parameters of oedema, inflammatory cell infiltration, sinusoidal dilatation, portal vein diameter and hepatocyte nuclear area. Masson Trichrome staining findings showed a significant increase in the amount of collagen seen around the central vein in the Cd group. In PAS staining findings, a partial decrease in PAS positivity was observed in the Cd group and a significant increase was observed in the THY group compared to the other groups.

Conclusion: It was concluded that THY may be partially effective in preventing Cd-induced liver damage. We recommend further studies at different doses and durations.

Oral Presentation

MODULATORY EFFECTS OF ROSA CANINA SEED OIL ON JUNCTIONAL PROTEIN EXPRESSION IN THE DUODENAL MUCOSA OF EPILEPTIC RATS

NEVRUZ ALIŞ SÖYLEYİCİ | ONUR ONGUNCAN | FÜSUN SONAT | EBRU ÖZYURT | SABİRE GÜLER

Bursa Uludag University Graduate School of Health Sciences Department of Veterinary Histology and Embryology, nwrzalis@gmail.com

Abstract

Introduction: The intestinal barrier plays a critical role in maintaining homeostasis and immune function, with tight junctions (TJs), adherens junctions (AJs), and desmosomes being essential for these processes. Disruption of these junctions, particularly under conditions of oxidative stress, can lead to increased intestinal permeability, commonly referred to as "leaky gut," which is associated with various pathological conditions, including epilepsy. This study explores the impact of epilepsy on intercellular junctions within the duodenal mucosa and evaluates the potential protective effects of Rosa Canina Seed Oil (RSO), known for its antioxidant properties.

Aim: The aim of this study was to investigate the effects of epilepsy on the expression of key intercellular junctional proteins (ZO-1, E-cadherin, and vimentin) in the duodenal mucosa of rat models, and to assess the impact of RSO treatment on these junctions in the context of epilepsy.

Materials and Methods: Eighty male Sprague-Dawley rats were divided into eight groups, including control and epilepsy groups, with or without RSO treatment at varying doses (0.125, 0.25, and 0.5 ml/rat/day). Epilepsy was induced using pilocarpine, and RSO was administered via intragastric gavage for 28 days prior to seizure induction. Immunohistochemistry was employed to assess the expression of ZO-1, E-cadherin, and vimentin in the duodenal mucosa.

Results: Epilepsy significantly downregulated the expression of ZO-1, E-cadherin, and vimentin in the duodenal mucosa, indicating a disruption in both TJs and AJs. RSO treatment demonstrated a dose-dependent modulation of these proteins. Higher doses of RSO partially restored ZO-1 and E-cadherin levels in non-epileptic conditions, though this protective effect was less pronounced in epileptic rats. Vimentin expression was similarly reduced with epilepsy and high-dose RSO treatment, suggesting potential destabilization of mesenchymal structures within the intestinal mucosa.

Conclusion: This study highlights the deleterious effects of epilepsy on the integrity of intercellular junctions in the duodenal mucosa, with significant downregulation of key proteins. Rosa Canina Seed Oil demonstrates promising potential as a therapeutic agent to counteract these effects, showing that its antioxidant properties can effectively support the preservation of intestinal barrier function, even in the challenging context of epilepsy.

Oral Presentation

ASSESSMENT OF THE IMPACT OF AMNIOTIC FLUID (AF) AS A PERFUSION SOLUTION IN PIG LIVERS EXPERIENCING HYPOTHERMIC OXYGENATED MACHINE PERFUSION (HOMP)

SENDEGUL YİLDİRİM[1] | OZGUR DANDİN[2] | DENİZ KARACAYLİ[3] | CAGATAY YİLMAZ[4] | MURAT CANPOLAT[3] | MUTAY AYDİN ASLAN[4] | GAMZE TANRİOVER[5]

[1]Akdeniz University Department Of Histology And Embryology|[2]Akdeniz University Department Of General Surgery |[3]Akdeniz University Department Of Biophysics | [4]Akdeniz University Department Of Biochemistry| [5]Akdeniz University Department Of Histology And Embryology
sendegulyildirim@gmail.com

Abstract

Introduction: Ischemia-reperfusion injury (IRI) is a critical issue in organ transplantation, occurring when blood flow returns to tissues after a period of oxygen deprivation (ischemia). The initial ischemia leads to cellular damage, which is often exacerbated upon reperfusion due to oxidative stress, inflammation, and calcium overload. In transplantation, IRI occurs during organ removal (ischemia phase) and insertion (reperfusion phase). Remission strategies focus on optimizing preservation, cold storage solutions and pharmacological interventions to reduce oxidative stress and inflammation.

Objectives: We investigated the efficacy of amniotic fluid (AF) compared to the standard histidine-tryptophan-ketoglutarate (HTK) solution in hypothermic machine perfusion (HOMP) and ex-vivo normothermic reperfusion of pig liver tissue. The study examined the effects of AF in combination with HOMP, providing a perspective beyond static cold storage (SCS), known for its immune activation and cytoprotective properties.

Materials and Methods: The experimental groups were divided into three groups: Group 1; static cold storage (SCS; n=3), Group 2 received histidine-tryptophan-ketoglutarate perfusion (HTK; n=3) and Group 3 received amniotic fluid perfusion (AF; n=3). Pig livers were excised, subjected to one hour of warm ischemia, and then preserved in either the SCS or HOMP system for 4 h. During perfusion and reperfusion, we monitored bile production, sphingomyelin levels, reactive oxygen and nitrogen species, total antioxidant capacity, protein concentrations, liver tissue oxygen saturation, flow dynamics (portal vein and hepatic artery pressures and resistance), serum biochemical and blood gas levels, and performed histopathological and immunohistochemical analyses (apoptosis, endothelial cell activation, mitotic activity, macrophage accumulation, and bile duct morphology).

Results: Compared to HTK-based methods, AF-HOMP demonstrated more efficient blood flow, lower vascular resistance, and better organ protection during hypothermic perfusion and ex vivo reperfusion. Blood gas measurements confirmed the stability and efficacy of AF-HOMP in maintaining physiological levels post-reperfusion. Additionally, AF-HOMP improved bile synthesis, sphingomyelin levels, and glycogen preservation. Histopathological evaluations revealed that AF-HOMP significantly reduced parenchymal necrosis, hepatocyte vacuolization, and sinusoidal obstruction. Immunohistochemical analysis further highlighted the protective effects of AF on bile duct function, cell proliferation, endothelial cell activation, and apoptosis.

Conclusion: This study demonstrated that AF in a warm ischemia, HOMP, and ex vivo liver reperfusion model outperforms the standard HTK approach. AF-HOMP offers a potentially safer, more affordable, and accessible option for liver preservation, which could expand the donor and enhance liver transplantation outcomes.

Key words: Ischemia-reperfusion injury, HOMP, liver, transplantation, amniotic fluid

Oral Presentation

INVESTIGATION OF HISTOLOGICAL ALTERATION CAUSED BY N-METHYLNITROSOURE-INDUCED BREAST CANCER MODEL ON THE OVARIAN TISSUES

HÜSEYİN AVNİ EROĞLU[1] | BAŞAK YAVUZ[2] | CEMRE AYDEĞER[1] | UFUK DEMİR[1] | MUSTAFA MAKAV[3] | DAMLA AYKORA[4]

[1]Çanakkale Onsekiz Mart University|[2] Izmir Democracy University |[3]Kafkas University|[4]Bitlis Eren University
cemre.ayd@hotmail.com

Abstract

Introduction: N-methyl nitrosourea (NMU; MNU), as a nitroso compound (NOC), is unstable, leading to DNA methylation. This situation changes protein synthesis first, and then mutations occur in the body. Due to these, MNU is used in severe different types of cancer in animal experiments. MNU-induced cancer models could be varied literature, and it is seen that the most used model is breast cancer. Furthermore, it is reported that when breast cancer is induced in the animal, MNU damages the ovarian tissue.

Aim: In consideration of this knowledge, the study is aimed at the alteration of macroscopically and microscopically on breast and ovarian tissue in two different types of MNU-induced breast cancer.

Material-Method: A total of 8 female Wistar albino rats were divided into two groups under the ages. 190–200-gram 2-3-month rats involved in Group 1 were applied 50 mg/kg of MNU intraperitoneally (i.p.) only once. 40-45-gram 21-day-old rats, contained Group 2, were applied 50 mg/kg of MNU i.p. four times. Three weeks after the first inductions, all animals were palpated twice a week aspect of tumour. In 140 days of the study, the animals' tissues were harvested under general anaesthesia. Breast and ovarian tissues were fixed in %10 of formaldehyde at 24 hours. Following fixation, paraffin blocks were prepared using routine tissue processing procedures. Sections of 4 µm thickness were obtained from the blocks using a microtome and stained with Hematoxylin & Eosin (H&E) for microscopic examination.

Results: Interestingly, there was no tumour formation in the mammary region was observed in either group following MNU induction. In addition, microscopic examination of tissue samples from both groups revealed physiological structure in the mammary tissue, and no change was observed. On the other hand, ovarian tissue views were inflammatory and redness macroscopically. Furthermore, shrinkage of follicles, atretic follicles, stromal disintegration, and vacuolisation were observed microscopically in the ovarian tissues.

Conclusion: According to the results, it is exhibited that even if MNU did not cause any changes in mammary tissue in both groups over the 140 days, it induces tumorigenesis in the ovarian tissue macroscopically and microscopically. Therefore, MNU is a potential chemical for ovarian cancer models in rats.
Çanakkale Onsekiz Mart University Scientific Research Projects Coordination Unit supported this study (Project Number: TSA-2021-3473).

Oral Presentation

HYDROXYCHLOROQUINE INDUCES RETICULON 4 EXPRESSION IN PROSTATE CANCER CELLS

TUĞCAN KORAK[1], MERVE GULSEN BAL ALBAYRAK[1], SEVİNC YANAR[2], MURAT KASAP[1]

[1]Kocaeli University, Faculty of Medicine, Department of Medical Biology, Kocaeli, Turkey
[2]Sakarya University, Faculty of Medicine, Department of Histology and Embryology, Sakarya, Turkey
tugcan.korak@kocaeli.edu.tr

Abstract

Introduction: Prostate cancer is the second most common cancer type among men worldwide. Androgen receptor signaling plays a significant role in its progression. In advanced stages, androgen deprivation therapy is administered as the standard treatment to reduce androgen levels. However, the side effects and loss of efficacy associated with this therapy decrease patients' quality of life, highlighting the need for additional therapeutic strategies. Hydroxychloroquine (HCQ), an inhibitor of autophagy—a cellular degradation mechanism pivotal in carcinogenesis—has been shown to enhance chemotherapy response in prostate cancer patients and increase cytotoxicity in combination therapies. On the other hand, reticulon 4 (RTN4), well-characterized in the nervous system, has been suggested in recent studies to be involved in cell cycle regulation, viability, and immunomodulation in cancer, although its cancer-related mechanisms remain largely unexplored.

Aim: This study aims to investigate the effect of HCQ on RTN4 mRNA expression in androgen-dependent and -independent prostate cancer cells and to functionally annotate potential HCQ-associated RTN4 protein interactors using in silico analysis.

Material-Method: The inhibition concentration (IC50) of HCQ, previously determined in our study, were applied for 72 hours to androgen-dependent (LnCap) and androgen-independent (PC3) prostate cancer cells at concentrations of 52 µM and 44.9 µM, respectively. After total RNA isolation and subsequent cDNA synthesis, RTN4 expression levels were determined using RT-PCR. Differences in expression between groups were analyzed using an unpaired t-test with GraphPad Prism (v8.3.0). Finally, HCQ and RTN4 protein interaction networks were constructed with data from the STITCH and STRING databases. Intersecting proteins within these networks were identified through Cytoscape (v3.10.2), and functional annotation was conducted using Enrichr.

Results: HCQ treatment increased RTN4 gene expression approximately 958-fold ($p<0.0001$) in LnCap cells and 25-fold ($p<0.05$) in PC3 cells. KEGG annotation of HCQ-associated RTN4 targets revealed significant involvement in cancer-related signaling pathways, including those specific to prostate cancer ($p<0.05$). GO Biological Process analysis indicated significant roles in apoptotic signaling regulation, cytokine response, and transmembrane receptor signaling ($p<0.05$).

Conclusion: These findings indicate that RTN4 plays a significant role in prostate cancer, especially in androgen-dependent cases, by affecting apoptosis, cytokine signaling, and cancer-related pathways. HCQ may influence these processes by regulating RTN4 activity beyond its effects on autophagy, suggesting its potential as a therapeutic agent for managing prostate cancer. Future research should explore HCQ-associated RTN4 mechanisms to enhance prostate cancer treatment strategies.

Oral Presentation

LOVASTATIN SYNERGIZES WITH GOT1 INHIBITOR TO KILL CANCER CELLS

ELİF BAYRAM[1] | ABDULLAH YALÇIN[2] | SABİRE GÜLER[3]

[1]Department Of Veterinary Biochemistry, Institute Of Health Sciences, Bursa Uludag University, Bursa, Turkey | [2]Department Of Biochemistry, School Of Veterinary Medicine, Bursa Uludag University, Bursa, Turkey | [3]Department Of Histology And Embryology, School Of Veterinary Medicine, Bursa Uludag University, Bursa, Turkey

elifbbayram@gmail.com

Abstract

Introduction: Glutamate-Oxaloacetate Transaminase 1 (GOT1) is a metabolic enzyme involved in the aspartate-malate shuttle, glutamine metabolism, and the Krebs cycle. GOT1 is overexpressed in cancers and plays a critical role in KRAS-induced metabolic rewiring. Targeting GOT1 alone has antiproliferative effects; however, the potential utility of targeting a single metabolic enzyme may be limited by metabolic redundancy and plasticity associated with KRAS activation.

Objective: This study aims to screen an anticancer drug library in combination with GOT1 inhibition to identify synergistic combinations that show efficacy in KRAS-mutant cancer cells.

Material-Method: To inhibit GOT1, a potent, tryptamine-based derivative small molecule inhibitor called GOT1 inhibitor-1 was used. For screening, an FDA-approved anticancer drug library of 1143 drugs were employed. Screening was performed on the KRAS mutant colorectal cell line HCT116. Cell viability was assessed by the Sulforhodamine B (SRB) assay. Promising combinations were confirmed using the CellTiter-Glo assay. The synergistic effects of lovastatin, an inhibitor of the 3-hydroxy-3-methylglutaryl-CoA reductase (HMGCR) enzyme, and GOT1 inhibitor-1 were further tested on KRAS-mutant pancreatic adenocarcinoma cell lines PANC-1 and MIA PaCa-2. The antiproliferative effect of single drugs and their combinations was also assessed in colony formation assays. TUNEL assay was used to evaluate apoptosis.

Results: The combination of lovastatin, a cholesterol-lowering drug, with GOT1 inhibitor-1 exhibited a significantly greater antiproliferative effect on HCT116, PANC-1, and MIA PaCa-2 cell lines than either inhibitor alone. This combination showed profound synergy based on various synergy models, such as Bliss independence. Lovastatin/GOT1 inhibitor-1 combination induced apoptosis and completely abrogated the colony formation potential of cancer cells, whereas single agents showed no effect, suggesting a synthetic lethality by simultaneous inhibitions of GOT1 and HMGCR.

Conclusion: The combination of GOT1 inhibitor-1 with lovastatin demonstrates a promising therapeutic strategy for targeting KRAS-mutant cancer cells.

Oral Presentation

THERAPEUTIC EFFECTS OF MESENCHYMAL STEM CELL CONDITIONED MEDIUM IN RAT VARICOCELE MODEL

EGE CAN SEREFOGLU[1] | BİRCAN KOLBAŞI[2] | MUHAMMET VOLKAN BÜLBÜL[3] | SEDA KARABULUT[2] | ÇAĞRI ÇAKICI[4] | REYHAN ZEYNEP GUNDOGDU OZDEMİR[5] | İLKNUR KESKİN[2]

[1]Department Of Urology, School Of Medicine, Biruni University | [2]Department Of Histology And Embryology, School Of Medicine, Istanbul Medipol University | [3]Department Of Histology And Embryology, School Of Medicine, Agri Ibrahim Cecen University | [4]Department Of Biochemistry, School Of Medicine, Istanbul Medipol University | 5 Department Of Molecular Biology And Genetics, Faculty Of Engineering And Natural Sciences, Istanbul Health And Technology University | bkolbasi@medipol.edu.tr

Abstract

Introduction: Varicocele is the most common medically treatable cause of male infertility. Considering the paracrine effects of MSCs (Mesenchymal Stem Cells), a new therapeutic approach associated with MSC administration has been introduced. This method is the use of a medium containing biologically active factors and extracellular vesicles, generally called MSC-CM (Mesenchymal Stem Cell-Conditioned Medium). In our study, the therapeutic effects of MSC-CM injection on the varicocele model created in rats were investigated.

Purpose: This study aimed to examine the therapeutic effects of injection of ADMSC-CM (Adipose Derived Mesenchymal Stem Cell- Conditioned Medium) in a surgically created varicocele model in comparison with varicocelectomy.

Materials and Methods: Twenty-eight male Wistar Albino rats were randomly divided into four groups: sham group, varicocele group, varicocelectomy group, and ADMSC-CM injection group. Sperm parameters were analyzed in samples taken from the epididymis after treatment. Malondialdehyde and SOD (Superoxide Dismutase) levels in blood samples were examined by biochemical analysis. The testicular tissues were stained with hematoxylin-eosin for histological examination (Johnsen's Score). Additionally, Western Blot analyzes were performed to detect Claudin-11 levels, the functional protein of the blood-testis barrier, in testicular tissues.

Results: Varicocelectomy and ADMSC-CM treatments significantly improved mean sperm parameters (concentration, progressive motility, motility, normal sperm morphology) ($p \leq 0.05$ for all). Both treatment groups had increased SOD levels along with a decrease in malondialdehyde levels ($p \leq 0.05$ for all). No significant difference was observed between the ADMSC-CM group and the varicocelectomy group in preserving normal testicular histology according to Johnsen's Score ($p=0.114$). Levels of Claudin-11 were significantly higher in the varicocelectomy and ADMSC-CM groups compared to the varicocele group ($p \leq 0.05$ for all).

Conclusions: The therapeutic effects of ADMSC-CM in varicocele model may involve secretion of anti-inflammatory and regenerative factors from ADMSC. ADMSC-CM injection appears to be a promising new strategy in the treatment of varicocele.

Oral Presentation

INVESTIGATION THE EFFECTS OF NIMODIPINE ON EXPERIMENTAL TESTICULAR TORSION/DETORSION MODEL

EBRU KANAK[1], SAMET KARA[1], DİLEK ŞAKER[1], ÖZLEM GÖRÜROĞLU ÖZTÜRK[2], YURDUN KUYUCU[1]

1 Çukurova University, Faculty of Medicine, Department of Histology and Embryology, Adana, Türkiye
2 Çukurova University, Faculty of Medicine, Department of Medical Biochemistry, Adana, Türkiye

Abstract

Introduction: Testicular torsion is one of the most significant causes of acute scrotum, occurring as a result of twisting the spermatic cord and its contents around themselves. Following testicular torsion ischemic injury, and after detorsion reperfusion injury may occure. Although there have been many studies on this topic, a method that prevent Ischemia/Reperfusion (I/R) injury completely has not yet been found. Nimodipine is a calcium channel blocker used to inhibit cerebral vasoconstriction in patients with subarachnoid hemorrhage. Its effects on ovarian and liver ischemia have been previously studied, and it has been shown to improve I/R injury.

Objective: In our study, investigation the potential therapeutic effects of nimodipine on experimental testicular torsion/detorsion model was aimed.

Materials and Methods: Forty male Wistar-Albino rats, weighing between 250-300 grams, were divided into 5 groups (n=8); sham group, testicular torsion group (TT), testicular torsion/detorsion group (TT/D), testicular torsion + nimodipine group (TT/N), and testicular torsion/detorsion + nimodipine group (TT/D/N). Before sacrifice, blood samples were collected from the rats to analyze SOD activity, serum MDA and testosterone concentrations. Testicular tissue samples were prepared for light and electron microscopic examinations. Additionally, testicular tissue sections were investigated immunohistochemically for the apoptotic marker caspase-3 and the inflammation marker TNF-α.

Results: In the TT and TT/D groups, thickening, hemorrhage, and edema in the tunica albuginea, degenerative, lytic, and apoptotic changes in the seminiferous tubules, edema and hemorrhage in the interstitial area, and degenerative changes in Leydig cells were observed. In the groups treated with nimodipine (TT/N and TT/D/N), a relatively normal morphology was observed. Significant increases in caspase-3 and TNF-α immunoreactivities were seen in the seminiferous tubule cells and Leydig cells in the interstitial area of the TT and TT/D groups, while both immunoreactivities were significantly reduced in the TT/N and TT/D/N groups. In the TT and TT/D groups, a significant increase in serum MDA concentrations was observed, while SOD activity and serum testosterone concentrations were markedly decreased. In the TT/N and TT/D/N groups, SOD activity and serum testosterone concentrations showed significant increases compared to the damage groups, while serum MDA concentrations were significantly decreased.

Conclusion: In conclusion, nimodipine treatment demonstrated therapeutic effects on the structural changes and biochemical impairments observed in the TT and TT/D groups, suggesting that it could be used as an alternative therapeutic agent in testicular I/R injury. However, further experimental and clinical studies are needed to confirm these findings.

Keywords: Testicular torsion/detorsion, nimodipine, calcium channel blocker.

Oral Presentation

THERAPEUTIC POTENTIAL OF NICOTINAMIDE RIBOSIDE IN MITIGATING MUSCLE TISSUE DEGENERATION ASSOCIATED WITH POLYCYSTIC OVARY SYNDROME: A HISTOPATHOLOGICAL EVALUATION

ÜMİT AYGÜN[1] | SEÇİL NAZİFE PARLAK[2] | HABİBE GÜNDOĞDU[3]

[1]Faculty Of Medicine, Department Of Orthopaedics And Traumatology, Ağrı İbrahim Çeçen University, Ağrı, Türkiye |[2] Department Of Histology And Embryology, Faculty Of Medicine, Ağrı İbrahim Çeçen University, Ağrı/Türkiye | [3]Department Of Histology And Embryology, Faculty Of Medicine, Ataturk University, Erzurum, Türkiye , habibe.kars@hotmail.com

Abstract

Introduction: Polycystic Ovary Syndrome (PCOS) is a common endocrine disorder in women, associated with various metabolic and reproductive health issues, including potential muscle tissue degeneration. Nicotinamide Riboside (NR) is a compound known for supporting cellular energy metabolism and reducing inflammation. This study investigates the effects of NR on muscle tissue degeneration associated with PCOS.

Objective: This study aimed to evaluate the therapeutic potential of Nicotinamide Riboside (NR) in the context of Polycystic Ovary Syndrome (PCOS) by assessing histopathological changes in femoral muscle tissues across different experimental groups.

Materials and methods: Femoral muscle tissue samples were fixed in 10% neutral buffered formalin for 48 hours, followed by graded dehydration and xylene clearing. The tissues were then embedded in paraffin, sectioned at a thickness of 4 µm, and mounted onto slides. The slides were incubated at 60°C for 30 minutes and deparaffinized using a series of xylene treatments. After rehydration, the sections were stained with hematoxylin for nuclear visualization and counterstained with eosin for cytoplasmic contrast. Subsequent to dehydration and xylene clearing, the sections were mounted with Entellan and examined under a light microscope to evaluate tissue morphology.

Results: In the control group, the striated muscle tissues maintained a normal histological architecture. In contrast, the PCOS group exhibited significant degeneration of striated muscle cells, characterized by myofibril separation, disruption of the connective tissue matrix, increased fibril content in the connective tissue, and infiltration of inflammatory cells into the connective tissue. The NR group showed an improvement and significant reduction in myofibril separation in the striated muscle cells compared to the PCOS group, with features more closely resembling those of the control group. However, the number of inflammatory cells remained higher in the NR group than in the control group but lower than in the PCOS group.

Conclusion: These findings suggest that NR may have a therapeutic role in alleviating muscle tissue degeneration associated with PCOS.

Keywords: Polycystic Ovary Syndrome (PCOS), Nicotinamide Riboside (NR)

Oral Presentation

EFFECTS OF TFG-B1 ON AB-40 AND A- B- Γ SECRETASE EXPRESSION IN HIPPOCAMPUS AND PREFRONTAL CORTEX IN EXPERIMENTAL ALZHEIMER'S DISEASES

SAMET KARA[1] , SEMA POLAT[2] , KUBRA AKILLIOGLU[3] , DİLEK ŞAKER1 , AHMET TURAN EVLİCE[4] , LEMAN SENCAR[1], GÜLFİDAN COŞKUN[1], FULDEN UMRAN BOZKAYA[5], SAİT POLAT[1]

1Department of Histology and Embryology, Faculty of Medicine, University of Çukurova, 01330 Balcali, Adana, Turkey
2Department of Anatomy, Faculty of Medicine, University of Çukurova, 01330 Balcali, Adana, Turkey
3Department of Physiology, Faculty of Medicine, University of Çukurova, 01330 Balcali, Adana, Turkey
4Department of Neurology, Faculty of Medicine, University of Çukurova, 01330 Balcali, Adana, Turkey
5Department of Biochemistry, Faculty of Medicine, University of Çukurova, 01330 Balcali, Adana, Turkey
asmtkara@gmail.com

Abstract

Introduction: Alzheimer's disease (AD) is a chronic complex neurodegenerative disease characterized amyloid plaques and neurofibrillary tangle formation, loss of neurons and synapses, and marked atrophy in the brain. Transforming growth factor β1 (TGF-β1) is an important growth factor with critical roles in cell metabolism, tissue homeostasis, neuronal development, and synaptic plasticity.

Aim: This study, it was aimed to examine the effect of TGF-β1 on the regulation of α, β, and γ-secretase enzymes, Aβ-40 accumulation, apoptosis, and neuronal damage in experimental AD-like disease model.

Material-Method: Eighty-eight male Swiss-Albino mice were randomly divided into 5 groups; the control group without any treatment, the sham group in which only saline as applied, the group in which TGF-β was administered, the experimental group in which Scopolamine was applied for 28 days, and the treatment group in which Scopolamine and TGF-β1 was applied. The mice in the treatment group were also divided into 2 subgroups. To examine the long-term effects of the applied methods, sham, TGF-β1 control, experiment, treatment-1, and treatment-2 groups were followed until the 56th day, and the Moris water maze test (MWM) was applied on the 28th and 56th days, and memory functions were examined. Hippocampus and prefrontal cortex tissues taken from all groups on the 28th and 56th days were examined by light and electron microscopic, immunohistochemical, and biochemical methods. The GraphPad Prism and SPSS-23 software was used to evaluate the obtained data and to determine whether the data have a normal distribution, The "D'Agostino & Pearson omnibus normality test" was carried out. Mann Whitney U test was used to compare the differences in immunoreactivity scores and biochemical data expression discrepancies between experimental and control groups.

Results: In the MWM test, it was observed that memory performance decreased in the experimental groups, while memory performance in the treatment groups increased statistically significantly compared to the experimental group. In the experimental group, it was observed that Aβ-40 and caspase-3 immunoreactivity increased statistically significantly

in the hippocampus and prefrontal cortex on the 28th and 56th days, and immunoreactivity decreased significantly as a result of TGF-β1 treatment. Structural changes were detected in neurons and glial cells in the experimental groups in light and electron microscopic examinations. It was noteworthy that cellular changes were relatively reduced in the TGF-β1 treatment groups. It was observed that α-secretase expression decreased significantly in the experimental groups compared to the control group, and increased significantly in the treatment groups.

Conclusion: As a result of, it can be effective in preventing the disease with its regulatory role on α, β, and γ-secretase enzymes. When all the findings were evaluated together, it was concluded that TGF-β1 could be evaluated as a therapeutic agent in Alzheimer's disease.

Oral Presentation

UNRAVELLING THE IMPACT OF COVID-19 ON PREGNANCY: IN ASPECT OF PLACENTAL HISTOPATHOLOGY AND UMBILICAL CORD MACROPHAGE IMMUNOACTIVITY WITH NEONATAL OUTCOMES

ŞÜKRİYE LEYLA ALTUNTAŞ[2] | ARZU GÜNEŞ[1] | ARİFE AHSEN KAPLAN[1] NEŞE AYŞİT[3] | İLKNUR KESKİN[1]

[1]Istanbul Medipol University, School Of Medicine. Department Of Histology And Embryology
[2] Istanbul Medipol University, School Of Medicine. Department Of Gynecology And Obstetrics
[3]Istanbul Medipol University, School Of Medicine. Research Institute For Health Sciences And Technologies
arzu.gunes@medipol.edu.tr

Abstract

Introduction: COVID-19, first identified in 2019, has rapidly evolved into a global pandemic, posing significant public health challenges worldwide. The virus has caused widespread illness and death, overwhelming healthcare systems and prompting urgent research into its effects. Pregnant women and newborns are considered particularly vulnerable due to potential complications arising from infection. Understanding the specific impact of COVID-19 on these groups is crucial for developing targeted healthcare strategies.

Objective: This study aimed to investigate the effects of COVID-19 on pregnant women and their newborns. By focusing on the analysis of histopathological changes in placental and umbilical cord tissues associated with COVID-19, we evaluated maternal and neonatal outcomes to determine the impact of COVID-19 on pregnancy and birth. Through this examination, we aimed to provide insights into the risks and implications of COVID-19 for these vulnerable populations.

Material-Method: We conducted histopathological examinations of placentas and umbilical cords from two groups of pregnant women. Group I comprised women who had never tested positive for COVID-19 during pregnancy (n = 20), while Group II included women who had contracted COVID-19, displayed mild to moderate symptoms, and recovered before delivery (n = 23). Additionally, immunofluorescence techniques were employed to detect macrophage activity in the umbilical cord. Prenatal assessments included maternal complete blood counts and coagulation assays (n = 40 in both groups). Neonatal outcomes were evaluated based on birth weight, length, head circumference, and APGAR scores (n = 40 in both groups).

Results: Our findings indicate that COVID-19 induces placental and umbilical cord inflammation and results in maternal and foetal vascular malperfussion. Immunofluorescence analyses showed a significant increase in umbilical cord macrophage numbers and the macrophage-to-total cell ratio in the COVID-19 group. This study is the first to report on macrophage activity in Wharton's jelly in pregnant women who have recovered from COVID-19. Furthermore, we found that COVID-19 shortens gestation periods and reduces maternal haemoglobin levels.

Conclusion: COVID-19 with mild to moderate symptoms during pregnancy causes notable alterations in the placenta and umbilical cord but, fortunately, does not significantly affect neonatal outcomes.

Keywords: COVID-19, immunofluorescence, inflammation, macrophage, placenta, umbilical cord

Oral Presentation

THE EFFECTS OF SYSTEMIC BORIC ACID ADMINISTRATION ON EMBRYONIC DEVELOPMENT İN PREGNANT RATS WITH EXPERIMENTALLY INDUCED PERIODONTITIS

***NAZLI ÇİL[1] | HAVVA MÜGE BALSEVEN[2] | ALPER KIZILDAĞ[3] | ŞAHİKA PINAR AKYER[4] | *NAZİRE GÜL NEŞET[1] | ERGUN METE[5] | CANAN ÖNDER[6] | YAŞAR ENLİ[7] | GÜLÇİN ABBAN METE[1]**

[1]Pamukkale University, Faculty Of Medicine, Department Of Histology And Embryology | [2]Dent 20 Oral And Dental Health Center, Department Of Periodontology, Pamukkale, Denizli, Turkey, | [3]Pamukkale University, Faculty Of Dentistry, Department Of Periodontology | [4]Pamukkale University, Faculty Of Medicine, Department Of Anatomy, | [5]Pamukkale Pamukkale University, Faculty Of Medicine,Department Of Microbiolog | [6]Ankara University, Faculty Of Dentistry, Department Of Periodontology, Ankara, Turkey | [7]Pamukkale University, Faculty Of Medicine, Department Of Biochemistry | gul.neset@windowslive.com

Abstract

The objective of this study was to examine the impact of varying doses of boric acid (BA) on pregnant rats with experimentally induced periodontitis by ligature.

In the study, 60 Wistar Albino adult female rats were randomly divided into six groups. The groups were as follows: A periodontally healthy, non-pregnant control group (NL, n:10); A periodontally healthy, pregnant control group (NLP, n:10); A periodontitis and pregnant group not administered BA (LP, n:10); A periodontitis, pregnant group administered 1.5 mg/kg/day BA (BA1, n:10); Periodontitis and pregnant group administered 3 mg/kg/day BA (BA3, n:10); Periodontitis and pregnant group administered 6 mg/kg/day BA (BA6, n:10). The administration of BA was conducted via intraperitoneal injection to the pregnant rats over a period of 20 days. At the end of 20 days, blood samples were collected from the rats and the expression of IL-33, TNF-alpha, IL-6, IL-1β and RANKL was determined using the ELISA method. Malondialdehyde (MDA) and glutathione (GSH) were quantified in liver and placenta tissues obtained from all rat groups. The expression of interleukin-33 (IL-33), tumour necrosis factor-alpha (TNF-alpha), IL-6, IL-1beta and receptor activator of nuclear factor-kappa beta ligand (RANKL) in gingiva, liver and placenta tissues was evaluated histopathologically and immunohistochemically.

No significant difference was observed between the initial and final weight measurements and the number of gestational sacs in the experimental groups ($p>0,05$). However, the formation of gestational sacs was not observed in three rats within the BA6 group. A comparison of the gingival tissues of the groups revealed that the BA treatment resulted in an improvement in the histological appearance and scoring at the treatment period ($p<0,05$). The highest expression of RANKL was observed in the gingival tissue in the immunohistochemical examination. The expression of IL-1 in liver tissue was observed in all groups. However, there was a notable expression of IL-33 and RANKL. While the placenta of the periodontitis pregnant group exhibited prominent degeneration, the BA3 group demonstrated a notable reduction in such alterations. The expression of RANKL was markedly positive in the PG and BA6 groups, while it was only moderately positive in the BA1 and BA3 groups ($p<0.05$).

In conclusion, in this experimental study, 1.5 mg/kg and 3 mg/kg BA treatment was effective in the improvement of periodental infection in pregnant rats in biochemical and histopathological examinations, but 6 mg/kg BA treatment did not improve the histopathological findings of pregnancy development and had a negative effect.

Keywords: Periodontitis, pregnancy, rat, ligature, boric acid

Oral Presentation

SYNERGISTIC EFFECT OF BENZTROPINE AND LDHA INHIBITOR IN PANCREATIC CANCER: A NOVEL THERAPEUTIC APPROACH

ÖNER SÖNMEZ[1] | ABDULLAH YALÇIN[1] | SABİRE GÜLER[2]

[1]Veterinary Biochemistry | [2]Veterinary Histology And Embryology
onersonmez@uludag.edu.tr

Abstract

Introduction: Pancreatic ductal adenocarcinoma (PDAC) is a highly lethal malignancy, representing approximately 90% of all pancreatic cancers and characterized by an exceptionally low five-year survival rate of around 10% due to its aggressive nature and typically late diagnosis. Recent research has identified Lactate dehydrogenase A (LDHA) as a pivotal enzyme in the metabolic reprogramming of PDAC cells, specifically through its role in the Warburg effect, where glycolysis predominates even in the presence of oxygen. Targeting LDHA has shown promise in inhibiting tumor growth and altering the tumor microenvironment. Additionally, benztropine, traditionally used as an antiparkinsonian drug, has emerged as a potential therapeutic agent in PDAC, demonstrating efficacy in reducing tumor growth and metastasis by modulating the tumor microenvironment.

Aim: This study aims to investigate the therapeutic potential of combining LDHA inhibition with benztropine in PDAC cell lines.

Material-Method: PDAC cell lines, PANC-1 and MIA PaCa-2, were utilized to evaluate the effects of various treatments. The cells were divided into four experimental groups: control (treated with DMSO), LDHA inhibition (treated with FX-11), benztropine, and the combination of LDHA inhibition with benztropine. Cell viability was assessed using the Sulforhodamine B (SRB) assay, with promising drug combinations further validated through the CellTiter-Glo assay. Synergistic interactions between treatments were quantified using the SynergyFinder online tool, and combination indexes (CI) were calculated. The antiproliferative effects of individual drugs and their combinations were analyzed through colony formation assays, while apoptosis was measured using the TUNEL assay.

Results: The combination of LDHA inhibition and benztropine at various concentrations demonstrated significant synergistic effects in PDAC cell lines. Notably, the combination index (CI) values, indicating synergy (CI < 1), were 0.74 for 20 µM benztropine combined with 20 µM FX-11 in MIA PaCa-2 cells, and 0.01 for the same combination in PANC-1 cells. These synergistic combinations effectively induced apoptosis and completely inhibited colony formation in cancer cells, while treatment with the individual agents alone produced minimal effects. These results suggest a synthetic lethality achieved through the concurrent inhibition of LDHA and benztropine in pancreatic cancer cells.

Conclusion: This study reveals that combining LDHA inhibition with benztropine significantly enhances the therapeutic effects in PDAC cell lines, leading to increased apoptosis and complete inhibition of colony formation. The observed synergy suggests that this combination could offer a promising new approach for improving treatment outcomes in pancreatic cancer.

Oral Presentation

THE HUMAN UMBILICAL CORD IS NOT COVERED BY A SINGLE LAYER BUT A DISTINCTIVE MULTILAYERED EPITHELIUM

EZEL ERKAN[1] | BİLGE SERDAROĞLU[1] | İBRAHİM ALPTEKİN[1] | DİLEK ŞAHİN[2] | DERYA UYAN HENDEM[2] | FERDA TOPAL ÇELİKKAN[1] | ALP CAN[1]

1 Laboratory For Stem Cells And Reproductive Cell Biology, Department Of Histology And Embryology, Ankara University School Of| 2 Perinatology Clinics, Obstetrics And Gynecology Department, Ankara Bilkent City Hospital | ezelerkan@gmail.com

Abstract

Introduction: The placenta, umbilical cord (UC), and associated amniotic membranes are typically regarded as residual organs of parturition and are discarded after birth. Despite having reached the final stages of differentiation, these are significant interest due to the presence of epithelial and mesenchymal cellular components.The epithelial tissue that covers the UC is typically referred to as the 'umbilical cord epithelium' or 'cord lining' in previous studies. These terms refer exclusively to the surface epithelium sheath. It is therefore more informative to use the term 'umbilical cord epithelium' (UCE) in order to distinguish it from its placental counterpart, as opposed to simply referring to it as amniotic epithelium.In the period following the historically significant articles, only a few more from the 1980s to the early 2000s have concentrated exclusively on the tissue specimens. The objective of these studies was to assess the distribution of cytoskeletal and cornified epithelial cell-specific proteins. More recently, some stem cell markers have been investigated in this relatively unidentified epithelial tissue.

Objective: The objective of this study is to provide a detailed description of the distinct structural characteristics and the abundance of specific proteins in this unique UCE, many of which have not yet been demonstrated in previous studies.

Material – Method: UCs were obtained by Caesarean section, approximately 20 cm away from the umbilicus, specifically from the proximal one third of the cord. Samples were placed in appropriate fixatives for examination under light, transmission and scanning electron microscopes. Toluidine blue stained semi-thin sections and periodic acid-Schiff stained and hematoxylin-eosin stained cryosections were examined under light microscope. Several cytoskeletal, basement membrane and junctional proteins immunofluorescence (IF) stained and observed by super-resolution confocal microscopy.

Results: UCE displayed a range of stratification, ranging from a single squamous layer to 4-5 layers of round/cuboid cells, challenging the notion of considering it as a single-layered structure. During TEM observations of control cords, it was noted that the outer lining of the cords exhibited distinctive features that could not be classified among the known epithelial types due to the high degree of variability observed. Moreover, our IF findings have revealed several distinctive structural features and provided detailed insights into selected in situ protein distributions.

Conclusion: Our study offers a comprehensive overview of the human UCE. It is not accurate to consider UCE as representing a single or stratified epithelial form. It constitutes a discrete entity, exhibiting a thickness of between two and five layers, situated in close proximity to the continuous basal membrane.

This study received partial funding from TÜBİTAK 121S821 and the Ankara University Scientific Research Fund TSG-2020-2545.

Oral Presentation

THE EFFECT OF TOTAL PROGRESSIVE SPERM DENSITY ON PREGNANCY PREDICTION IN COUPLES UNDERGOING IUI FOR MALE INFERTILITY

ÇİĞDEM KARACA[1], SELİN SEYMEN KENAN[2], AYŞE GÜLÜŞÜR[2], DİLŞAD ARISOY DEMİR[2], ÖZLEM AKAY[3]

1Gaziantep Islamic Science and Technology University Faculty of Medicine, Department of Histology Embryology
2Gaziantep City Hospital ART Clinic
3Gaziantep Islamic Science and Technology University Faculty of Medicine, Department of Biostatistics
drc_karaca@hotmail.com

Abstract

Introduction: Male infertility is known as the inability of a couple to have children due to various known or yet undetermined reasons such as hormonal disorders, infections, varicocele, cryptorchidism in the male individual. In these couples, the woman has no impediments to pregnancy and the success rates of treatment with assisted reproductive techniques (ART) are considered to be high. Intrauterine insemination (IUI) is preferred as first-line treatment in this group of patients because it is cheaper, easier to use and less invasive than other ART, but its success rate is lower than in vitro fertilisation (IVF) and intracytoplasmic sperm injection (ICSI). Semen analysis is one of the first steps in determining the cause of infertility and provides important information for the selection of ART. In the treatment of male infertility with IUI, studies on the effect of semen parameters on pregnancy outcomes have reported very variable results and have emphasised the need for comprehensive studies on this topic.

Objective: The aim of this study was to investigate the predictive effect of sperm parameters on pregnancy in couples who planned IUI treatment for male infertility.

Material and Methods: In our study, spermiogram data obtained from 57 couples diagnosed with male infertility who applied to Gaziantep Cengiz Gökçek Obstetrics and Gynecology Hospital ART Clinic and underwent IUI between July 2021 and July 2023 and demographic data of the patients were used. Before IUI, ovulation induction with aromatase inhibitor and recombinant FSH was performed in the female patient. Semen was collected from the male patient on the day of the procedure, semen analysis was performed and the semen prepared by applying the semen preparation protocol was injected into the uterus with an insemination catheter. Pregnancy of the patients was evaluated with serum beta hCG on the 14th day after the procedure.

Results: In our study, the positive pregnancy rate in couples who underwent IUI was 10.5% (6/57).A significant correlation was found between patients' Total Progressive Motile Sperm (TPMS) density and post-wash Total Progressive Motile Sperm Count (TPMSC) and pregnancy positivity (p=0.035, p=0.017) (Table).

Conclusion: It has been observed that the calculation of TPMS density and post-wash TPMSC in the semen evaluation performed at the first visit of couples presenting to the clinic for male

infertility is an important step in predicting pregnancy outcome. We believe that by assessing TPMS density in these patients, pregnancy outcome can be predicted and unnecessary IUI procedures avoided.

Oral Presentation

ENHANCED EFFICACY OF DOXORUBICIN BY ELECTROPORATION: EFFECTS ON LUNG CANCER CELL VIABILITY AND MORPHOLOGY

ÇAĞLA ZÜBEYDE KÖPRÜ[1] | BURCU BABA[2] | DİLEK YONAR[3] | WOJCİECH SZLASA[4] | ANNA CHOROMANSKA[5]

[1]Department Of Histology And Embryology, Faculty Of Medicine, Yuksek Ihtisas University, Ankara, Türkiye | [2]Department Of Medical Biochemistry, Faculty Of Medicine, Yuksek Ihtisas University, Ankara, Türkiye | [3]Department Of Biophysics, Faculty Of Medicine, Yuksek Ihtisas University, Ankara, Türkiye | [4]Faculty Of Medicine, Wroclaw Medical University, Wroclaw, Poland | [5]Faculty Of Pharmacy, Department Of Molecular And Cellular Biology, Wroclaw Medical University, Wroclaw, Poland
caglakopru@yiu.edu.tr

Abstract

Background: Doxorubicin (DOX) is one of the well-known chemotherapeutic agents used to treat various cancers, including lung cancer. However, due to cancer cells' resistance to cytotoxic drugs, chemotherapeutic treatment may not be effective. Therefore, there is a need for new strategies for the delivery of these types of drugs. Electroporation (EP)-based treatments that cause increased plasma membrane permeability have recently received significant attention. EP reduces the required dosage of cytotoxic drugs while increasing their efficacy.

Aim: The aim of this study is to investigate the effect of electroporation in enhancing the cytotoxic effects of DOX on A549 cells.

Methods: The lung cancer A549 cells were treated with DOX (1.6 µM) alone, in combination with EP, and without EP. In the EP experiment, control cells and cells treated with a low DOX concentration were placed into a cuvette with aluminum electrodes and pulsed with 8 square pulses of 1000V/cm, 1500V/cm, and 2000V/cm, with a pulse duration of 0.1ms. The cell viability was evaluated by the PrestoBlue assay after 24 hours. Holotomographic microscopy was used to observe the morphological changes in cells.

Results: Electroporated cells were found to have lower viability compared to control cells. A statistically significant decline in cell viability was seen in cells treated with DOX and EP compared to those treated with DOX alone. Additionally, when comparing cells treated with DOX and EP at different pulses, a significant decrease in cell viability was found at 1500 V/cm and 2000 V/cm compared to 1000 V/cm. No statistically significant difference in cell viability was observed between DOX treatment at 1500 V/cm and 2000 V/cm pulses. According to holotomography results, cell membrane blebbing and vesicle formation were notably observed in cells treated with DOX alone and in EP-applied DOX-treated cells. When comparing the DOX alone with EP-applied DOX-treated cells, apoptotic figures were observed to be more in combination with DOX with EP.

Conclusion: Our results demonstrated that electroporation enhanced the cytotoxic effect of DOX by inducing apoptotic body formation in lung cancer cells. It was concluded that electroporation may improve the effectiveness of drugs in treating lung cancer.

Keywords: lung cancer, electroporation, holotomography, doxorubicin

Oral Presentation

THE EFFECT OF ACTIVATED PLATELET RICH PLASMA ON IN VITRO SPERMATOGENESIS IN TESTIS ORGANOIDS

MERVE BULUT[1] | SELİN ÖNEN[2] | MERVE GİZER[3] | ZELİHA CANSEL ÖZMEN[4] | PETEK KORKUSUZ[5] | NİLGÜN ÖKSEL[1]

[1]Gaziosmanpaşa University, Faculty Of Medicine, Department Of Histology And Embryology, Tokat, Turkey, | [2]Odtü Mems Center | Odtü Mems Center | [3]Gaziosmanpaşa University, Faculty Of Medicine, Department Of Medical Biochemistry, Tokat, Turkey, | [4]Hacettepe University, Department Of Histology And Embryology, Faculty Of Medicine, Ankara, Turkey, |nilgun.yersal@gop.edu.tr

Abstract

Introduction: Infertility affects 10-20% of sexually active couples and male-related factors contribute 30-50% of these cases. Obtaining sperm from spermatogonial stem cells (SSC) by in vitro spermatogenesis in infertile patients is the promising approache for couples who want to have their own biological children. Three-dimensional (3D) in vitro culture systems mimic in vivo environment by cell-cell and cell-extracellular matrix (ECM) interactions. Germ and somatic cells can reorganize to form testis organoid or culture of testicular pieces support differentiation of SSCs into sperm by 3D culture systems. One of the most important limitations of these approaches is that the culture media are supplemented with undefined nature of serum and/or xenogenic growth factors. It is known that platelet rich plasma (PRP) has a regenerative effect on spermatogenesis and testicular regeneration after testicular damage and PRP maintains the proliferation and function of SSCs in vitro.

Objective: Activated PRP can preserve the SSC pool in testicular organoids and support spermatogenesis in vitro. To test this assumption, it was aimed to evaluate the effect of activated PRP on spermatogenesis in 3D testicular organoid cultures.

Material and method: Prepubertal C57BL/6 testicular cells were cultured in culture medium supplemented with activated PRP by ultra-low attachment and air-liquid interphase culture methods for 6 weeks, and the effect of activated PRP on in vitro spermatogenesis was evaluated histomorphometrically and immunohistochemically at 1, 3, 4 and 6 weeks.

Results: In testicular organoids supported with 10% PRP, the SSC pool was preserved for 6 weeks and the number of ID4(+) SSCs was found to be higher than in testicular organoids supported with 10% KSR and 5% FBS+5% KSR at 3, 4 and 6 weeks. In testicular organoids supported with 10% PRP, the number of SCP3(+) spermatocytes remained constant from week 1 to 6 and higher than in testicular organoids supported with 10% KSR and 5% FBS+5% KSR at 4 and 6 weeks. In testicular organoids supported with 10% KSR, 5% FBS+5% KSR and 10% PRP, the ACR(+) round spermatids was observed at week 3 and the number of ACR(+) spermatids was higher in testicular organoids supported with 10% PRP compared to testicular organoids supported with 10% KSR at week 4.

Conclusion: The overall data demonstrated the positive effect of activated PRP on in vitro spermatogenesis. Thus, activated PRP can be used as a safe culture platform in the the teratment of infertility without risk of potential immunological reaction and viral contamination.

Oral Presentation

COMPARATIVE ANALYSIS OF ETHANOL EXTRACTS FROM RHEUM RIBES L. ON THE VIABILITY OF TM3 LEYDIG CELLS UNDER NORMOXIC AND HYPOXIC CONDITIONS

NUR ELAGÜL TOMBUL[1] | GÜL İPEK GÜNDOĞAN[2] | EBRU ÖZDEMİR NATH[2]

[1]Research Assistant | [2]Associate Professor | n.elagul1@hotmail.com

Abstract

Introduction: Rheum ribes L. (Işgın) is a rhubarb species from the Polygonaceae family, which grows naturally mostly in the Eastern Anatolia Region of Turkey and attracts attention with its high anthraquinone content. It is also used in traditional medicine to combat diseases such as stomach and kidney disorders, diabetes, cholesterol, and in pharmacology as an anti-aging, cell regenerator, antimicrobial, aphrodisiac, anti-inflammatory and antioxidant.

Objective: This study investigates the comparative effect of 96% and 70% ethanol (EtOH) extracts of stem, root and seed parts of Rheum ribes L. on the viability rates of normal and hypoxia-exposed TM3 mouse Leydig cells based on the antioxidant and cell regenerative properties reported in the literature.

Material-Method: The stem, root and seed parts of the plant were dried and powdered and 96% and 70% EtOH extracts were obtained by maceration method. TM3 cell line was cultured under in vitro conditions. Then the cells were planted in 96-well plate dishes. 3-(4,5-Dimethylthiazol-2-yl)-2,5-Diphenyltetrazolium Bromide (MTT) assay analyses were performed for all extracts in the concentration range of 0.0025-0.5 mg/mL at 24-48-72 hours. The first concentration showing a significant difference compared to the control was applied to cells exposed to hypoxic environment (200 µM CoCl2) for 24 hours and the viability rates (%) were determined by the MTT assay. The findings were analyzed statistically and $p<0.05$ was accepted as significant.

Results: Lower concentrations of 70% EtOH stem extracts and higher concentrations of 96% EtOH stem extracts significantly increased cell viability at 48 hours. Under hypoxic conditions, both extracts improved viability compared to the hypoxia control, with 96% EtOH being more effective than 70% EtOH (26% and 12%, respectively). For root extracts, 70% EtOH was more effective at 48 hours, but under hypoxia, viability in 96% EtOH extracts increased significantly (74%), nearing control group levels. For seed extracts, higher doses of 70% EtOH increased viability more than 96% EtOH at 48 hours. In hypoxia, 70% EtOH was more effective than both 96% EtOH and the control (viability increase rate; 70% EtOH: 168%, 96% EtOH: 106%).

Conclusion: Both 70% EtOH and 96% EtOH extracts obtained from stem, root and seed parts of R. ribes L. species seem to increase the viability rate significantly compared to the control group under hypoxic conditions. However, 96% EtOH seed and root extracts and 70% EtOH seed extract seem to show antioxidant properties by protecting cells from hypoxic environment compared to the control group.

Keywords: Cell viability, hypoxia, normoxia, Rheum ribes L., TM3 Leydig cell

Oral Presentation

IMMUNOHISTOCHEMICAL LOCALIZATION OF TGF-A AND TGF-B1 IN THE GOOSE (ANSER ANSER) EYE

DİLEM GÜLECE ERMUTLU | SERAP İLHAN AKSU | SERAP KORAL TAŞÇI | TURGAY DEPREM | ŞAHİN ASLAN | RUMEYSA NUR ASLAN

Kafkas University / Faculty of Veterinary Medicine
dilemermutlu@gmail.com

Abstract

Introduction: Poultry have eyes with excellent resolution and very good vision. Anatomically, the organ of vision consists of the eyeball (bulbus oculi) and the appendages (organa oculi accesoria). The histologic structure of the eyeball consists of three layers: tunica fibroza (tunica externa), tunica media (uvea) and tunica interna (retina).

Purpose: In the literature search, histologic studies were found in various avian species, but they were not detailed in terms of immunohistochemical staining. The aim of this study was to determine the histological structure of goose eyes as well as the immunohistochemical localization of TGF-α and TGF-β1 and to contribute to the literature.

Materials and Methods: In our study, eye tissues of eight geese slaughtered for consumption by local breeders were used as material. Crossmann's Triple Staining technique was used to show the general histological structure of the tissue and immunohistochemical procedures were performed to examine the immunohistochemical localization of TGF-α (Transorming growth factor- α) and TGF-β1 (Transorming growth factor- β1).

Results: Examination of the eye tissue identified cornea and sclera. A layer of hyaline cartilage was detected in the sclera. The corneal epithelium was found to consist of multilayered squamous non-keratinized epithelium. Keratocytes were distinguished in the stroma. The descement membrane was observed in the lowest layer. Striated muscles are detected in the iris of the uvea. In addition, the stroma of the corpus ciliare and processus ciliaris and the pigmented and non-pigmented epithelial layer were differentiated. It has been observed that the retina consists of ten layers. TGF-α and TGF-β1 immunoreactivity was determined in avian eye tissue. TGF-β1 was found to react more intensely than TGF-α.

Conclusion: It was determined that TGF-β1, which acts as an immunosuppressor in eye tissue, was secreted in the iris and processus ciliaris and also showed immunoreactivity in the corneal stroma. In contrast, TGF-α was found to give a very weak immunoreactivity in the goose eye. In this study, the presence of TGF-α and TGF-β1 in poultry eye tissue was determined.

Oral Presentation

ROLE OF CD4$^+$CXCR5$^+$ T FOLLICULAR HELPER CELLS IN AUTOIMMUNE HEPATITIS: INCREASED CELL POPULATION WITH DOWNREGULATED IL-21 EXPRESSION

GULAM HEKİMOGLU[1], SEVİNC KESER[2], SELMA SENGİZ ERHAN[3], GAMZE YESİLAY[4], HANİ ALSAADONİ[5], HALİME TUBA CANBAZ[6], KUBRA SEVGİN[1]

1Department of Histology and Embryology, International School of Medicine, University of Health Sciences, Istanbul, Turkey
[2]Department of Pathology, Kartal Dr. Lutfi Kirdar City Hospital, University of Health Sciences, Istanbul, Turkey
[3]Department of Pathology, Prof. Dr. Cemil Tascıoglu City Hospital, University of Health Sciences, Istanbul, Turkey
[4]Department of Molecular Biology and Genetics, Hamidiye Institute of Health Science, University of Health Sciences, Istanbul, Turkey
[5]Department of Biology, School of International Medicine, University of Health Sciences, Istanbul, Turkey

Abstract: Autoimmune hepatitis (AIH) is a chronic inflammatory liver disease of yet unknown etiology characterized by elevated serum levels of immunoglobulin G (IgG), and autoantibodies. It shows pathologically plasma cell-dominated inflammatory cell infiltration and signs of interface hepatitis. T follicular helper (Tfh) cells have been shown to play a crucial role in autoimmune diseases by producing interleukin (IL)-21. However, its role in AIH remains to be further elucidated. In the present study, we aimed to examine the gene expression of IL-21, and protein expression of CXCR5, PD-1, and ICOS in AIH biopsies and to determine the role of the tissue-resident Tfh cells in the pathogenesis of AIH.
Eighteen healthy subjects and twenty patients with AIH were included in the current investigation. qRT-PCR quantified the expression of the IL-21 gene. Immunofluorescence double staining was used with the CD4+CXCR5+, PD-1+CXCR5+, and PD-1+ICOS+ combinations to demonstrate the role of tissue-resident Tfh cells in AIH. Compared to healthy controls, AIH patients exhibited significantly greater CD4+CXCR5+, PD-1+CXCR5+, and PD-1+ICOS+ Tfh cells in their inflammatory cells ($p < 0.05$), respectively. Compared to healthy controls, AIH had a reduced IL-21 expression ($p < 0.001$).

In summary, compared to healthy controls, the liver biopsies of patients with AIH showed a substantial increase in the number of tissue-resident Tfh cells, specifically CD4+CXCR5+, PD-1+CXCR5+, and PD-1+ICOS+. Despite this increase, AIH patients had much lower levels of IL-21 gene expression. These results suggest that Tfh cells may be involved in the pathology of AIH. However, the lower expression of IL-21 indicates that these cells have a more intricate role in AIH, requiring greater investigation into the processes behind their activity.

Oral Presentation

THE HISTONE LYSINE METHYLTRANSFERASES AND THEIR TARGET METHYLATION MARKS EXHIBIT DYNAMIC EXPRESSION DURING OVARIAN AGING

YESİM BİLMEZ | SAFFET OZTURK

Department Of Histology And Embryology, Akdeniz University School Of Medicine, Antalya, Turkey
yesimbilmez95@gmail.com

Abstract

Introduction: Histone methylation, involving methylation of lysine or arginine residues of histones, is a key epigenetic mechanism that regulates gene expression during oocyte maturation and follicle development. The histone lysine methyltransferases, G9A and ASH1L, and key histone methylation marks, H3K4me3 and H3K36me3 are important for normal oogenesis and early embryo development, determining their expressional changes during ovarian aging would be important to understand the underlying reasons of fertility loss along with maternal aging.

Purpose: In this study, we aimed to determine spatiotemporal distributions of the G9A and ASH1L proteins and the methylation marks as well as global DNA methylation and transcriptional activity in postnatal mouse ovaries.

Materials-Methods: Three groups were created from Balb/C female mice ovaries, including pubertal (7-week-old, n=7), postpubertal (18-week-old, n=7), and aged (52-week-old, n=7). Immunohistochemical staining was performed for the G9A and ASH1L proteins, H3K4me3 and H3K36me3 marks as well as for pS2 (transcriptional activity marker) and 5mC (global methylation marker). Obtained data were analyzed with ImageJ program and then with one-way ANOVA for statistical significance ($P<0.05$).

Results: G9A showed both nuclear and cytoplasmic localization in oocytes and granulosa cells of growing follicles as well as in stromal cells of all groups. Its level increased in the postpubertal group compared to the pubertal group ($P<0.01$). Similarly, ASH1L was intensively expressed in oocytes and granulosa cells of growing follicles, but no differences were noted. H3K4me3 expression was detected highly in the nuclei of granulosa cells of follicles at different developmental stages as well as in the nuclei of stromal, luteal and theca cells. Its relative levels gradually decreased from puberty to aged groups, especially in the granulosa and theca cells of secondary, preantral, and antral follicles ($P<0.05$). The H3K36me3 expression was strongly expressed in the nuclei of granulosa and stromal cells, and its relative levels reduced in granulosa and theca cells of primary, secondary, and preantral follicles as well as in the granulosa and theca lutein cells in the aged group ($P<0.05$). While pS2 level in the secondary and preantral follicles, and granulosa lutein and theca lutein cells gradually decreased from puberty to aged groups ($P<0.05$), 5mC staining in granulosa cells of primary follicle and granulosa lutein cells decreased in the aged ovaries ($P<0.05$).

Conclusion: The alterations in histone lysine methyltransferases and their methylation marks may be associated with altering gene expression during ovarian aging, associated with fertility loss.

Keywords: follicles, ovarian aging, histone lysine methyltransferases, histone methylation, transcriptional activation, global DNA methylation

Acknowledgements: This study supported by the Scientific and Technological Research Council of Türkiye (TUBITAK; Grant No. 123S694).

Oral Presentation

COMBINING LEFLUNOMIDE AND SORAFENIB: A PROMISING STRATEGY AGAINST COLORECTAL CANCER

AYBİKE SARIOĞLU BOZKURT | ÖNER SÖNMEZ

Bursa Uludag University Faculty of Veterinary Medicine
aybikesarioglu0@gmail.com

Abstract

Introduction: Colorectal (CRC) cancers rank among the most lethal malignancies globally, characterized by high incidence and poor survival rates. Despite advances in treatment, resistance to current therapies remains a significant challenge, underscoring the need for novel therapeutic strategies. Leflunomide, an immunomodulatory drug, inhibits dihydroorotate dehydrogenase, thereby disrupting nucleotide synthesis and exhibiting potential anti-cancer effects. Sorafenib, a multi-kinase inhibitor, is utilized in treating advanced cancers by targeting key pathways involved in tumor growth and angiogenesis. While both drugs have shown promise individually in preclinical models, their combined efficacy in CRC cancers has yet to be fully explored.

Aim: This study aims to evaluate the combined anti-cancer effects of Leflunomide and Sorafenib in CRC cancer model, with the goal of determining whether this combination offers enhanced therapeutic benefits.

Material & Methods: HCT116 (CRC), cell lines were used to investigate the potential synergistic effects of Leflunomide and Sorafenib. The half-maximal inhibitory concentration (IC50) for each drug was determined via SRB assays. A matrix dose-response analysis was then conducted using Synergy Finder to assess the synergistic potential of the drug combination, with combination index (CI) values guiding further assays. Functional studies included TUNEL assays to measure apoptosis, CellTiter-Glo assays for time-dependent cell viability, and colony formation assays (CFA) to assess long-term clonogenic potential. All experiments were performed in triplicate to ensure reproducibility and statistical validity.

Results: The combination of Leflunomide and Sorafenib resulted in a significant reduction in cell viability and proliferation, with a marked increase in apoptosis in both CRC cancer cell line compared to monotherapy or control groups. Notably, the combination index (CI) was calculated to be 0.7, suggesting a synergistic interaction between Leflunomide and Sorafenib.

Conclusion: The combination of Leflunomide and Sorafenib demonstrated a synergistic effect in reducing cell viability and proliferation while significantly enhancing apoptosis in colorectal cancer cell line. These findings suggest that the combined use of these two drugs could offer a promising therapeutic strategy for improving outcomes in these challenging malignancies, warranting further investigation in preclinical and clinical settings.

Oral Presentation

PRECLINICAL FINDINGS HIGHLIGHT BRCC3 AS A POTENTIAL TARGET FOR PARKINSON'S DISEASE: EVIDENCE FROM ROTENONE-INDUCED EXPERIMENTAL RAT MODEL

ÇEVİK GÜREL[1] | GÖKÇE CEREN KUŞÇU[2] | AYLİN BUHUR[3] | EZGİ TUT[4] | LEİLA SABOUR-TAKANLOU[5] | CEM GÜLER[6] | EBRU ŞANCI[5] | EDA AÇIKGÖZ[7] | NEFİSE ÜLKÜ KARABAY YAVAŞOĞLU[5] | ÇIĞIR BİRAY AVCI[5] | FATİH OLTULU[2] | ALTUĞ YAVAŞOĞLU[2]

[1]Department Of Histology And Embryology, Faculty Of Medicine, Harran University, Şanlıurfa, Turkey | [2]Department Of Histology And Embryology, Faculty Of Medicine, Ege University, İzmir, Turkey |[3] Department Of Dentistry, Faculty Of Dentistry, Galata University, İstanbul,Turkey |[4] Department Of Nuclear Application, Institute Of Nuclear Sciences, Ege University, Izmir, Turkey | [5]Department Of Medical Biology, Faculty Of Medicine, Ege University, Izmir, Turkey | [6]Department Of Biology, Faluty Of Science, Ege University, Izmir, Turkey | [7]Department Of Histology And Embryology, Faculty Of Medicine, Van Yuzuncu Yil University, Van, Turkey | cevikgurel@gmail.com

Abstract

Introduction: Emerging evidence suggests that disruptions in the ubiquitin-proteasome system (UPS) and autophagy, which are essential for degrading misfolded or dysfunctional proteins, contribute to Parkinson's Disease (PD). Notably, lysine-63 (K63) polyubiquitination, which facilitates autophagic protein degradation within the UPS, might play a critical role in PD neuropathogenesis. Understanding the molecular mechanisms governing K63 poly-ubiquitination is therefore crucial for elucidating PD etiology and developing new treatments.

Objective: This study aimed to examine the effects of BRCC3, a K63-specific deubiquitinase, gene knockout on the autophagy pathway in a rotenone-induced sporadic in vivo PD model through histological, biochemical, and molecular analyses.

Material-Metod: Ninety-six adult male Sprague Dawley rats were utilized, divided into four groups of 24: Control, Parkinson, Parkinson+Niosome, and Parkinson+Niosome-siRNA. Parkinson's disease was induced in all groups except the Control group using 2 mg/kg intraperitoneal rotenone over 35 days. Control and Parkinson groups received three 0.2 ml doses of physiological saline at 48-hour intervals. The Parkinson+Niosome and Parkinson+Niosome-siRNA groups received empty niosomes and niosome-siRNA complexes in physiological saline at 48-hour intervals, respectively. Behavioral tests were conducted on days 0, 21, and 42. The efficacy of niosome-siRNA complexes in reaching the brain was assessed using an in vivo imaging system (IVIS). Histopathological changes were evaluated through hematoxylin and eosin and toluidine blue staining. Real-time quantitative PCR (RT-qPCR) and immunohistochemical analyses were performed to measure changes in autophagy-related molecule expression. Oxidative stress effects were quantified using malondialdehyde (MDA) and superoxide dismutase (SOD) enzyme-linked immunosorbent assays (ELISA).

Findings: IVIS analyses indicated that the niosome-siRNA complex reached the brain within 3 to 5 hours of injection and was detoxified within 24 hours. Behavioral tests showed that the niosome-siRNA group had a significant increase in distance traveled and a significant decrease in immobility and catalepsy scores compared to the Parkinson and

Parkinson+Niosome groups ($p<0.05$). Histopathological analysis revealed significantly decrease in Lewy body-like changes and degenerative neurons in the niosome-siRNA group compared to the Parkinson and Parkinson+Niosome groups ($p<0.05$). RT-qPCR and immunohistochemistry demonstrated that LC3II and Beclin-1 mRNA and protein levels were over four times higher in the niosome-siRNA group ($p<0.005$). Biochemical analyses showed that MDA levels were half and SOD activity was approximately twice as high in the niosome-siRNA group compared to the Parkinson group ($p<0.05$).

Conclusion: Preclinical findings suggest that BRCC 3 may be a promising therapeutic target for the PD management via autophagy and antioxidant system re-activation.

Keywords: Autophagy; BRCC3; Gene Knockout; Parkinson's Disease; siRNA

Oral Presentation

NICOTINAMIDE MONONUCLEOTIDE ALLEVIATES SEPSIS-INDUCED LIVER INJURY IN A RAT MODEL OF CECAL LIGATION AND PUNCTURE

ZELİHA YETİM[1], ERGİN TAŞKIN[2], ÖZLEM DEMİR[3]

1 University of Health Science, Histology and Embriology, İstanbul, Türkiye, zeliha.yetim@sbu.edu.tr

2 Ağrı İbrahim Çeçen University, Medical Biochemistry, Ağrı, Türkiye, etaskin@agri.edu.tr

3 Erzincan Binali Yıldırım University, Histology and Embriology, Erzincan, Türkiye, ozlem.abuc@erzincan.edu.tr

Abstract

Aim: Sepsis is an infection that triggers abnormal inflammatory and immune responses. Cytokines cause production of reactive oxygen species, apoptosis and cell dysfunction, leading to organ failure and death. In sepsis, toxins of pathogens or inflammatory molecules can cause liver damage. Nicotinamide mono nucleotide (NMN) is a precursor of nicotinamide adenine dinucleotide (NAD+). Administration of NMN decreases intracellular NAD+ levels, and protects organs against oxidative stress and many diseases. In this study, it was investigated whether NMN prevented oxidative stress and liver injury in sepsis.

Material and method: 21 female rats of the Sprague Dawley were used. The rats were randomly divided into 3 groups. The control group consisted of healthy rats. The sepsis model was established with cecal ligation perforation (CLP) to the CLP group. The CLP+NMN group were given NMN at a dose of 500 mg/kg intraperitoneally 30 minutes before and 12 hours after sepsis was established. At the end of the experiment, ovaries and blood samples were taken, later histological and biochemical evaluations were performed.

Results: The control group had healthy ovarian tissue appearance. In the CLP group, liver tissues exhibited marked edema, degeneration, disorder of arrangement. Increased number of inflammatory cells were available. Liver injury symptoms become much more obvious. In CLP+NMN group, histological alterations were ameliorated. Edema, degeneration and inflammatory cells were decreased. The biochemical parameters were indicated that CRP levels increased significantly in the CLP group and decreased in CLP+NMN group.

Conclusion: The results showed that NMN reduced cellular damage in liver tissue when given before and after sepsis. These findings support that NMN can be used as a protective and therapeutic agent in the treatment of liver damage in sepsis.

Key Words: Oxidative stress, Nicotinamide Mono Nucleotide, liver, rat, sepsis.

Oral Presentation

VITEX AGNUS-CASTUS L. OIL MODULATES TLR EXPRESSION IN SK-UT-1 CELL LINE: A PROMISING THERAPEUTIC AVENUE FOR UTERINE LEIOMYOSARCOMA

SEMİH TAN[1] | SEÇİL TAN[2] | CEMRE ZEYNEP HARMAN[1]

[1]Ordu University, School Of Medicine, Department Of Histology And Embryology | [2]Pamukkale University, Institute Of Medical Sciences, Department Of Cancer Molecular Biology | czharman@hotmail.com

Abstract

Introduction: Human uterine leiomyosarcoma (uLMS) is a challenging malignancy with complex diagnostic and therapeutic aspects. SK-UT-1 cell line is a key research model used to study the molecular mechanisms of uLMS and test new treatment strategies. Toll-like receptors (TLRs) are crucial in the immune system's response to pathogens, triggering inflammation. Phytochemicals like those in Vitex agnus-castus (VAC) have been shown to regulate TLRs. VAC's essential oils and phenolic compounds possess antioxidant properties, which may influence inflammatory pathways and modulate oxidative stress, potentially affecting TLR signaling in cancer and immune responses.
Objective: The aim of this study is to contribute to the elucidation of the therapeutic effects of Vitex agnus-castus in uterine leiomyosarcoma by demonstrating its link with the regulation of TLRs and by affecting TLR-mediated pathways of its phytochemical components.
Material-Method: The main stock was prepared by dissolving 950 µl of commercially available VAC oil with 20 µl of Tween 20 and adding 1000 µl of DMEM (48.22% VAC, 1% Tween20). The main stock was diluted 100X and working doses were determined. SK-UT-1 cells were incubated for 24 hours by taking 1, 5, 10, 25, 50, 100% of the working stock. In addition, the effect of the solvent was observed by applying the same ratios of solvent. The IC50 dose of VAC oil on SK-UT-1 cells was determined by XTT assay. The effective dose was given to the cells and incubated for 24 hours. Then, total RNA was isolated from the cells. TLRs (1-10) and Myd expression were analyzed by qRT-PCR. Statistical analysis of the data was performed using the GraphPad Prism program and $p \leq 0.05$ was accepted as the statistical significance level.
Results And Conclusion: The IC50 value was found to be 0.01959% in SK-UT-1 cells incubated with VAC oil for 24 hours. No cytotoxic effect was observed at doses ≤ 0.01% Tween20. TLR 1-10 and Myd expressions were evaluated by qRT-PCR analysis. It was observed that TLR2 and TLR4 decreased at a statistically significant level. The downregulation of TLR2 and TLR4 in cancer cells is a critical factor influencing tumor behavior and immune evasion. The differential expression of these receptors can affect cancer progression, immune responses, and treatment efficacy. Further research is necessary to elucidate the precise mechanisms underlying TLR regulation in uLMS and to explore potential therapeutic strategies that leverage TLR signaling to improve cancer treatment outcomes.

Oral Presentation

ALDEHYDE DEHYDROGENASE INHIBITOR 673A INDUCES ER STRESS-MEDIATED APOPTOSIS IN OVARIAN CANCER STEM CELLS

TUNA ONAL[1] | MELİKE OZGUL-ONAL[2] | ANİL YADAV[3] | SUROJEET SENGUPTA[3] | ILANA CHEFETZ[3] | ROBERT CLARKE[3]

[1]Bandirma Onyedi Eylul University, Department Of Histology And Embryology, Bandirma-Balikesir, Türkiye, University Of Minnesota, The Hormel Institute, Cancer Systems Biology Laboratory, Austin, Mn, Usa
[2]Mugla Sitki Kocman University, Department Of Histology And Embryology, Mugla, Türkiye, University Of Minnesota, The Hormel Institute, Cancer Systems Biology Laboratory, Austin, Mn, Usa
[3]University Of Minnesota, The Hormel Institute, Cancer Systems Biology Laboratory, Austin, Mn, Usa
tonal@bandirma.edu.tr

Abstract

Introduction: Ovarian cancer (OC) is one of the most lethal gynaecological cancers. Despite advances in chemotherapy and surgical techniques for the treatment of ovarian cancer, the survival of OC patients is 5 years. It is important to develop new therapeutic approaches to improve the prognosis of OC patients. Cancer stem cells (CSCs) are a subpopulation of tumor cells that contribute to tumor growth, metastasis and chemoresistance. Ovarian cancer stem cells (OCSCs) are characterized by high aldehyde dehydrogenase (ALDH) enzyme activity and CD133 expression. 673A is a promising agent in ovarian cancer treatment because it is an ALDH1A inhibitor and induces necroptotic cell death in CD133+ OCSCs. Endoplasmic reticulum (ER) stress is activated when proteostasis is disrupted and misfolded and unfolded proteins accumulate in the ER. The ER stress activates all the protein response (UPR) pathways. When ER stress is prolonged, stressed cells undergo apoptosis. The relationship between ER stress, apoptosis and 673A in OCSCs remains to be elucidated.

Aim: In this study, we investigated the activated novel cell death mechanisms and signaling pathways after treatment of 673A in ovarian cancer stem cells.

Materials and Methods: CD133+ cells isolated from type I ovarian cancer A2780 cells and high-grade serous cancer PEO4 cells using fluorescence-activated cell sorting (FACS) and used for all experiments. Cells were treated with 673A in different concentrations at different time points. Cell viability and proliferation were determined using Incucyte®. Colony formation assay and spheroid assay were performed. Reactive oxygen species (ROS) levels measured using CellROX with Incucyte®. Apoptosis was determined using Annexin V/PI. In addition, the expressions of ALDH, CD133, ER stress, and several apoptotic proteins were determined by Western blot analysis.

Results: ALDH inhibitor 673A inhibited the growth of OCSCs, colony formation and the development of spheroids in a dose-dependent manner. ROS levels were elevated in OCSCs after 673A treatment. Apoptosis showed by Annexin V/PI staining after 673A treatment. The treatment with 673A decreased ALDH and CD133 protein expression in OCSCs. Markers of ER stress (eIF2α, ATF4 and CHOP) and apoptosis (Caspase-8, Caspase-9, Caspase-3, and c-PARP) increased after 673A treatment in a time-dependent manner.

Conclusion: This study demonstrated for the first time that 673A treatment induces ER stress-mediated apoptosis in ovarian cancer stem cells and will provide a basis for investigating the effects of 673A in other cancer stem cells.

Key words:Ovarian Cancer, Cancer Stem Cell, ALDH, CD133, ER stress, Apoptosis

Oral Presentation

BUPARLISIB ENHANCES THE ANTICANCER ACTIVITY OF RADIOTHERAPY IN METASTATIC CASTRATION RESISTANT PROSTATE CANCER

KAAN FURKAN HAMARAT[1] | YUSUF YILMAZ[1] | GÜLSÜM REYHAN ÖZAKKAŞ[2] | HATİCE HALİS[3] | GAMZE GÜNEY ESKİLER[4]

[1]Faculty Of Medicine, Sakarya University, Sakarya, Türkiye | [2]Department Of Medical Biology, Institute Of Health Sciences, Sakarya University, Sakarya, Türkiye | [3]Department Of Radiation Oncology, Sakarya Training And Research Hospital, Sakarya, Türkiye | [4]Department Of Medical Biology, Faculty Of Medicine, Sakarya University, Sakarya, Türkiye
kaan.hamarat@ogr.sakarya.edu.tr

Abstract

Introduction: Metastatic castration-resistant prostate cancer (mCRPC) remains a leading cause of cancer-related mortality worldwide. Despite advances in therapeutic strategies, including androgen deprivation therapy, chemotherapy, and novel hormonal agents, the prognosis of mCRPC patients remains poor due to intrinsic and acquired resistance mechanisms. The aberrant activation of the PI3K/Akt/mTOR signaling pathway results in uncontrolled cell proliferation and resistance to therapy. Inhibition of this pathway, particularly in combination with radiotherapy (RT), could potentially enhance anticancer efficacy by overcoming resistance and sensitizing cancer cells to treatment.

Aim: In this study, we, for the first time, investigated the combined anticancer effects of a PI3K inhibitor, Buparlisib and RT on the PC-3 mCRPC cell line.

Material-Method: PC-3 cells were first pre-treated with different Buparlisib concentrations (1-10 µM) and then exposed to ionizing radiation (2-6 Gy). After the incubation, we conducted WST-1, Annexin V, Acridine orange/Propidium iodide and RT-PCR analysis.
Results: According to the WST-1 analysis, the Buparlisib and RT combination exerted synergistic anticancer activity in PC-3 cells and induced apoptosis with nuclear damage and many vacuoles. The cell viability reduced to 44.5% after 6 Gy RT and Buparlisib treatment compared with 1µM Buparlisib (61.5%) or RT alone (70.5%). Additionally, the mRNA levels of Akt (0.3-fold) and mTOR (0.5-fold) significantly down-regulated following combination treatment ($p<0.01$).

Conclusion: In summary, inhibiting the PI3K/Akt/mTOR signaling pathway in combination with RT could be a new therapeutic treatment strategy in mCRPC cells. However, there is a need for further analysis to assess the underlying molecular mechanisms of combination treatment efficacy in mCRPC cells.

Key Words: mCRPC, Buparlisib, Radiotherapy, Combination treatment.

Oral Presentation

INTRAHIPPOCAMPAL AND INTRANASAL APPLICATION OF HUMAN UMBILICAL CORD MESENCHYMAL STEM CELL DERIVED EXOSOMES IN THE EXPERIMENTAL RAT ALZHEIMER MODEL

GÖKÇEN GÖKÇE

Ksbü Tıp Fakültesi Histoloji-Embriyoloji Ad
gokcen.gokce@ksbu.edu.tr

Abstract

Introduction: Alzheimer's Disease (AD) is a neurodegenerative disease that occurs as a result of the deterioration of neurons and the synaptic structure between neurons through genetic and environmental factors and is the most common cause of dementia. The exosome application method in AD has begun to be used in recent years to investigate the pathogenesis and treatment of the disease, and its use has increased day by day. In our study, we aimed to obtain exosomes and administer them intrahippocampus (IH) and intranasal (IN) in order to put exosomes obtained from umbilical cord mesenchymal stem cells (WJ-MSCs) into clinical use for therapeutic purposes. The results achieved within the framework of this goal were also confirmed by histochemical staining, immunohistochemical staining, confocal and electron microscopic examination. In our study, ICV and IN exosomes were administered to experimental Alzheimer's model rats and it was shown that exosomes could reach the brain tissue in the application method.

Method: In this study, Wistar albino rats were used. The ethics committee approval report of Ankara University Experimental Animals Local Ethics Committee with decision number 2022-5-56 and dated March 2, 2022 has been put into use. Six groups were formed. The Alzheimer model was created by IH injection of Aβ 1-42 (Facchinetti et al., 2018). In our study, for the purpose of obtaining exosomes, WJ-MSC were obtained and stored after ethical approval, and MSCs obtained from tissue samples taken from cases applying to Kocaeli University Faculty of Medicine with ethical decision number IAEK 4/19 were used. The MSCs we used in our study were previously characterized and analyzed using flow cytometry. The ultracentrifuge protocol was modified and used to obtain exosomes (Lässer et al., 2012). Exosome (200µg /100µL) and PBS (200µg /100 µL) were injected intrahippocampus and intranasal in determined groups for ten days and all experimental groups were sacrificed ten days later.

Results: When we generally evaluated all histochemical and immunohistochemical perspective, it was observed that exosome application reduced the Aβ and tau staining positivity values, which increased with Aβ application.

Conclusion: In addition to stem cell therapy in AD treatment, it has been observed that intracerebroventricular exosome therapy can be used as an additional treatment for gaining healthy brain morphology.

Keywords: Mesenchymal Stem Cells, Exosome, PKH, Alzheimer, Rat

Oral Presentation

INVESTIGATION OF THE EFFECT OF ELECTROMAGNETIC FIELD EXPOSURE ON CATSPER GENE EXPRESSION LEVELS

ADEM KOCAMAN | BÜLENT AYAS

Ondokuz Mayıs University, Faculty Of Medicine, Histology And Embryology Department Samsun
adem.kocaman@omu.edu.tr

Abstract

Introduction: Electromagnetic field (EMF) exposure is known to trigger therapeutic and pathophysiological processes at the cellular level in living organisms. A limited number of studies conducted in recent years have revealed the effects of EMF on male infertility. It is thought that EMF may have an effect on sperm motility by activating calcium channels. The increase in sperm intracellular calcium through the CatSper channel results in capacitation, hyperactivation of motility and triggering of the acrosome reaction. Despite its crucial role in male fertility, little is known about the effect of EMF on CatSper gene expression and sperm motility. In this study, we aimed to investigate the possible effects of EMF on Casper gene expression.

Material and Method: Fifty adult (60 days) Wistar albino male rats weighing 180-200 g were included in the study. In the EMF group, EMF at 2100 MHz level was applied for 1 hour daily at the same time every day for 28 days. In the positive control group, amlodipine, a calcium channel blocker (CCB), was administered 1 mg/kg/day by gavage for 28 days. Control, Sham, EMF, EMF+CCB, EMF+CCB, CCB groups were formed with 10 subjects in each group. Total RNA isolation and cDNA synthesis were performed from sperm samples and Catsper1 and Catsper2 gene expression levels were analyzed.

Results: A comparison of gene expression rates between the groups revealed a 3.4-fold increase in Catsper1 gene and an 8-fold increase in Catsper2 gene in the EMF group compared to the control group. In addition, the expression levels of Catsper gene, a calcium channel protein, increased in the EMF+CCB and CCB groups compared to the control group.
Discussion: EMF may act on sperm intracellular calcium levels through calcium channel proteins. Changes in intracellular calcium levels may have implications on sperm motility. The increase in Catsper gene expression levels may have occurred to compensate for possible functional impairments caused by EMF exposure. Similarly, the proportional increase in Catsper gene expression levels was also observed in the CCB group. Catsper proteins with reduced functionality as a result of CCB administration may cause disruption of intracellular balance. This suggests that the increase in gene expression levels may have occurred in order to synthesize more protein subunits with reduced functionality.
Conclusion: The potential adverse effects of EMF exposure caused by devices emerging with the development of technology on living systems have been discussed for a long time. With this study, it is important to consider possible protection and avoidance methods against other possible effects of EMF exposure at the cellular level.

Keywords: CatSper, electromagnetic field, sperm, infertility
*This project is supported by Tubitak 1002 program.

Oral Presentation

INVESTIGATION OF THE ROLE OF P97/VCP IN AUTOPHAGIC DEGRADATION OF ANDROGEN-BINDING PROTEIN IN SERTOLI CELLS

ILKAY CORUMLUOGLU | SEVİL CAYLI

Department Of Histology And Embryology, Faculty Of Medicine, Ankara Yildirim Beyazit University
ilkaypiskin@aybu.edu.tr

Abstract

Background: Androgen-binding protein (ABP) is a protein produced by Sertoli cells that directly influences sperm production by ensuring androgen binding in the testicular tubules. Irregularities in the production, degradation, and release of ABP are associated with a number of endocrine and andrological disorders of the male reproductive system. ABP metabolism in Sertoli cells is largely unknown. Recent studies have shown that autophagy in rat Sertoli cells is regulated by testosterone, which prolongs the biological half-life of ABP. p97/Valosin-containing protein (VCP) is a chaperone protein that belongs to the ATPase family and plays a role in a variety of cellular processes, including regulation of the cell cycle, ER-associated degradation (ERAD), autophagy, apoptosis, and the ubiquitin-proteasome system (UPS). Regarding its role in autophagy, its absence impairs both the formation and maturation of autophagosomes, resulting in impaired autophagy. However, the relationship of p97/VCP with the autophagic degradation of ABP is unknown.

Aim: Our study aims to determine whether p97/VCP has a relationship with ABP in the mouse Sertoli cell line. Our hypothesis is that p97/VCP is involved in the autophagic degradation of ABP in mouse Sertoli cells.

Material and methods: Expression of ABP and p97/VCP in the mouse Sertoli cell line (15P-1) in the presence of autophagy activator, inhibitor, and testosterone was determined by immunocytochemistry and western blot methods. The co-localization of ABP and p97/VCP was investigated by a double immunofluorescence method. The p97/VCP gene expression was suppressed by p97/VCP siRNAs, and siRNA transfection methods were used to determine whether ABP was affected by this suppression.

Results: A decrease in VCP, ABP, LC3B, and p62 proteins was observed in the groups suppressed with VCPsi and receiving QC+T ($p<0.05$). This revealed for the first time in the literature the association between ABP and p97/VCP, which is related to male reproductive health and directly affects sperm production, and provided the first information on the importance of p97/VCP in ABP-related endocrine and andrologic diseases.
Conclusion: Finally, it will form the basis for studies in various tissues such as the brain, liver, and placenta, where ABP is expressed outside the testis and p97/VCP expressions will be linked to ABP-dependent pathologies in these tissues.

Keywords: ABP, Autophagy, Testosterone, p97/VCP, Sertoli cell line 15P-1

Oral Presentation

INDOXIMOD AND MELATONIN REGRESSED TUMOR PROGRESSION AND METASTASIS SYNERGISTICALLY RESTRICTING IMMUNOSUPPRESSIVE TUMOR MICROENVIRONMENT

ECE OYLUMLU[1] | SENDEGUL YİLDİRİM[1] | ALEYNA SİSANCİ[1] | EMİNE YAZİCİ[1] | MERZUKA KALAY[1] | SAYRA DİLMAC[2] | GAMZE GUNEY ESKİLER[3] | GAMZE TANRİOVER[1]

[1]Akdeniz University,Faculty Of Medicine, Department Of Histology And Embryology, Antalya, |[2] Houston Methodist Research Institute, Department Of Nanomedicine, Houston, Usa | [3]Sakarya University , Faculty Of Medicine, Department Of Medical Biology, Sakarya | eceoylumlu2@gmail.com

Abstract

Introduction and Aim: Breast cancer is the second most common cancer among women. IDO (Indoleamine 2-3 dioxygenase) is an enzyme highly expressed in neoplastic cells and leukocytes. Enhanced IDO activation in different cancer cells causes T cells to lose their proper function. Nowadays, IDO inhibition has received much attention in the field of cancer immunotherapy. Indoximod, an IDO inhibitor involved in the regulation of immune responses. Melatonin is an indolamine that plays a crucial role in the regulation of the central circadian rhythm. Furthermore, the effects of Melatonin on tumor progression has known. In this study, we hypothesized that Indoximod and Melatonin restricts tumor growth and metastasis by suppressing MDSCs (myeloid-derived suppressor cells). Herein, we aimed to interpret the possible synergistic effects of IDO inhibition and Melatonin on tumor progression and changes in immune responses.

Material and Methods: In vitro and in vivo experiments were conducted using 4T1 cells. 4T1 cells were supplemented with TNF-α for mimicking tumor microenvironment and Annexin V staining was performed to investigate apoptosis. For in vivo experiments, 1x106 cells were orthotopically injected into the mammary tissues of Balb/C mice. Injected animals were divided into six groups regarding Control, 4T1, 4T1+EtOH, 4T1+M(Melatonin), 4T1+I(Indoximod) and 4T1+M+I(Melatonin+Indoximod. 7 days post injection, ethanol and Melatonin were administered intraperitoneally twice daily. Indoximod was administered intraperitoneally twice in a week. Tumor growth was measured twice a week. And of the 4th week, peripheral blood smear analysis was performed to evaluate the immune responses. Moreover, primary tumor and metastatic tissues were excised and analyzed. MDSC markers were evaluated in primary tumors and metastatic organs by IHC staining. ELISA assay was performed to reveal the pro and anti-inflammatory cytokines from the spleens' lysates.

Results: Indoximod and melatonin significantly reduced 4T1 cell viability by inducing apoptosis. Both Individual and combined administration of Indoximod and Melatonin reduced tumor growth. We observed least metastasis in liver and lung tissues of group 4T1+M+I. Furthermore, tumor cell induced-inflammatory responses were dampened in groups 4T1+M, 4T1+I and 4T1+M+I. Strikingly, individual and combined administration of Indoximod and Melatonin reduced MDSCs markers in primary tumors and metastatic organs.
Conclusion: Indoximod and Melatonin synergistically induced apoptosis thereby restricting tumor growth and metastasis through inhibition of MDSCs.
Keywords: Breast cancer, Metastasis, Indoximod, Melatonin, MDSCs
This study has been funded by TUSEB Group A Emergency R&D Project (Project no:28251).

Oral Presentation

EXPLORING THE THERAPEUTIC POTENTIAL OF MATCHA TEA IN NEUROBLASTOMA: IMPACT ON GAP43 AND MAP2 EXPRESSION

HATİCE HANCI[1] | SEMİH TAN[1] | SEÇİL TAN[2] | CEMRE ZEYNEP HARMAN[1]

[1]Ordu University, School Of Medicine, Department Of Histology And Embryology | [2]Pamukkale University, Instution Of Medicine, Department Of Cancer Molecular Biology | czharman@hotmail.com

Abstract

Introductıon: Matcha tea, a finely ground powder from specially cultivated green tea leaves (Camellia sinensis), has garnered interest for its health benefits, particularly in cancer therapy. Its unique cultivation enhances bioactive compounds like catechins, known for strong antioxidant effects, with epigallocatechin gallate (EGCG) being the most studied for its anti-cancer properties. GAP43 (Growth-Associated Protein 43) and MAP2 (Microtubule-Associated Protein 2) are key proteins in neural cell development. GAP43 is expressed in the growth cones of developing neurons and is critical for neuronal pathfinding. MAP2, found mainly in cell bodies and dendrites, supports microtubule assembly and neurogenesis. In neuroblastoma, their interaction sheds light on tumor differentiation and potential therapies. Additionally, GAP43 and MAP2 serve as prognostic markers, offering insights into patient outcomes and treatment responses.

Objective: This study aimed to evaluate the potential of Matcha tea in neuroblastoma treatment due to its high antioxidant content, potential anti-inflammatory properties, and ability to enhance conventional therapies.

Material-Method: SH-SY5Y neuroblastoma cells were used as a model for neurodegenerative diseases. The Matcha tea dose was selected based on existing literature. A solution of 1 g Matcha tea in 10 ml distilled water was stirred at 70°C for 1 hour, then sterilized using a 0.22 µm filter. A 50 µl aliquot of this solution was mixed with 450 µl DMEM and applied to cells at 70% confluency in 12-well plates, followed by 24 hours of incubation. After incubation, cells were fixed with methanol and stained with GAP43 and MAP2 primary antibodies using immunocytochemistry (ICC). Photographs were taken at 40x magnification using an inverted microscope, and ICC results were analyzed with ImageJ software.

Results And Conclusion: ICC analysis revealed a significant reduction in GAP43 and MAP2 expression. The interplay between GAP43 and MAP2 is crucial in neural cancers. In glioma, GAP43 expression is modulated by factors like NNMT, which inhibits GAP43 while promoting tumor proliferation, suggesting a complex regulatory network. Additionally, MAP2 expression in neural cancer stem cells indicates that these cells may retain characteristics of neural progenitors, contributing to tumor heterogeneity and resistance to treatment. GAP43 is associated with tumor progression and invasiveness, while MAP2 is a marker for neuronal differentiation and stability. Understanding the interactions between these proteins provides insights into tumorigenesis and highlights potential therapeutic targets.

Oral Presentation

SHORT-TERM AND LONG-TERM THERAPEUTIC EFFECTS OF ELABELA ON TORSION-INDUCED TESTIS DAMAGE IN RATS VIA THE ALLEVIATION OF OXIDATIVE STRESS

YASEMİN CESUR | ALPEREN AKBABA | LEYLA SEMİHA ŞEN | AHMET ÖTER | YILMAZ ÇİRKİN | FATİH ERBALCI | KÜRŞAT UYĞUL | KUTAY KÖROĞLU | MERAL YÜKSEL | BERRAK YEĞEN | FERİHA ERCAN

Marmara University School Of Medicine, oterahmet38@gmail.com

Abstract

Introduction: Testicular torsion is a well-defined acute urological problem occuring in children and young adolescents due to compression and subsequent reperfusion of the spermatic cord. Rotation of the spermatic cord with testicular torsion impairs arterial nutrition and venous drainage, causes release of reactive oxygen species along with decrease in antioxidants, leading to deterioration of testis morphology and spermatogenesis. Elabela (ELA), a member of the apelinergic system, has been shown to provide antioxidative and anti-inflammatory effects against several ischemia/reperfusion (I/R)-induced damage models.
Objective: The aim of this study was to investigate the possible protective effects of ELA on torsion-induced testis damage and impaired sperm parameters.
Materials and Methods: The tunica vaginalis of the left testicles of male Sprague-Dawley rats was opened under ketamine-xylazine anesthesia. The left testicle was rotated 720o clockwise and torsion was performed, kept for 2 hours, and then detorsion was performed. Before the rats were euthanized at 2-h following detorsion, ELA (40 µg/kg) or saline was administered intraperitoneally during and after torsion (n=16, short-term group), while other rats were further treated twice a day in the following 2 days after detorsion (n=16, long-term group) until they were euthanized at 72 h. Saline was applied to sham-operated control groups. Testicular blood flow was measured with a laser Doppler flow meter before the experiment, during torsion and before euthanasia. Epididymal sperm parameters and testicular morphology were evaluated. Lipid peroxidation (LP), glutathione, myeloperoxidase (MPO) activity, luminol, lucigenin and nitric oxide (NO) levels were measured in testicular homogenates. Data were evaluated statistically using one-way ANOVA and significance was accepted at the level of $p<0.05$.
Results: Testicular blood flow was increased and MPO, luminol, lucigenin and NO levels in testis samples were decreased by ELA treatment in both short- and long-term I/R groups, when compared to saline-treated I/R groups ($p<0.05$). LP and glutathione levels in testes were not significant among experimental groups. Testicular damage was ameliorated and sperm concentration, sperm motility and the percentage of spermatozoa with normal morphology were increased in both short- and long-term ELA-treated groups, while sperm parameters were better improved in long-term ELA-treated group.
Conclusion: According to the findings of this study, elabela treatment improved torsion-induced oxidative testicular damage and impaired sperm parameters by regulating testicular blood flow and inhibiting the formation of oxidative stress.

Key words: Testicular torsion, elabela, oxidative stress, spermatogenesis, spermatozoa

Oral Presentation

EVALUATION OF TAP73 PATHWAY IN TEMOZOLOMIDE RESISTANT CELL LINE IN VIEW OF CELL PROLIFERATION AND APOPTOTIC PATHWAYS

ALEYNA SISANECI | EMİNE YAZICI | MERZUKA KALAY | ECE OYLUMLU | SENDEGUL YILDIRIM | GAMZE TANRIOVER

Akdeniz University, Faculty Of Medicine, Department Of Histology And Embriyology, Antalya
a.sisaneci@gmail.com

Abstract

Introduction: Glioblastoma multiforme (GBM) is classified as a high-grade malignant glioma and is among the most invasive and highly proliferative cancer types. The primary treatment modality for patients with GBM is radiotherapy in combination with temozolomide (TMZ). However, patients eventually develop resistance to this treatment. CDK4/6 is one of the cyclin-dependent kinases (CDKs) involved in the cell cycle. A CDK4/6 inhibitor, Ribociclib, was approved by the Food and Drug Administration (FDA) in 2018 and is recommended for use in combination with aromatase inhibitors as a first-line treatment for hormone receptor-positive (HR+) human epidermal growth factor receptor-negative (HER2-) metastatic breast cancer patients.

Aim: We aimed to evaluate the effect of Ribociclib, in combination with TMZ and radiotherapy in terms of cell survival and to evaluate the effect of Ribociclib in terms of cell migration and colony forming ability. In addition, it was aimed to analyze the individual and combined application in terms of TAp73 pathway and molecular pathways and to determine the potential therapeutic effect.

Materials and Methods: The possible effects of Ribociclib and radiotherapy on GBM cells in T98G, TMZ resistant cell line were evaluated by MTT assay in terms of cell survival, while the effect of Ribociclib in terms of movement potential was evaluated by migration and clonogenic assays. In addition, the effects of chemotherapeutics on cell morphology were evaluated. In addition, protein analyses were performed by Western Blot and Immunocytochemistry to evaluate the cells in terms of pathway proteins.

Results: Both individual and combined administration of Ribociclib with TMZ significantly decreased cell survival. In addition, it was determined that the combination of Ribociclib with radiotherapy was more significant in radiotherapy groups compared to all groups. In addition, both individual and combined application of Ribociclib inhibited the migration and colony formation abilities of cells. In addition, Ribociclib decreased the expression of TAp73, p21, p-Rb, CDK4/6, STAT3, p-STAT3, BCL2 and cyclin D, while increasing the expression of cleaved Caspase-3 and p53.

Conclusion: Ribociclib decreased cell survival by inhibiting TMZ resistance in T98G cells and induced cells to apoptosis by suppressing TAp73.

Key words: glioblastoma multiforme, temozolomide, cyclin-dependent kinase inhibitor
This study has been funded by TUBITAK-1002 B Emercengy R&D Project (123Z802)

Oral Presentation

EVALUATION OF THE EFFECT OF DONAFENIB AND RADIOTHERAPY FOR THE SURVIVAL POTENTIAL OF TEMOZOLOMIDE-SENSITIVE AND RESISTANT GBM CELLS

EMİNE YAZICI | ALEYNA ŞIŞANECİ | MERZUKA KALAY | ECE OYLUMLU | SENDEGÜL YILDIRIM | GAMZE TANRIÖVER

Akdeniz University, Faculty Of Medicine, Department Of Histology And Embryology
emineyazici2525@hotmail.com

Abstract

Introduction: GBM (Glioblastoma multiforme) is the most common, aggressive malignant tumor of the central nervous system. Temozolomide (TMZ) is an chemotherapeutic agent widely used for clinical treatment of GBM patients. Donafenib (DNF) is a small molecule multikinase inhibitor, including VEGFR, PDGFR, and Raf kinases.

Aim: Our study was based on the hypothesis that DNF could use the Raf/MEK/ERK signaling pathway. The aim of our project is to combine DNF with Radiotherapy and TMZ treatment; is to evaluate the survival of GBM cells in vitro by interpreting its effect on this pathway.

Materials and Methods: The GBM cell lines used in our study were TMZ-sensitive U87MG and TMZ-resistant T98G cell lines. Our experimental groups consisted of Control (C), Vehicle (V), TMZ, DNF, TMZ+DNF, TMZ+DNF+RT and RT, TMZ+RT to mimic the clinical administration and DNF+RT. In GBM cells, dose scans were performed with MTT to determine the IC50 value of DNF and TMZ. According to this value, DNF was applied to cells in combination with both TMZ and radiotherapy. For radiotherapy application, the cells were irradiated with a total of 10Gy for 5 days, 2Gy daily. In the same groups, they were analysed with both migration and clonogenic testing to interpreted the movement potentials of the cells.

Results: The IC50 value of DNF in GBM cells was determined for the first time. DNF has been shown to reduce tumor cell proliferation with both TMZ and radiotherapy administration. As a result of the scarring in the cells, it was seen that there was a slowdown in tumor cell migration. In addition, the colony forming potential of GBM cells was reduced with TMZ and DNF administration.

Conclusion: Our study showed that DNF and TMZ reduce survival, migration and colony forming of tumor cells. For this reason, we believe that the findings we have obtained will lead to new studies and will make a significant contribution to the literature.

Keywords: Glioblastoma Multiforme, Donafenib, Temozolomide, Radiotherapy, Donafenib

This study has been funded by TUBITAK 1002-B Emergency R&D (Project no: 122Z788)

Oral Presentation

INVESTIGATION OF THE EFFECT OF HYPOXIA ON VEGF AND KISSPEPTIN PROTEIN LEVELS IN INVASIVE BLADDER CANCER CELLS

SİMGE ÇELEBİ AYLAN[1] | TUBA ÖZDEMİR SANCI[2] | GİZEM İLTER AKTAŞ[3]

[1]Ufuk University Faculty of Medicine Department of Histology-Embryology | [2]Ankara Yıldırım Beyazıt University Faculty of Medicine Department of Histology-Embryology | [3]Yüksek İhtisas University Faculty of Medicine Department of Histology-Embryology

simgecel@gmail.com

Abstract

Introduction: Bladder cancer is the most common type of cancer in the urinary system, ranking 6th in men and 10th in both sexes. It is classified as invasive and non-invasive based on its spread within the bladder wall. Invasive bladder cancer is an aggressive type that penetrates the muscle layer of the bladder wall, spreading to deeper tissues. In this type of cancer, tumor size and irregularities in vascular structure lead to a severe and widespread hypoxic microenvironment. Hypoxia contributes to poor prognosis by increasing the metastasis and angiogenesis potential of cancer cells. Bladder tumor hypoxia is associated with malignant progression, genetic instability, epithelial-to-mesenchymal transition, and reduced apoptotic potential. Under hypoxic conditions, it is known that Hypoxia-inducible factor 1-alpha (HIF-1α) is synthesized, angiogenesis is promoted, metabolic changes required for the transition to anaerobic glycolysis occur, and apoptosis is suppressed. However, it is not fully understood how these changes occur in invasive bladder cancer cells or how the levels of the kisspeptin protein, whose function under hypoxic conditions is not yet fully elucidated, change.

Objective: The aim of this study is to examine the levels of HIF-1α, Vascular endothelial growth factor (VEGF), and kisspeptin proteins under hypoxic and normoxic conditions in an invasive bladder cancer cell line.

Methods: The HTB-9 invasive bladder cancer cell line was cultured under hypoxic conditions with different concentrations (100, 150, and 200 µM) of cobalt chloride ($CoCl_2$) for 24 hours. Cell viability was assessed using PI analysis with flow cytometry. HIF-1α, VEGF, and kisspeptin protein levels in HTB9 cells cultured under hypoxic and normoxic conditions were determined by immunohistochemical analyses.

Results: PI viability analysis by flow cytometry of HTB9 cells cultured under hypoxic conditions with different concentrations (100, 150, and 200 µM) of $CoCl_2$ for 24 hours showed a significant decrease in cell viability, particularly at a hypoxic concentration of 200 µM $CoCl_2$ ($p<0.05$). In HTB9 cells cultured under hypoxic conditions, a significant increase was observed in HIF-1α and VEGF protein expression levels compared to normoxic conditions ($p<0.05$). This increase became more pronounced with rising hypoxia-inducing concentrations. Furthermore, a significant elevation in kisspeptin protein levels was also detected under hypoxic conditions ($p<0.05$). These results suggest that HIF-1α may exert its effects through a pathway involving VEGF and kisspeptin under hypoxia.

Conclusion: It was observed that hypoxia increases VEGF and kisspeptin protein expression levels in invasive bladder cancer cells. These findings highlight the potential role of the

hypoxic microenvironment in bladder cancer progression and the need for developing new therapeutic strategies targeting this pathway.

Oral Presentation

EXPRESSION OF AQUAPORIN 8 AND 5 MOLECULES IN CHONDROCYTES OF ARTICULAR CARTILAGE IN RATS WITH TYPE-2 DIABETES MELLITUS

FİKRET GEVREK* | *MERVE PARLAK* | *ASİYE YANCI

Department Of Histology And Embryology, Faculty Of Medicine, Tokat Gaziosmanpaşa University, Tokat, Turkiye, fikret.gevrek@gmail.com

Abstract

Introduction: Diabetes Mellitus (DM) is an incurable condition marked by abnormal blood sugar levels due to insulin deficiency. DM heightens the risk of knee and hip osteoarthritis (OA), as articular chondrocytes, which depend on glucose for normal cell functions and cartilage matrix synthesis, become poorly adapted to fluctuating glucose levels. Consequently, chondrocytes take up excess glucose during OA onset. Aquaporins (AQPs), crucial transmembrane proteins for water transport, help regulate metabolic water in cartilage, indicating their crucial role in maintaining cartilage morphology and ionic balance.

Objective: The expression characterizations of the AQP molecules in articular cartilage cells in DM diseases may be negatively affected and may lead to functional disorders in the joints. Based on this hypothesis, we aimed to investigate the immune expressions of AQP molecules in articular cartilage cells of rats in which a diabetes model was created.

Methods: The study utilized Wistar albino adult male rats, weighing between 150-300 g. Rats were divided into two groups: Sham control (n=7) and Diabetes (n=7). Type II diabetes was induced in the diabetic group using streptozocin (STZ) at a dose of 150 mg/kg via intraperitoneal injection. The sham control group received saline injections. After a 24-hour fasting period and on the 10th day post-STZ administration, fasting blood glucose levels were measured. Rats with glucose levels ≥250 mg/dL were classified as diabetic. Following the experiment, rats were euthanized, and knee joints were extracted for analysis. The expression of AQPs 5 and 8 in articular cartilage chondrocytes was assessed immunohistochemically. Immunostaining results were quantified using H-scores and statistically analyzed.

Results: Diabetic rats exhibited significantly elevated blood glucose levels (≥250 mg/dL) compared to controls. Immunohistochemical analysis revealed a decrease in both AQPs 5 and 8 expression in articular cartilage cells of the diabetic rats compared to the sham controls. Notably, AQP 8 was identified in articular chondrocytes for the first time in this study.

Conclusions: The study indicates that diabetes mellitus is associated with reduced expression of AQPs 5 and 8 in articular chondrocytes. This reduction in AQP expression could contribute to joint dysfunction observed in diabetic conditions. Further research with higher methodological rigor is needed to confirm these findings and elucidate the underlying mechanisms.

Keywords: Aquaporins, Chondrocyte, Diabetes mellitus, Immune expression,

Oral Presentation

THE ROLE OF HIPPO SIGNALING PATHWAY AND CELL POLARITY IN VARICOCELE-INDUCED APOPTOSIS

SIMLA SU AKKAN | EZGİ GOLAL | NURAY ACAR AYDEMİR

Akdeniz University, akkansimla@gmail.com

Abstract

Introductıon: Varicocele is known as the abnormal dilation of the testicular veins in the pampiniform plexus within the testicular tissue. The increase in reactive oxygen species and nitric oxide in varicocele leads to changes in adhesion molecules and cytoskeleton organisation in Sertoli cells, especially affecting the structure of the blood-testicular barrier. This condition causes disruptions in the translocation of germ cells during spermatogenesis, leading to significant consequences that can affect fertility. The Hippo signaling pathway is known to regulate proliferation, apoptosis, and differentiation, as well as being activated by various internal and external signals such as cell-cell contact, stress signals, and cell polarity. While many studies on varicocele mechanisms have concentrated on changes in adhesion molecules, the role of polarity proteins -key structural elements of the Sertoli cell cytoskeleton- and the associated cellular pathways remain relatively unexplored. In this study, we aimed to investigate the effects of varicocele on the expression of Scribble, a polarity protein involved in the blood-testis barrier, and YAP, TEAD, and CTGF, key components of the Hippo signaling pathway.

Materıals And Methods: This study was conducted with a total of 42 male Sprague Dawley rats obtained from the Akdeniz University Experimental Animal Application and Research Center (ADAM). The rats were randomly divided into three groups: Control(n=14) Sham(n=14), Varicocele(n=14). Thirteen weeks after the establishment of the experimental model, animals were sacrificed. The tissues were stained with Hematoxylin-Eosin and examined under a microscope to detect seminiferous tubule degeneration. The expression levels of Scribble, YAP, TEAD, and CTGF were demonstrated using Western Blot and Immunohistochemistry methods. One-wayANOVA was applied to analyze the differences between the groups.

Results: Our analyses revealed a significant increase in seminiferous tubule degeneration in the experimental varicocele model. Additionally, a significant decrease in Scribble protein levels($p<0.05$) and a marked increase in YAP, TEAD, and CTGF protein levels compared to the control group were observed($p<0.05$).

Dıscussıon-Conclusıon: The decrease in Scribble expression, which plays a role in cell polarity, under conditions caused by varicocele, suggests that it may lead to disruptions in the blood-testis barrier and the spermiation mechanism. Therefore, YAP may have participated in or triggered varicocele-induced apoptosis by increasing pro-apoptotic activation in the nucleus in conjunction with TEAD. This study aims to link cell polarity to the Hippo pathway and to provide a mechanistic basis for how varicocele-induced apoptosis might affect spermatogenesis. More detailed studies are needed to clarify the relationship between increased apoptosis and impaired cell polarity in varicocele.

Oral Presentation

ANTI-PSORIATIC EFFECTS OF BERGENIN AND STEM CELL ADMINISTRATION IN AN IMIQUIMOD-INDUCED PSORIASIS-LIKE MOUSE MODEL: TARGETING NLRP3 INFLAMMASOME COMPLEX AND NRF2/KEAP1/SIRT1 PATHWAYS

SEDA KESKİN | EDA AÇIKGÖZ | MUSTAFA CAKIR

Department Of Histology And Embryology, Faculty Of Medicine, Van Yuzuncu Yil University, 65090, Van, Turkey
sedakeskin@yyu.edu.tr

Abstract

Introduction: Psoriasis is a chronic autoimmune disease marked by scaly, erythematous skin plaques, driven by abnormal keratinocyte-immune cell interactions, leading to inflammation and keratinocyte hyperproliferation. Current treatments provide temporary symptom relief but have serious side effects. More effective treatments are needed in the long term. Recent studies implicate NLRP3 inflammasome activation and Nrf2/Keap1/SIRT1 signaling disruptions in disease progression, highlighting the potential of novel anti-inflammatory and immunosuppressive strategies targeting these pathways.

Objective: The aim of this study was to investigate the potential therapeutic effects of combined anti-inflammatory Bergenin (BER) and immunosuppressive mesenchymal stem cells (MSCs) on NLRP3 inflammasome complex and Nrf2/Keap1/SIRT1 axis in an imiquimod (IMQ)-induced psoriasis-like mouse model.

Material &Method: A total of 48 BALB/c mice were divided into the following groups: Control, Saline+Vaseline (SAL+VAS), BER, MSCs, IMQ, IMQ+BER, IMQ+MSCs, and IMQ+BER+MSCs. The psoriasis like mice model was established by applying topical IMQ to the back and ear skin for 7 days. In addition to macroscopic observations, the Psoriasis Area Severity Index (PASI) score was used to assess the severity and extent of psoriasis. Histological and biochemical changes in the skin and spleen were examined using histochemical staining (H&E, Masson Trichrome, and PAS), and epidermis and dermis volume alterations were determined using the Cavalieri method. Immunohistochemistry was employed to assess the immunoreactivity intensities of NLRP3 inflammasome components, Nrf2, Keap1, and SIRT1 using ImageJ. Inflammatory cytokines levels (TNF-α, IL-1β, IL-17A, IL-22 ve IL-23) were analyzed using ELISA.

Results: Histopathological and stereological data revealed that the IMQ+BER, IMQ+MSCs, and IMQ+BER+MSCs treatment groups, compared to the IMQ group, exhibited: i) lower PASI scores, ii) reduced keratinocyte hyperproliferation, parakeratosis, and Munro micro abscess formation, iii) reduced immune cell infiltration and vascularized areas in the dermis, iv) reduced increases in epidermal and dermal volume, and v) significantly reduced splenomegaly and white pulp area expansion in the spleen. BER and MSCs treatments significantly decreased the intensities of NLRP3, ASC, Caspase-1, IL-1β, Nrf2, and Keap1 in the skin, as well as cytokines levels linked to psoriasis, while also significantly increasing SIRT1 intensity compared to the IMQ group.

Conclusion: In summary, the combined treatments of BER and MSCs were shown to suppress the NLRP3 inflammasome and Keap1/Nrf2 signaling pathways, while alleviating psoriasis symptoms in the psoriasis model by enhancing SIRT1 activation. This study demonstrates that the potent anti-inflammatory and anti-psoriatic effects of BER, combined with the immunomodulatory activity of MSCs, may represent a promising therapeutic approach for psoriasis.

Keywords: Psoriasis, Bergenin, Mesenchymal Stem Cell, NLRP3 Inflammasome, Nrf2, SIRT1
Acknowledgement: This research was supported by VAN YYU Scientific Research Projects Unit within the scope of the doctoral project numbered TDK-2022-10132.

Oral Presentation

INVESTIGATION OF THE IMPACT OF SYSTEMIC URSODEOXYCOLIC ACID APPLICATION ON PERIODONTAL TISSUES IN RATS WITH EXPERIMENTAL PERIODONTITIS

ALİ KURT[1] | SEDA ŞİMŞEK[2] | ENDER ERDOĞAN[2] | İSMAİL MARAKOĞLU[1]

[1]Selcuk University, Faculty Of Dentistry | [2]Selcuk University, Faculty Of Medicine, Department Of Histology And Embryology
sedaatay89@gmail.com

Abstract

Objectives: With the understanding host response in periodontitis, researchers focused on unravelling the inflammatory response. Many drug trials have been conducted to resolve inflammation in periodontitis. In this study, effects of the systemic use of ursodeoxycholic acid (UDCA) on the periodontium in rats with experimental periodontitis, were investigated.

Methods: Thirty-eight Wistar Albino male rats were randomly divided into five subgroups; first control group, second group that had periodontitis for the first 10 days and waited for 30 days, third group that had periodontitis for the first 10 days and applied systemic UDCA for 30 days, fourth group that had periodontitis for the last 10 days, fifth group that had systemic UDCA for the first 30 days and had periodontitis on last 10 days. For the drug administered groups,20mg/kg/day UDCA was dissolved 50 ml of saline and administered as gavage at the same time every day. At the end of the 40th day all rats were sacrificed and rat's maxillae bones histological measurements, IL-1b, IL-10, RANKL, OPG were detected using the image J program.

Results: In the 1st,2nd and 3rd groups, where the therapeutic effect was observed, RANKL with IL-1b was significantly higher in the 2nd and 3rd groups compared to the 1st group, while the 2nd group was significantly higher than the 3rd group. While IL-10 and OPG values were significantly higher in the 2nd and 3rd groups compared to the 1st group, the 3rd group was significantly higher than the 2nd group. Considering the IL-1b and RANKL values in the 1st, 4th and 5th groups, where the protective effect was observed, the increase in the 4th group was more significant than the other groups. OPG showed a significant increase in the 5th group compared to the 1st and 4th groups.IL-10 values showed a significant increase in the 5th and 4th groups compared to the 1st group.

Conclusions: Considering these results, the anti-inflammatory effect of systemic UDCA administration in rats with experimental periodontitis is clearly observed.

Oral Presentation

THE EFFECTS OF XENIN-25 ON INDOMETHACIN-INDUCED GASTRIC ULCERS IN RATS

SEVİL ARABACI TAMER[1] | FERİHA ERCAN[2] | BERRAK YEĞEN[3]

[1]Sakarya University Department Of Physiology, Sakarya, Türkiye | [2]Marmara University, Department Of Histology And Embryology, Istanbul, Türkiye | [3]Marmara University, Department Of Physiology, Istanbul, Türkiye

sarabaci@sakarya.edu.tr

Abstract

Introduction: Gastric ulcer is an injury to the gastric mucosa caused by various pathogenic factors penetrating the deep muscular layer of the mucosa (1). This study was designed to investigate the potential gastroprotective effect of the Xenin-25 peptide on acute oxidative gastric damage induced by indomethacin.

Materials and Methods: Male Sprague-Dawley rats were randomly divided into a control group (n=7) and ulcer groups treated with saline or Xenin-25 (0.2, 2, or 20 µg.kg-1) (n=28). The rats were fasted for 24 hours prior to indomethacin administration (25 mg/kg, 5% $NaHCO_3$, subcutaneously), but had free access to water. Immediately after ulcer induction, saline or Xenin-25 was administered subcutaneously, and treatments were repeated at the second hour. At the fourth hour following ulcer induction, the animals were decapitated under ketamine and xylazine anaesthesia (100 and 10 mg.kg-1, intraperitoneally). Gastric tissues were then collected for macroscopic scoring, determination of malondialdehyde and glutathione levels as oxidant and antioxidant parameters and histopathological changes. Statistical analysis of the data was performed using one-way ANOVA with GraphPad Prism 9.0 software.

Results: Compared to the ulcer group treated with saline, the macroscopic damage score significantly decreased in the group treated with 2 $\mu g.kg^{-1}$ Xenin-25 ($p<0.01$), with a trend towards reduction observed at doses of 0.2 and 20 $\mu g.kg^{-1}$. Gastric lesions were significantly reduced ($p<0.05$-0.001) and moderate mucosal degeneration with desquamated surface mucous cells, dilated glandular structures and inflammatory cell infiltration were observe at all administered doses of Xenin-25. All doses of Xenin-25 suppressed malondialdehyde levels, indicating lipid peroxidation ($p<0.001$), while higher doses led to an increase in glutathione levels ($p<0.001$).

Conclusions: Xenin-25 exhibited a gastroprotective effect by suppressing histological and oxidative damage in acute gastric injury induced by indomethacin in rats.

Acknowledgements
This study was supported by a grant of Sakarya University Research Fund (Project no: 2023-20-45-27).

Oral Presentation

DETERMINATION OF CURCUMIN PROTECTIVE EFFECT ON NEUROTOXICITY INDUCED BY GLIOBLASTOMA-DERIVED EXOSOMES

ALPEREN ENES AYDIN[1] | SIDIKA GENÇ[2] | ALİ TAGHIZADEHGHALEHJOUGHI[2]

[1]Sakarya University, Department Of Medical Pharmacology, Faculty Of Medicine, 54050, Sakarya, Türkiye | [2]Bilecik Şeyh Edebali University, Department Of Medical Pharmacology, Faculty Of Medicine, 11230, Bilecik, Türkiye

alperenenesaydin@gmail.com

Abstract

Introduction:
GBM is the most aggressive primer brain tumor. Exosomes are extracellular vesicles with 40-150 nm in diameter. Exosomes have many physiological effects but recently toxicity of the exosome raised attention. Curcumin is a natural antioxidant substance. It has many natural functions such as antibacterial, antiviral, and antioxidant. Glioblastoma cells by secreting exosomes increased neurotoxicity.

Objective: The study aimed to evaluate the protective effect of curcumin against Glioblastoma (GBM) derived exosome toxicity on neuron cell culture.

Material and method: T98G cells were used for the GBM exosome source. The toxicity model was done in the neuron cell line. Different doses of exosomes were exposed to the neuron cell for 24 h. In the the study, scanning electron microscope (SEM), 3-(4,5-dimethylthiazol-2-yl)-2,5-diphenyltetrazolium bromide (MTT), Total Antioxidant Capacity (TAC), Total Oxidant Number (TOS) analyses were done.

Result and Conclusion: The exosomes are depicted as round structures, ranging in size from 27.41 nm to 41.42 nm. According to the result, An amount of 4 µg/mL of T98G-derived exosomes depleted MTT with a statistically significant difference of $p<0.05$. Higher dosages of 8-32 µg/mL depleted MTT in a more significant ($p<0.001$). Figure 2 B shows curcumin's 2 µg/mL protective effect against T98G 2, 4, and 8 µg/mL (Figure 2). The data obtained have shown that curcumin reduces oxidative stress in neuronal cells. Although toxicity is seen from 4 micrograms without curcumin, toxicity is seen to decrease significantly. In conclusion, the identification of a neurotoxic effect of GBM exosomes suggests how exosomes can be considered as both biomarkers and targets and their characterization could significantly improve the management of GBM patients.

Poster Presentation

ADVANCING CANCER RESEARCH: EVALUATING IMMUNOTHERAPY EFFICACY USING PATIENT-DERIVED ORGANOIDS

ELİF ERTURK[1] | FERDA ARI[2] | OGUZHAN AKGUN[2] | YAREN YİLDİZ[2] | DİGDEM YOYEN ERMİS[3] | FATMA DOMBAZ[3] | HALUK BARBAROS ORAL[3] | AHMET SAMİ BAYRAM[4] | HUSEYİN MELEK[5] | ELİF ULKER AKYİLDİZ[6] | ADEM DELİGONUL[6] | ERDEM CUBUKCU[6] | TURKKAN EVRENSEL[5] | MEHMET FATİH INECİKLİ[7] | GİYASEDDİN OZCAN[8] | SEHİME GULSUN TEMEL[9] | SEBNEM OZEMRİ SAG[9]

[1]Bursa Uludag University, Vocational School Of Health Services, Bursa, Türkiye, eliferturk@uludag.edu.tr | [2]Bursa Uludag University, Faculty Of Arts And Sciences, Department Of Biology, Bursa, [3]Bursa Uludag University, Faculty Of Medicine, Department Of Immunology, Bursa, Türkiye | [4]Bursa Uludag University, Faculty Of Medicine, Department Of Thoracic Surgery, Bursa, Türkiye [5]Bursa Uludag University, Faculty Of Medicine, Department Of Medical Pathology, Bursa, Türkiye | [6]Bursa Uludag University, Faculty Of Medicine, Department Of Medical Oncology, Bursa, [7]Bursa Uludag University, Faculty Of Medicine, Department Of Radiology, Bursa, Türkiye | [8]Bursa Uludag University, Faculty Of Engineering, Department Of Computer Engineering, Bursa, Türkiye | Bursa Uludag University, Faculty Of Medicine, Department Of Medical Genetics, Bursa,

Abstract

Introduction: 2D cell cultures are far from complex tissue formation and cell-cell interactions. Therefore, they cannot fully meet clinical efficacy. At this point, the development of patient-derived organoid culture approaches has provided effective opportunities to test or predict drug responses in sensitive cancer therapy. However, conventional organoids are not sufficient for immunotherapy, which is a current and effective treatment especially in non-small cell lung cancer. Since immunotherapy targets the tumor with T-lymphocytes, complex organotypic tumor models that include the immune response are needed.

Objective: In this context, the aim of the current study is to create organotypic tumor models from lung cancer tumor samples and immune cells taken from untreated patients and to characterize them in terms of suitability for immunotherapy treatment.

Material-Method: In this study, patients tumor samples were characterized for ALK/ROS1 rearrangements and EGFR mutations. ALK/ROS1 rearrangements were determined by FISH staining and ALK/ROS1 negative/EGFR mutation negative patient biopsy samples were included in the study. Tumor samples were co-cultured with lymphocytes from the same patients and immunotherapy drug responses were evaluated. Drug responses were analyzed using factors such as immune system-induced cell death and caspase-induced apoptotic activity. In addition, CD4/8 T cell proliferation was determined by flow cytometry and tumor immune response was analyzed. The results of cellular analysis were used to build a classification-based decision tree model.

Results and Conclusion: In the present study, drug response values appropriate to the patient profile could be obtained through the analysis of 40 tumors of primary origin. It was also observed that the drug responses of patients routinely receiving immunotherapy in the clinic were consistent with the organotypic models generated from tumor samples. In conclusion, the development of organotypic tumor models and their use in drug response prediction is considered an important step in the field of immunotherapy and personalized cancer therapy.

Research Fund of TUBITAK (Project Number: 221S423).

Keywords: Organotypic Models, Organoids Culture, Immunotherapy

Poster Presentation

EFFECT OF LIPOPOLYSACCHARIDE-INDUCED ACUTE SYSTEMIC INFLAMMATION ON DEPRESSION-LIKE BEHAVIOR IN RATS AND EPHA4 EXPRESSION IN HISTOLOGICAL LAYERS OF THE HIPPOCAMPUS

SENEM ESİN YAVAŞ | ÖZKAN YAVAŞ | SEDA IŞIKLAR | SEMİHA ERSOY

[1]*Bursa Uludag University*
senemesin@uludag.edu.tr

Abstract

Introduction: Depression is a highly prevalent neuropsychiatric disorder with a complex etiology worldwide, particularly affecting women. The hypothesis that depression and illness behavior are similar has been strengthened with increasing evidence that these phenomena are also associated with inflammation. Abnormal neuroplasticity (neurogenesis, axon branching, dendritogenesis, and synaptogenesis) in some areas of the central nervous system, particularly in the hippocampus, is considered an essential factor in the pathophysiology of depression. The EphA4 receptor also plays a role in brain plasticity and is the EphA receptor family member with the highest expression level in the adult hippocampus, where plasticity is high. It is known as a negative regulator of neuroplasticity.

Objective: This study aimed to investigate the effect of lipopolysaccharide (LPS)-induced acute systemic inflammation on depressive behavior in rats and EphA4 expression levels in the hippocampus.

Materials and Methods: Wistar albino female rats were used in the study. Rats were divided into two groups: LPS (n=7) and control (n=7). In diestrous rats, acute systemic inflammation was induced by intraperitoneal 5 mg/kg LPS. Open field test and tail suspension test were performed to determine depression-like behaviors. WBC and formula leukocytes in the blood evaluated the presence of systemic inflammation. EphA4 and Iba-1 immunohistochemistry were performed on paraffin brain sections obtained from the subjects.
Results: 24-hour acute systemic inflammation caused a decrease in WBC count and an increase in total neutrophil count. In the LPS group, there was an increase in depression-like behaviors in tail suspension and open-field test assessments compared to the control group. In the LPS group, microglial response in the hippocampus was triggered by an increase in the number of Iba-1 positive staining cells. EphA4 expression levels increased in various histologic tissue layers of the hippocampus.

Conclusion: Our findings suggest that modulation and monitoring of EphA4 receptor expression and plasticity can be used to develop novel therapeutic strategies for neuropathologies that develop after inflammatory processes. Furthermore, combining the two existing hypotheses of depression (inflammatory and neuroplasticity) may allow for a more integrated approach and a better understanding of the underlying mechanisms in the development and progression of depression.
This study was supported by the Bursa Uludağ University Scientific Research Projects Coordination Unit with the project code TDK-2021-552.

Poster Presentation

ALLOCATION AND ULTRASTRUCTURAL CHARACTERISTICS OF MACROPHAGES WITHIN LUNG TISSUE

ALİYARBAYOVA AYGUN[1] | HASANOV ILQAR[2] | MEHRALİYEVA GULSHAN [1]

[1]*Azerbaijan Medical University, alyarbayova@gmail.com*

[2]*Ozon Medical Centre, Ganja, Azerbaijan*

Abstract

Introduction. Macrophages are dynamic immune cells performing process phagocytosis, clearing pathogens from tissue, regulated the recruitment of other immune cells during inflammation, tissue regeneration, by secreting pro-inflammatory and anti-inflammatory mediators. It is important to study the location and types of macrophages, that played critical role in maintaining homeostasis of lung tissue.

Objective. The goal of the research was to sort out the type of lung macrophages due to localization and calculate the proportion of these cells.

Material methods. The study was conducted on whole lung tissue receiving from 24 adult male rats keeping in Scientific Research Center of Azerbaijan Medical University. Histological (H&E, picrofuchsin-hematoxylin stained) and immunohistochemical examinations (CD68, CD163, CD207 (langerin)) were performed on section from formalin fixed and paraffin embedded blocks with appropriate staining. The ultrathin sections obtained from Araldite Epon blocks with thickness 50-60 nm, stained with 2.0% uranyl acetate, 0.6% pure lead citrate prepared in a 0.1N solution of NaOH and investigated at 80.0 kV on the JEM-1400 transmission electron microscope (Japan). Morphometric parameters were analyzed by methods of variational and nonparametric statistical analysis (M±m; P=0.95; $p<0.05$; $\chi 2$; r).

Results. On histological and immunohistochemical examination revealed the three subpopulation of macrophages depends on its location. First the largest on size, amount the alveolar macrophages situated within lumen, on the wall of alveoli (44.2±4.2%). The second groups included the bronchial macrophages detected in the lumen and wall of large, medium, small sized bronchi (14.8±1.3 %). The third - interstitial BALT macrophages, that occupied most area within parenchyma of the lung and around the bronchi (41.0±4.2%). Macrophages of rat lungs constituted the 8.8±1.0% of the total cell composition of the organ. All macrophages recognized by acidophilic cytoplasm and lobulated nucleus. Dendritic macrophages within BALT characterized by long thin processes, whereas the interstitial macrophages, situated in lung parenchyma have one or more processes of distinct size. But macrophages detected in alveolar lumen have oval or round shape. Under stereometrics examination, the largest macrophages detected in the alveoli with the diameter 13.6±1.4μm. Ultrastructurally observed the irregular surface of cell membrane of macrophage, lobulated nucleus with condensed, dispersed chromatins, cytoplasm filled with numerous lysosomes, residual bodies, osmiophilic crystalloid deposits, few mitochondria, scattered cytoskeletal filaments.

Conclusion. Considered the allocation and specific function of lung macrophages, such as ability to participation in immune response and inflammation, maintaining homeostasis in lung these cells prevent and treat many lung diseases.

Keywords: immunohistochemistry, lung, macrophage, ultrastructure.

Poster Presentation

IDENTIFICATION OF THE PHOENIXIN RECEPTOR GPR-173 IN RAT LACRIMAL GLAND

ESRA BİHTER GURLER[1] | HÜLYA CEVİK ARAS[2] | MERVE ACİKEL ELMAS[3] | SERAP ARBAK[3]

[1]Istanbul Galata University, Faculty Of Dentistry, Department Of Physiology Istanbul, Turkiye | [2]University Of Copenhagen, Faculty Of Health And Medical Sciences, Section For Oral Biology And Immunopathology/Oral Medicine, Department Of Odontology, Copenhagen, Denmark | [3]Acibadem University, School Of Medicine, Department Of Histology And Embryology, Istanbul, Turkiye, acikelmerve@gmail.com

Abstract

Introduction: Phoenixin, a peptide derived from the Smim20 protein, was initially identified as a versatile gut-brain messenger. This peptide has been shown to influence various physiological processes, including reproduction, anxiety, thirst, memory formation, lipid metabolism, and appetite control. The discovery of phoenixin has paved the way for understanding its receptor and potential biological functions. Research has linked phoenixin to the previously orphan G-protein coupled receptor GPR173, which is now considered the primary mediator of phoenixin's effects. According to the Human Protein Atlas, GPR173 has been detected in salivary glands but not in lacrimal glands, providing insight into its tissue distribution and potential functional areas. In our study, we aimed to detect GPR 173 receptor in lacrimal gland.

Materials And Methods: Under anesthesia, the bilateral salivary and lacrimal glands were removed from 12 male and female Sprague-Dawley rats. Tissues were fixed in formalin solution for routine histologic analysis and fixed with 4% paraformaldehyde solution for immunofluorescence analysis. All tissues were analyzed for the expression of GPR173 by immunofluorescence and Western blotting.

Results: Our investigation revealed the presence of GPR173, the proposed phoenixin receptor, in the lacrimal gland. Sublingual and submandibular salivary glands were used as positive controls for the GPR173 receptor. The positive controls were selected in accordance with the protein atlas. GPR173 was expressed in the acinar and tubular cells of these salivary glands. This receptor activity was also detected in the acinar cells of the lacrimal gland. The Western blot results were corralled with the microscopic results.

Conclusion: Our findings demonstrate that GPR173, the proposed receptor for phoenixin, is expressed at varying levels in the lacrimal gland. This differential expression suggests a potential role for the phoenixin-GPR173 signaling pathway in lacrimal gland function. However, additional research is necessary to elucidate the specific physiological implications of phoenixin in the lacrimal gland. Further studies could help uncover the precise mechanisms and functions of this peptide-receptor system in tear production, gland maintenance, or other aspects of ocular health.

Poster Presentation

P2Y$_2$ RECEPTOR EXPRESSION IN NUCB2/NESFATIN-1 OXYTOCIN AND VASOPRESSIN NEURONS IN SUPRAOPTIC AND PARAVENTRICULAR NUCLEI OF THE RAT HYPOTHALAMUS

NURSEL HASANOĞLU AKBULUT[1] | GONCA TOPAL[2] | CANSU KOÇ[3] | BERNA SALMAN[3] | MERHMET CANSEV[3] | ÖZHAN EYİGÖR[1]

[1]Çanakkale Onsekiz Mart University Faculty Of Medicine, Department Of Histology And Embryology, Canakkale, Turkey | [2]Bursa Uludağ University Faculty Of Medicine, Department Of Histology And Embryology, Bursa, Turkey | [3]Bursa Uludağ University Faculty Of Medicine, Department Of Medical Pharmacology, Bursa, Turkey,
nurselhasanoglu@comu.edu.tr

Abstract

Introduction: NUCB2/nesfatin-1, oxytocin (OT) and vasopressin (VP) neurons are expressed in the supraoptic (SON) and paraventricular (PVN) nuclei of the hypothalamus. Vasopressin is involved in the regulation of fluid homeostasis, whereas oxytocin is involved in the regulation of instinctive behaviours (eating and drinking, sleeping and waking, etc.) and autonomic neural activities (heart rhythm, gastrointestinal tract contraction, breathing rhythm and sweating, etc.) in addition to maternal behaviours such as parturition and milk secretion. NUCB2/nesfatin-1 is involved in the regulation of physiology such as cardiovascular system, stress, immune system as well as regulating energy metabolism by inhibiting food intake. All P2Y receptors are G-protein-coupled receptors (GPCRs) for extracellular nucleotides. Eight P2Y receptor subtypes have been identified (P2Y1, P2Y2, P2Y4, P2Y6, P2Y11, P2Y12, P2Y13 and P2Y14). Apart from ATP and UTP, which are endogenous agonists for P2Y2 receptor, P2Y2 receptor agonists and antagonists with a wide range of physiological and pathophysiological potentials are currently being developed.

Objective: In our study, we aimed to show NUCB2/nesfatin-1 expressed in SON and PVN nuclei of the hypothalamus, and P2Y2 receptor protein expression in OT and VP neurons using dual immunofluorescence method.

Material-Method: Male Sprague Dawley rats aged 4-6 months were used in the study. The rats were fixed with 4% paraformaldehyde prepared in phosphate buffer given transcardially without any treatment. The brain tissues were post-fixed in 4% paraformaldehyde at +4 °C overnight. After the fixation was completed, brain sections were taken in 5 series with a thickness of 40 µm, including the entire rostra-caudal axis with a vibratome. Double immunofluorescence method using anti-NUCB2/nesfatin-1, anti-oxytocin and anti-vasopressin antibodies in combination with anti-P2Y2 antibodies was applied to the obtained floating sections. The obtained preparations were evaluated under fluorescence microscope in terms of double labelled neurons in the SON and PVN where NUCB2/nesfatin-1, OT and VP neurons are densely located.

Results: The present study shows that the P2Y2 receptor is expressed in NUCB2/nesfatin-1, VP and OT-containing neurons in the SON and PVN of the rat hypothalamus.

Conclusion: In conclusion P2Y2 receptor agonists and antagonists may regulate NUCB2/nesfatin-1 VP and OT release from these neurons in the SON and PVN by causing activation and inhibition of P2Y2 receptors.

Key words: NUCB2/nesfatin-1, Oxytocin, Vasopressin, P2Y receptors, Immunohistochemistry
This study was supported by Bursa Uludag University BAP Unit (TOA-2021-684).

Poster Presentation

EFFECT OF NARINGIN AND PREDNISOLONE TREATMENT ON BLOOD-TESTIS BARRIER IN EXPERIMENTAL RHEUMATOID ARTHRITIS MODEL

GİZEM KAYA | LEMAN SENCAR | GÜLFİDAN COŞKUN | SAİT POLAT | ÖZLEM GÖRÜROĞLU ÖZTÜRK | ALPER ÇELENK

Çukurova University Faculty of Medicine Department of Histology and Embryology
sencarleman@gmail.com

Abstract

Introduction: Rheumatoid arthritis (RA) is a chronic inflammatory disease characterized by cartilage and bone destruction. Due to their side effects of glucocorticoids used in treatment, the benefit/risk ratio remains uncertain. Prednisolone is a potent glucocorticoid used in treating autoimmune diseases due to its antiallergic and anti-inflammatory effects. Naringin is an active flavonoid found in many citrus fruits, has antioxidant, anticancer, and anti-inflammatory properties. There is no study in the literature investigating the damage RA causes to the blood-testis barrier and the comparative effects of Naringin and Prednisolone, on testicular injury.

Objective: This study aimed to investigate, using immunohistochemical, biochemical, histomorphometric, and microscopic methods, the effects of separate and combined treatments with Naringin and Prednisolone on the expression of blood-testis barrier proteins Connexin-43 and Occludin, serum testosterone and LH levels, and testicular damage in an experimental RA model.

Materials and Methods: 36 male mice were divided into 6 groups: healthy control group, sham group received distilled water, arthritis group induced by Freund's Complete Adjuvant (FCA) without treatment, Prednisolone (10 mg/kg) treatment group for 28 days after arthritis induction, Naringin (150 mg/kg) treatment group three times a week for 30 days after arthritis induction, and combined Naringin and Prednisolone treatment group with the same doses and duration. Testis tissues samples obtained from all groups on day 51 were examined by using microscopic, immunohistochemical, biochemical, and histomorphometric methods.

Results: In the arthritis group, seminiferous tubules degeneration, decreased expression of Sertoli cell junction proteins Connexin-43 and Occludin, and reduced serum levels of LH and testosterone were observed. In the Prednisolone group, widespread degeneration in seminiferous tubules and tight junctions, decreased Connexin-43 and Occludin expression, and lower testosterone levels compared to the control were noted. In the Naringin group, the testicular composition was close to normal, also significant increase in Connexin-43 and Occludin expression and serum testosterone levels compared to the arthritis and other treatment groups were seen. In the combined treatment group, degenerative changes in the testis tissue samples were reduced, moreover Connexin-43 and Occludin expressions increased compared to the arthritis and Prednisolone groups, and testosterone and LH levels were observed.

Conclusion: Considering all the results, it was concluded that Naringin treatment was more effective agent than Prednisolone in repairing testicular damage and maintaining blood-testis barrier integrity after arthritis. On the other hand, Naringin treatment could protect the testes from the adverse effects of both arthritis and Prednisolone.

Keywords: Blood-testis barrier, Naringin, Prednisolone, Rheumatoid arthritis, Ultrastructure

Poster Presentation

THE EFFECT OF PREPUBERTAL DI-2-ETHYLHEXYL PHTHALATE EXPOSURE ON HIPPOCAMPUS IN RATS

ALEV KURU[1] | MUHSİN KONUK[1] | BAŞAK YAVUZ[2]

[1]Üsküdar University |[2] İzmir Democracy University Faculty Of Medicine
drbasakbuyuk@gmail.com

Abstract

Introduction: Phthalates are a class of chemicals widely utilized in the production of flexible plastics and various consumer products. Their primary function is to enhance the flexibility and durability of plastics, making them integral to numerous household items. Di-(2-ethylhexyl) phthalate (DEHP) is the most well-known member of the class of phthalates used as plasticizers for polymer products to convert plastic products into a flexible format. However, the health implications of DEHP exposure have raised significant concerns among researchers and health professionals. Studies indicate that phthalates can disrupt endocrine functions, posing risks to human health, particularly in vulnerable populations such as pregnant women and children.
The aim of this study is to investigate the effect of DEHP exposure during neonatal period on hippocampus of rats.
Methods: Twenty-six newborn Wistar albino rats were randomly divided into two groups.
Group 1 (Control Group, n=13)
Group 2 (Phthalate Group, n=13)
0.1 ml/day of corn oil administered subcutaneously to animals in the control group for 65 days from birth. DEHP prepared in corn oil (in 250 ml) was administered subcutaneously to 14 newborn rats with the dose of 300 mg/kg/day in the experimental group for 65 days from birth. After intracardiac perfusion, hippocampus tissues were taken from sacrificed animals and subjected to tissue processing for histopathological examination. Sections were analyzed under light microscope.
Cellular shrinkage, interstitial edema criteria were used for evaluating the histopathological damage. Results were graded as follows,
Grade 0: No damage
Grade 1: mild damage
Grade 2: Moderate damage
Grade 3: Severe damage
Results: Hippocampus tissues of animals were evaluated, and interstitial edema and cellular shrinkage rates were found to be higher in the experimental groups compared to the control group. No statistical difference was observed in the results obtained from male animals.
Conclusion: Prepubertal DEHP exposure can cause histopathological damage in the hippocampus. Further studies are needed.

Keywords: Di-(2-ethylhexyl) phthalate, rat, hippocampus

Poster Presentation

SYNERGISTIC INHIBITION OF HCT-116 COLORECTAL CANCER CELL VIABILITY BY TARGETING GLUT1 AND SOLIFENACIN: A NOVEL THERAPEUTIC STRATEGY

ONUR ONGUNCAN | SABİRE GÜLER

Bursa Uludag University Faculty of Veterinary Medicine Department of Histology-Embryology
onuronguncan@uludag.edu.tr

Abstract

Introduction: Colorectal cancer remains one of the leading causes of cancer-related morbidity and mortality worldwide. Despite advances in screening and therapeutic interventions, the prognosis for advanced CRC continues to be poor, highlighting the urgent need for novel therapeutic strategies. The glucose transporter (GLUT) family, particularly GLUT1, has been implicated in the metabolic reprogramming of cancer cells, facilitating the increased glucose uptake essential for rapid tumor growth and survival. Targeting GLUT-mediated metabolic pathways has emerged as a potential strategy for inhibiting tumor progression. Recent studies have suggested that Solifenacin, an antimuscarinic agent traditionally used for the treatment of overactive bladder, may exhibit off-target effects that could influence cancer cell metabolism. Considering this off-target effect of solifenacin, it is important to evaluate its combined effect with a GLUT inhibitor.

Aim: This study aims to investigate the effects on the viability of colorectal cancer cells following the inhibition of GLUT1 and Solifenacin.

Material-Method: HCT 116(CCL-247, Human colorectal carcinoma) cells were utilized as a model for colorectal cancer in this study. The cells were divided into four experimental groups: control (treated with DMSO), GLUT1 inhibition, Solifenacin, and the combination of GLUT1 inhibition with Solifenacin. GLUT1 inhibitor doses of 5,10,20 and 30 µm and solifenacin doses of 5,10,15 and 20 µm were chosen according to our previous studies. Cell viability was assessed using the Sulforhodamine B (SRB) assay, with promising drug combinations further validated through the Luminescent Cell Viability assay (CellTiter-Glo). Synergistic interactions between treatments were quantified using the SynergyFinder online tool(https://synergyfinder.org)(Faculty of Medicine at University of Helsinki , Helsinki, Finland) program, which is used to determine synergy, and combination indexes were calculated.

Result: The combination of GLUT1 inhibition and Solifenacin at various concentrations demonstrated significant synergistic effects in HCT-116 cell lines. Compared to the individual treatments, the combined use of GLUT1 inhibitor and Solifenacin resulted in a sevenfold increase in HCT-116 cancer cell inhibition. Notably, the combination index (CI) values, which indicate synergy (CI < 1), were as low as 0.01 for the combination of 20 µM Solifenacin with 30 µM GLUT1 inhibitor in HCT-116 cells ($p<0.05$) **There was no difference between the single use of the drugs and the control group($p>0.05$).**

Conclusion: The results of this study suggest that the combination of GLUT1 inhibition and Solifenacin exerts a highly synergistic effect on the viability of HCT-116(Colorectal

Carcinoma) colorectal cancer cells, significantly enhancing cancer cell inhibition compared to individual treatments. These findings indicate that targeting GLUT1-mediated metabolic pathways, in conjunction with Solifenacin treatment, holds promise as a novel therapeutic strategy for HCT-116(Colorectal Carcinoma) colorectal cancer. Further investigation is warranted to fully elucidate the underlying mechanisms and to explore the potential clinical applications of this combination therapy.

Poster Presentation

CAPSAICIN AUGMENTS CISPLATIN EFFICACY IN NSCLC:

TÜLAY MUTLU[1] | ONUR ONGUNCAN[2] | SABİRE GULER[3]

[1]Bursa Uludag University, Institute Of Health Sciences, Department Of Veterinary Histology And Embryology | [2]Bursa Uludag University, Faculty Of Veterinary Medicine, Department Of Histology And Embryology | [3]Bursa Uludag University, Faculty Of Veterinary Medicine, Department Of Histology And Embryology; Bursa Uludag University Faculty Of Medicine Experimental Animal Breeding And Research Unit Cellular And Molecular Targeting Laboratory
tullayla@gmail.com

Abstract

Introduction: Non-small cell lung cancer (NSCLC) is the most prevalent form of lung cancer, constituting approximately 85% of cases. While early-stage NSCLC can often be surgically treated, many patients are diagnosed at advanced stages, limiting surgical options and worsening prognosis. Cisplatin (Cis), a platinum-based chemotherapy drug, is widely used in NSCLC treatment but is associated with significant toxicities and chemoresistance. Recent studies suggest capsaicin (CAP), a compound from the Capsicum plant, may enhance cisplatin's efficacy while reducing its side effects, offering a promising adjunctive approach in NSCLC therapy.

Aim: This study investigates the effects of combining Cis with CAP on cell proliferation in vitro in NSCLC cells and tumor growth in vivo in xenograft mouse models.

Materials and Methods: In this study, A549 cells were utilized to achieve two specific objectives: (1) The anti-proliferative and apoptotic effects of varying doses of CAP, both alone and in combination with Cis, were investigated in vitro. For this, A549 cells were treated with DMSO, different doses of CAP, Cis, and a CAP/Cis combination for 48 hours. Following treatment, MTT analysis was performed, and cell proliferation was assessed using Ki-67, while apoptosis was evaluated through cleaved caspase-3, both by immunohistochemistry and western blot methods. (2) The anti-tumorigenic effect of the CAP/Cis combination was evaluated in vivo using lung xenograft mouse models. The care and experimental procedures for the animals were carried out with the approval of the Local Ethics Committee for Animal Experiments (2020-04/02). A549 cells were injected into the bilateral flank regions of 20 athymic nude mice. When tumor volumes reached 150 mm^3, the animals were divided into four treatment groups of 5 mice each (n:5x2=10); vehicle (corn oil), CAP, Cis, and CAP/Cis. Throughout the study, tumor sizes and body weights were monitored. At the end of the experiment, the excised tumor tissues were embedded in paraffin, sectioned, and subjected to histopathological analysis. Cleaved caspase-3 for apoptosis and Ki-67 for proliferation were determined by immunohistochemical methods. Data were evaluated using the IBM Statistics 23 program at a 95% confidence interval, analyzed with the Kruskal-Wallis Test, and differences between the groups were calculated using the Mann-Whitney U Test.

Results: In A549 cells, it was found that the combination of 200 µM CAP with Cis enhanced the efficacy of the chemotherapeutic agent ($p<0.05$). This combination resulted in reduced cell viability and proliferation, as well as induced apoptosis. Supporting the in vitro findings, the xenograft mouse model showed that the CAP/Cis combination significantly inhibited tumor

growth and induced regression (24.37±2.8) compared to the control group (190.23±10.2) ($p<0.05$). Additionally, in the excised tumor tissues, there was a marked decrease in proliferation markers and an increase in apoptotic indicators within the combination treatment group ($p<0.05$).

Conclusion: In NSCLC, the combination of CAP and Cis has been determined to exert more potent anti-proliferative and anti-tumorigenic effects compared to cisplatin monotherapy, suggesting that capsaicin may be a valuable adjunct in the treatment of NSCLC.

Poster Presentation

INVESTIGATION OF THE PROTECTIVE EFFECTS OF VITAMIN A AND OMEGA-3 FATTY ACIDS IN THE HIPPOCAMPAL FORMATION BY EPHA4 AND EPHB2 EXPRESSION IN AN EXPERIMENTAL NEUROINFLAMMATION MODEL IN RATS

DORUK BAŞAR | SENEM ESİN YAVAŞ | AYŞE AKBAŞ | SEMİHA ERSOY

[1]Bursa Uludağ Üniversitesi, Tıp Fakültesi, Histoloji Ve Embriyoloji Ad, Bursa
dorukbasar@hotmail.com

Abstract

Introduction: Alzheimer's disease (AD) is a neurodegenerative progressive disease characterized by age-related progression and a lack of definitive treatment, affecting millions of people worldwide. The main features of the disease are memory loss, decline in cognitive functions, and neuroinflammation. Hippocampal formation is a brain region central to learning and memory processes and plays a significant role in the pathophysiology of AD.

Objective: The study aimed to investigate whether a diet simultaneously rich in vitamin A and omega-3 fatty acids has a protective effect on the hippocampal formation in a rat model of AD induced by lipopolysaccharide (LPS)-mediated neuroinflammatory mechanisms, through the immunohistochemistry of EphA4 and EphB2 receptor expression in the dentate gyrus.

Materials and Methods: The study was conducted on female Wistar albino rats, which were divided into five groups: (1) control group, (2) LPS group, (3) vitamin A-enriched diet and LPS group, (4) omega-3 fatty acids-enriched diet and LPS group, and (5) a combination of vitamin A and omega-3 fatty acids-enriched diet and LPS group. The dietary regiments were applied for 28 days. LPS was administered at a dose of 500 µg/kg/day/i.p. for 7 days to the LPS group and the dietary groups at the end of the 28-day dietary period. Brain sections were obtained from the subjects afterwards and EphA4 and EphB2 receptor immunohistochemistry was performed on the hippocampal dentate gyrus areas of the sections for neuron evaluation.

Results: The results revealed that EphA4 receptor expression, which is typically increased in AD, was elevated in the LPS group but decreased after an application of a combined diet rich in vitamin-A and omega-3 fatty acids. Conversely, EphB2 receptor expression level, which is typically reduced in AD, was decreased in the LPS group but increased in all dietary groups.

Conclusion: In conclusion, this study demonstrated that a diet rich in vitamin A and omega-3 fatty acids can reverse changes in EphA4 and EphB2 receptor expression induced by neuroinlammatory mechanisms.

This study was supported by the Bursa Uludağ University Scientific Research Projects Coordination Unit with the project code TTU-2021-541.

Poster Presentation

THE EFFECT OF NUTRITION RICH IN VITAMIN A AND FISH OIL ON OVARIAN TISSUE IN A MODEL OF SYSTEMIC INFLAMMATION IN RATS

ÇİĞDEM USTA | AYŞE AKBAŞ | SENEM ESİN YAVAŞ | EFE ÖZOĞLU | SEMİHA ERSOY

Bursa Uludag University, Faculty Of Medicine, Department Of Histology And Embryology, Bursa, Turkiye
ayseakbas@uludag.edu.tr

Abstract

Introduction: Although there are studies investigating nutritional supplements in inflammatory cases that develop through different pathways in the ovaries, a combination of vitamin A and fish oil has not been found in the literature.

Objective: This study aimed to investigate the effects of nutritional conditions enriched with vitamin A and fish oil, a source of omega-3, on rat ovarian tissue after lipopolysaccharide (LPS)-induced inflammatory damage.

Materials and Methods: Wistar albino female rats used in the study were divided into five groups: (1) Vitamin A + LPS Group, (2) Omega 3 + LPS Group, (3) Combined Feed + LPS Group, (4) LPS Group and (5) Control Group. 0.5 mg/kg/day LPS was administered intraperitoneally to rats for 7 days. Afterwards, enriched diets were administered for 28 days. Histopathological and morphometric evaluations were performed on paraffin sections stained with hematoxylin-eosin of ovarian tissues removed from the rats. Serum TNF-α levels were measured in blood samples by ELISA.

Results: It has been shown histologically and biochemically that LPS causes chronic inflammation in the rat ovary. It was also observed that it negatively affected follicle development and caused the formation of atretic and cystic follicles. It was determined that the combined diet rich in vitamin A and omega-3 was more effective in suppressing inflammation and reducing the development of atresia and cystic follicles than their single use.

Conclusion: In conclusion; it was thought that the use of nutritional vitamin A and fish oil in combination form could be used as a supportive treatment option in inflammatory cases of the ovaries.

Poster Presentation

BENEFICIAL EFFECTS OF ADIPOSE TISSUE-DERIVED STROMAL VASCULAR FRACTION ON BUSULFAN-INDUCED TESTICULAR DAMAGE

EMİNE RÜMEYSA HEKİMOĞLU[1] | MUKADDES EŞREFOĞLU[1] | FATMA BEDİA KARAKAYA ÇİMEN[1] | BİRSEN ELİBOL [2]| HURİ DEDEAKAYOĞULLARI[3] | ÖZGE PASİN[1]

1 Bezmialem Vakıf Üniversitesi, Tıp Fakültesi, Histoloji Ve Embriyoloji Anabilim Dalı | 2 İstanbul Medeniyet Üniversitesi, Tıp Fakültesi, Tıbbi Biyoloji Anabilim Dalı | 3 Biruni Üniversitesi, Tıp Fakültesi, Tıbbi Biyokimya Anabilim Dalı

f.bedia.k@hotmail.com

Abstract

Introduction and Objectives: Busulfan, a commonly used chemotherapeutic agent, attaches to one of the DNA strands of the cancer cells thus prevents them from dividing. Male infertility is one of the side effects of cancer treatment. Preserving or restoring fertility of these patients constitute an important research area. In recent years, various studies have been published investigating the therapeutic effects of stem cell applications in various diseases. Adipose tissue-derived stromal vascular fraction (SVF), obtained by enzymatic and/or mechanical disintegration of adipose tissue, contains endothelial progenitor cells, hematopoietic cells, pericytes, macrophages, fibroblasts and various growth factors in addition to the stem cells. This study aimed to investigate the therapeutic effects of SVF on busulfan-induced testicular damage.

Materials and Methods: Twenty-four male rats were randomly divided into control, busulfan, SVF and busulfan+SVF group. Testicular damage was induced by single intraperitoneal busulfan (35 mg/kg) application. SVF obtained from human adipose tissue using Lipocube SVF™ was injected into the testicles of rats 5 weeks after busulfan application. Histopathological, biochemical and western blotting analyses were performed on sperm and testicular samples.

Results: Vacuolization, tubular degeneration and atrophy were evident in busulfan group. The mean damage score (OHS) of this group was higher than control ($p<0.001$) and busulfan + SVF ($p=0.006$) group. The mean serum total oxidant level (TOS) was higher than control ($p<0.05$) and busulfan+SVF ($p<0.005$) group. Mean serum and tissue total antioxidant levels (TAS) were lower than those in the control ($p\leq0.001$; $p<0.005$) and busulfan+SVF ($p<0.005$) group. The mean TUNEL + cell count and tissue Bax-Bcl-2 level of busulfan group were higher than control ($p<0.001$, $p<0.05$) group. The mean tissue CD-90 level in busulfan group was higher than control ($p<0.05$) and busulfan+SVF ($p<0.001$) group. Tissue ATG5 level of this group was also higher than control ($p<0.05$) and busulfan+SVF ($p<0.05$) group. Similarly, the mean NF-kB level was higher than control ($p<0.05$) and busulfan+SVF ($p<0.001$) group. On the contrary, the mean tissue TGF-β1 level was lower than the busulfan+SVF ($p<0.001$) group. The mean healthy sperm count in busulfan group was also lower than control ($p<0.001$) and busulfan+SVF ($p<0.001$) groups.

Conclusion: It was concluded that SVF injection reduced busulfan-induced oxidative stress and tissue damage and increased sperm count. SVF may be a promising and effective therapeutic agent in the elimination of testicular damage caused by busulfan toxicity.

Poster Presentation

HISTOLOGICAL, BIOCHEMICAL, AND GENETIC INVESTIGATION OF LIVER AGING IN RAT

YASİN ALİ HASSAN | GAMZE KOCAMAZ | MELİHA TEMİZEL | OĞUZHAN EDEBALİ | AYSEL KÜKNER

Ydü Faculty of Medicine Histology And Embryology
aysel.kukner@neu.edu.tr

Abstract

Introduction: Aging is a chronic, complex and irreversible process that leads to functional disruption in cells. There are various theories at the molecular, cellular, organ and organism levels to explain this process. Structural and functional changes also occur in the liver during aging. The hepatic artery wall thickens, endothelial cell permeability decreases, blood flow and bile acid levels decrease. The number of smooth endoplasmic reticulum and mitochondria in hepatocytes decreases. The aging process in the liver has all cellular characteristics, these changes occur in parenchymal cells and non-parenchymal cells and in the extracellular matrix.
Aim: This study aimed to determine the changes that occur in rat liver tissue due to aging by histological, biochemical and RT-PCR (Reverse-Transcriptase Polymerase Chain Reaction) of caspase-3 (Cas-3), mammalian target of rapamycin (mTOR), interleukin-6 (IL-6) and nuclear factor kappa B (NF-kB) expressions.
Material and Methods: Wistar albino rats were used in the study, two groups were formed: Young-adult group (10 weeks) and aged group (18 months). Blood and tissue samples were taken from the subjects under general anesthesia. Liver enzymes were measured in the blood. IL-6, NF-kB, mTOR, Cas-3 gene expressions from the tissues were evaluated with RT-PCR. Histological scoring was performed on the tissues belonging to the groups. Sections were evaluated with hematoxylin-eosin, Masson trichrome and Periodic acid Schiff (PAS) stains. The obtained results were statistically evaluated with the Two-Way Anova method using the GraphPad program.
Results: Biochemically, when the young group was compared with the aged group, significant increases were observed in cholesterol, triglyceride, AST (aspartate aminotransferase), ALT (alanine transaminase) and ALP (alkaline phosphatase) levels. The number of binucleated hepatocytes increased in the aged group. Histological scoring results supported the light microscope findings. Light microscopically, increased binucleated hepatocytes, vacuolization, sinusoidal congestion, bile duct proliferation, mononuclear cell increase in the aged group, Masson trichrome staining showed collagen increase in the portal area, around v. centralis and between hepatocytes, and PAS staining clearly identified decreased glycogen storage in hepatocytes. While the inflammation marker IL-6, apoptosis marker Cas-3 and autophagy marker mTOR gene expressions showed a significant increase in the aged group, no difference was observed in NF-kB levels.
Conclusion: It has been observed that inflammatory, apoptotic and autophagic changes occur in physiological aging and that these changes affect liver functions. Studying the molecular pathways that play a role in these changes will supply more detailed information.

Key words: liver, aging, microscopy

Poster Presentation

INVESTIGATION OF THE EFFECT OF CURCUMIN ON THE OVARY IN AN EXPERIMENTAL SEPSIS MODEL IN RATS

TUBA DEMİRCİ
Ataturk University Faculty of Medicine Histology and Embryology Department
drtubademirci@gmail.com

Abstract
Aim: Sepsis is a life-threatening infection condition that can cause serious damage to vital organs. Curcumin is a compound derived from turmeric root and it has anti-inflammatory and antioxidant properties. In this study, it was aimed to investigate the protective and therapeutic potential effects of curcumin on ovarian damage that may occur in the experimental sepsis model by histological, immunohistochemical, and biochemical methods.

Material and method: In this study, 40 female rats of the Sprague Dawley were used. The rats were randomly divided into 5 groups. Rats in the control group were not administered any medication. Those in the Vehicle group were given corn oil by oral gavage for 7 days. The CLP model was applied to rats in the cecal ligation perforation (CLP) group. Subjects in the KUR+CLP group were given curcumin at a dose of 200 mg/kg per day as an emulsion by oral gavage before sepsis was established, and the CLP model was applied after 7 days. Those in the CLP + KUR group were given curcumin at a dose of 200 mg/kg per day for 7 days by oral gavage after the CLP model was applied. At the end of the experiment, ovaries and blood samples were taken from the sacrificed rats and analyzed histologically, immunohistochemically and biochemically.

Results: As a result of the histological evaluations performed in the ovarian tissues, it was observed that the normal morphological structure was preserved in the control group. In the vehicle group, the histological appearance was slightly impaired compared to the control group. In the CLP group, vascular congestion and intense hemorrhage areas were detected. In particular, the number of primordial and primary follicles decreased. In the curcumin-treated groups, the congestion decreased significantly and hemorrhage was minimal. The number of follicles also increased significantly in these groups. Immunohistochemically, it was determined that the immunoreactivity of the endoplasmic reticulum (ER) stress marker GRP78 was increased dramatically in the CLP groups. With curcumin administration, the expression of GRP78 was decreased. When the biochemical parameters were evaluated, it was determined that CRP levels increased significantly in the CLP group.

Conclusion: Our findings showed that curcumin significantly reduced sepsis-related ER stress in the ovaries when given both before and after sepsis and prevented cellular damage. These findings support that curcumin can be used as a potential protective and therapeutic agent in the treatment of ovarian damage as a result of sepsis.

Key Words: Endoplasmic reticulum stress, curcumin, ovary, rat, sepsis.

Poster Presentation

ANTIOXIDANT CAPACITY OF THYMOQUINONE AND CARVACROL AGAINST THE MOLECULAR AND IMMUNOHISTOCHEMICAL STUDIES OF CADMIUM TOXICITY İN THE LIVER TISSUE OF RAT

GÖZDE ÖĞÜTÇÜ[1] | NADİRE KIYAK[1] | GÜLTEN TUNCEL DEREBOYLU[2] | ERBLİNA NİKSHİQİ[3] | FERDA TOPAL ÇELİKKAN[4] | SEVDA MÜFTÜOĞLU[3] | AYSEL KÜKNER[1]

[1]Yakın Doğu Üniversitesi Tıp Fakültesi Histoloji Ve Embriyoloji Anabilim Dalı | [2]Yakın Doğu Üniversitesi Tıp Fakültesi Tıbbi Genetik Anabilim Dalı | [3]Hacettepe Üniversitesi Tıp Fakültesi Histoloji Ve Embriyoloji Anabilim Dalı | [4]Ankara Üniversitesi Tıp Fakültesi Histoloji Ve Embriyoloji Anabilim Dalı gozde.ogutcu@neu.edu.tr

Abstract

Introduction: Cadmium (Cd) is a toxic element and can cause damage to various organs. The liver and kidney are the main target organs. Thymoquinone and carvacrol has various pharmacological effects such as antioxidant, anti-inflammatory and antiproliferative.

Aim: This study aimed to investigate the effects of thymoquinone and carvacrol(Car) against cadmium-induced toxicity in liver tissues of rats.There are few studies in literature examining the protective effects of carvacrol and thymoquinone against cadmium-induced toxicity in the liver.

Material and Methods: Total 42 male Wistar albino rats were used.Control, DMSO, cadmium-treated(3.5 mg/kg by subcutane),carvacrol-Cd treated, thymoquinone- Cd treated, carvacrol, and thymoquinone groups were formed. Carvacrol administered at 50 mg/kg, and thymoquinone at 5 mg/kg by gavage. On the liver sections caspase-3,TNF-a, IL-6, and NF-kB immunostainings were carried out. Also sections of liver tissue were evaluated by electron microscopy. Serum aspartate aminotransferase(AST), alanine aminotransferase(ALT), and triglyceride, oxidative stress parameters, GPx and MDA, were evaluated.*Tnf-a, Nfkb1, IL6, mTor* and *Casp3* mRNA gene expression levels were examined using RT-PCR. The obtained data was statistically analyzed using GraphPad Prism software.

Results:Cadmium administration caused increase in serum AST, ALT, and Triglyceride levels. Cd+Car and Cd+Thymoquinone group showed significant reduction in ALT and Triglyceride when compared to cadmium group.In cadmium group,levels of MDA increased significantly and GPX1 levels decrease when compared to control group. GPX1 activities increased in Cd+Carvacrol and Cd+Thymoquinone groups.NF-kB, caspase-3, TNF-a and IL-6 immunostained surface area increased in cadmium compared to the Control group. Cells stained with these antibodies decreased in the Cd-Car and Cd+Thymoquinone groups. Cd groups showed a significant increase in *Tnf-a* and *Mtor* expressions, indicating that cadmium exposure upregulated this pro-inflammatory gene.Comparing Cd to Cd+Car groups,carvacrol treatments reduced *Tnf-a* expression. In Cd+Thymoquinone and Cd+Car groups, both treatments reduced*, Nfkb1, IL6,mTor and Casp3* expressions compared to cadmium alone. In the electron microscopic evaluation, degenaration of mitochondrial cristae, enlarged granular endoplasmic reticulum cisternae(GER),and markedly increased autophagic vacuole structures are observed in cadmium group. Small number of autophagic vacuoles and decreased dilatation of GER are seen in Cd+Thymoquinone and Cd+Car groups.

Conclusion:The study results indicate that carvacrol and thymoquinone alleviate the toxic effects induced by cadmium. However, further research in the literature is needed to support these findings, and it observed that the doses and durations of the administered compounds should be increased and experiments repeated to confirm their efficacy.

Poster Presentation

HISTOLOGICAL INVESTIGATION OF THE EFFECT OF QUERCETIN ON TESTICULAR DAMAGE CAUSED BY METHOTREXATE

BURCU BARAN[1] | HİLAL KOÇDOR[2] | ARZU YILDIRIM[2] | ASLI ÇELİK[3] | MEHMET ALİ KOÇDOR[4] | SEDA ÖZBAL[1]

[1]Department Of Histology And Embryology, School Of Medicine, Dokuz Eylul University Inciralti, 35340, Izmir, Turkey. | [2]Institute Of Oncology, Dokuz Eylül University, School Of Medicine, Inciralti, 35340, Izmir, Turkey. | [3]Department Of Laboratory Animal Science, Health Sciences Institute, Dokuz Eylül University, Inciralti, 35340, Izmir, Turkey. | [4]Department Of Surgery, Breast And Endocrine Surgery Unit, Dokuz Eylul University, 35340 Inciralti, Izmir, Turkey | seda.ozbal@deu.edu.tr

Abstract

Introduction: Methotrexate (MTX), folic acid antagonist, is an immunosuppressive and cytotoxic chemotherapeutic agent. However, it has toxic effects on tissues. Its tissue damage is known to be associated with oxidative stress. ROS increase causes cell damage and apoptosis. Quercetin (QE) is a free radical scavenger and a biological antioxidant.

Aim: This study aimed to investigate the effectiveness QE, a powerful antioxidant, on MTX-induced testicular toxicity.

Materials-Methods: 35 Wistar-albino male rats male rats were used. Rats were randomly divided into 5 groups: control, sham, QE, MTX and MTX+QE groups. MTX was administered single dose 20 mg/kg i.p. on day 1. QE was given by oral gavage 50 mg\kg for 9 days, 30 minutes before MTX administration. The subjects were sacrificed on 10th day. Testicular cell damage was evaluated with Hematoxylin-Eosin, Periodic Acid Schiff, Masson Trichrome staining, Johnsen's score and histomorphometric measurements. Apoptosis was evaluated by TUNEL and active caspase-3 immunostaining. Additionally, Occludin and ZO-1 immunohistochemistry was performed. Total Antioxidant Level (TAS), Total Oxidant Level (TOS) and Superoxide Dismutase (SOD) levels were measured in testicular tissues and serum.

Results: Histological evaluation showed QE administration reduced testicular cell damage. TUNEL, caspase-3, occludin and ZO-1 positive cell numbers were decreased in the seminiferous tubules compared to the control group. In biochemical analyzes, when TAS, TOS and SOD levels were examined in tissue and serum, it was determined that QE helped tissue stabilization by providing free radical balance.

Conclusions: It was concluded that QE application reduced testicular tissue damage caused by MTX with its suppressive effect on oxidative stress and apoptosis. Therefore, QE could be a potentially useful agent in the treatment of MTX-induced testicular injury.

This study was supported by TÜBİTAK 1002-B Emergency Support Module (122S966).

Keywords: Quercetin, Methotrexate, Testis, Oxidative stress, Apoptosis

Poster Presentation

INVESTIGATION OF THE EFFECTS OF FISETIN AND PIRFENIDONE ON CARDIAC TISSUE IN BLEOMYCIN-INDUCED IDIOPATHIC PULMONARY FIBROSIS MODEL IN RATS

AYŞEGÜL BURÇİN YILDIRIM[1] | ŞERİFE KÜÇÜKHÜYÜK[1] | MATTHİAS W. AMREİN[2] | MEHMET GÖL[3] | LEYLA ÇİMEN[4]

[1]Gaziantep Islam Science And Technology University, Faculty Of Medicine, Department Of Histology-Embryology | [2]University Of Calgary, Faculty Of Medicine, Departments Of Cell Biology & Anatomy Cell Biology | [3]Gaziantep Islam Science And Technology University Faculty Of Medicine, Department Of Physiology | [4]Gaziantep Islam Science And Technology University Faculty Of Medicine, Department Of Medical Biochemistry

aysegulburcin@gmail.com

Abstract

Introduction: Bleomycin (BLM), an anti-carcinogenic drug used in chemotherapy, has side effects such as pulmonary toxicity and cardiotoxicity(1). Fisetin (FST) is a flavonol found in many plant fruits and vegetables(2). Pirfenidone(PFD) is an antifibrotic agent used in the treatment of pulmonary fibrosis(PF).

Objective: In our study, we aim to elucidate the mechanism of cardiac damage caused by PF, which is the most important complication especially for chemotherapy patients receiving BLM treatment, on experimental animals. Therefore, we aim to investigate the effects of FST and PFD on on apoptotic and antioxidant mechanisms related to ER stress in the heart due to BLM-induced pulmonary fibrosis.

Materials and Methods: In this study, 40 adult male Wistar albino rats, 8-12 weeks old, weighing 250±25 g, obtained from Gaziantep University Experimental Research Center were used. 5 experimental groups were formed: Sham(Sh) Group, BLM Group, BLM+PFD Group, BLM+FST Group, BLM+PFD+FST Group. Hematoxylin-eosin staining was performed on the heart tissues. Gadd153 (growth arrest and DNA damage-inducible gene 153) and caspase-3 immunohistochemical staining were performed using the avidin-biotin-peroxidase method. Gadd153 and caspase-3 stained sections were photographed under light microscope with digital camera(3). Immunohistochemical staining was evaluated semi-quantitatively by two independent histologists. Biochemical GSH, MPO and MDA values were analyzed from heart tissue. In statistical analysis, Kruskal-Wallis H test was used for differences between groups and Mann Whitney-U test was used for pairwise comparisons between groups. $p< 0.05$ was considered significant.

Results: The bleeding and dilation in the vessels was intense in the BLM group. Vasodilation and bleeding were also present in BLM+PFD and BLM+FST groups. However, eosinophilic cardiomyocytes were present (Figure 1). Immunohistochemical analyses for caspase-3, Gadd153 were scored as Sh(-), BLM(+++), BLM+PFD(++), BLM+FST(++), BLM+PFD+FST(+) (Figure 2 and 3). There was a significant difference between the groups for GSH, MDA and MPO($p< 0.001$). In pairwise comparisons, there was no difference between BLM+FST and BLM+PFD, but the difference between the other groups was significant. Among the treatment groups, MDA and MPO levels were significantly lowest in

the BLM+PFD+FST group, and GSH was significantly highest in the BLM+PFD+FST group (Table 1).

Conclusion: Histopathological examination of heart tissue showed that the combined administration of PFD and FST resulted in greater improvements than either treatment alone. At the same time, when the proteins Gadd153 and caspase-3, which are likely to be effective in ER stress-induced apoptosis, were evaluated immunohistochemically, it was observed that PFD and FST were more effective when given together. In terms of antioxidant parameters, PFD and FST showed similar effects, but were more effective when given together.

Poster Presentation

PROTECTIVE EFFECTS OF CARVACROL IN MIMIC IN VITRO ENDOTHELIAL INFLAMMATION MODEL

NADİRE KIYAK[1] | EDA BECER[2] | HAFİZE SEDA VATANSEVER[3] | AYSEL KÜKNER[1]

[1]Near East University, Faculty Of Medicine, Department Of Histology And Embryology, Nicosia, Cyprus. | [2]Eastern Mediterranean University, Department Of Biochemistry, Famagusta, Cyprus. | [3]Manisa Celal Bayar University, Faculty Of Medicine, Department Of Histology And Embryology, Manisa, Türkiye.
nadire.1993@gmail.com

Abstract

Introduction: The endothelium is an important, widely distributed organ that maintains tissue homeostasis by producing numerous vasoactive molecules in the human body. These molecules play a key role in regulating vascular tone, thrombosis, smooth muscle proliferation, cellular adhesion, and vascular inflammation. In particular, endothelial cells secrete these molecules in response to pathogens. Viral infections can cause significant damage to endothelial cells. Studies on natural compounds of plant origin support the protective effects of natural compounds in various diseases. Carvacrol (2-methyl-5-(1-methylethyl)-phenol) is one of the mono-terpenoid molecules found in essential oils with therapeutic benefits due to its antiviral, antioxidant, and anti-inflammatory properties.

Objective: The roles of carvacrol against hyperinflammatory responses and its mechanisms in viral infections are not clear. In this study, we aimed to establish a LPS (lipopolysaccharide) induced mimic in vitro endothelial inflammation model and evaluate the protective and anti-inflammatory effects of carvacrol in viral infections.

Materials and Methods: ECV304 endothelial cell line was cultured at 37°C in a humidified atmosphere with 5% CO2. Cells were cultured in M199 growth medium containing 15 mM HEPES and 10% FBS. Cell viability and cytotoxicity effects of carvacrol were analyzed via MTT (3-(4,5-dimethylthiazol-2yl)-2,5-diphenyl tetrazolium bromide) assay on ECV304 cells. ECV304 cells were incubated with different concentrations of carvacrol (10, 20, 50, 100, and 150 µg/ml) for 48, 72, and 96 hours. To create an in vitro inflammation model, ECV304 cells were cultured with 50 and 200 µg/ml concentrations of LPS isolated from E. coli for 48 and 96 hours. TNF-α and IL-8 levels in the culture medium were measured using the ELISA test. Anti-inflammatory and protective effects of carvacrol were determined by immunocytochemistry using antibodies against Ki 67, endothelin 1, iNOS, eNOS, caspase 1, and caspase 3.

Results: After MTT analysis, it was observed that the dose of 10 µg/ml and 72 hours of carvacrol treatment in ECV304 cells were similar to the control group. According to ELISA results, it was concluded that 48 hours of incubation and 50 µg/mL LPS application were appropriate for the in vitro inflammation model. After carvacrol application, the morphology of both ECV304 and LPS-induced ECV304 cells was similar. Endothelin 1 and iNOS immunoreactivities significantly decreased in carvacrol-treated in vitro inflammation model cells ($p<0.05$). Furthermore, carvacrol reduced the activation of inflammation protein markers in ECV304 cells.

Conclusion: Our findings suggested that carvacrol can be used as a natural protective agent for endothelial dysfunction resulting from inflammatory processes associated with viral

infection. Furthermore, our results are preliminary data for in vitro and in vivo experimental models.

Keywords: Carvacrol, ECV304, inflammation

Poster Presentation

THE HISTOLOGIC EFFECTS OF EARLY ADMINISTRATION OF EQUINE HYPERIMMUNE SERUM ON THE TRACHEA OF K18-HACE2 MICE EXPOSED TO SARS-COV-2

ENGİN ALP ÖNEN[1] | FATMA BEYZA SAĞ[2] | ELİF KERVANCIOĞLU DEMİRCİ[2]

[1]Kocak Pharmaceutical Company, Biotechnology And Vaccine R&D, Tekirdag, Turkey | [2]Histology And Embryology Department, Istanbul Faculty Of Medicine, Istanbul University, Istanbul, Turkey
beyzasag@istanbul.edu.tr

Abstract

Introductıon: SARS-CoV-2 infection significantly impacts the upper airways. Prompt initiation of treatment targeting this region may aid in prognosis assessment. With the emergence of new viral variants each year, there is an increasing need for accessible and producible treatment options. Equine hyperimmune serum presents a viable alternative due to its high levels of neutralizing antibodies, which can effectively neutralize the virus upon entry into the body.

Objectıves: This study investigated the effects of equine hyperimmune serum on the trachea of SARS-CoV-2-infected K18-hACE2 transgenic mice, which exhibit severe disease analogous to that in humans due to their human ACE2 receptor.

Materıals & Methods: Vero cells were utilized for virus replication. After inactivation, purification, and sterile filtration, the final antigen was prepared. Equines were immunized with four doses of the inactivated viral antigen, administered at one-week intervals. On the 48th day, serum was collected, purified, and filtered. Following microneutralization assays and antibody titer assessments, the equine hyperimmune serum was produced. Four groups of K18-hACE2 transgenic mice were established: Control, Equine Hyperimmune Serum, SARS-CoV-2, and SARS-CoV-2 + Equine Hyperimmune Serum. After infecting the mice with SARS-CoV-2, the hyperimmune serum was administered three times at one-day intervals. A detailed analysis of the trachea was performed, with inflammation scores assigned and viral damage described according to established literature through microscopic examination.

Results: The SARS-CoV-2 group exhibited epithelial damage, cilia loss, detached basal membrane, and inflammatory cell infiltration. The tracheal lumen contained exudate, and desquamated cells. The epithelium of the SARS-CoV-2 + Equine Hyperimmune Serum group was preserved. Minimal inflammation was observed. The Control and Equine Hyperimmune Serum groups displayed normal tracheal morphology.

Conclusions: Equine hyperimmune serum offers significant advantages, including the capability for large-scale production and effectiveness against emerging viral variants. In this study, we demonstrated that the serum protects the tracheal epithelium and reduces inflammation due to its neutralizing antibodies. However, since the serum was administered during the first week of infection, its protective effect on the epithelium might be diminished if administered later, due to the time required for epithelial healing. Nevertheless, the serum would still help alleviate inflammation-related damage. Thus, early treatment is essential for achieving optimal efficacy.

Keywords: COVID-19, antiserum, horse, airway, neutralizing antibody

Poster Presentation

IN VITRO INVESTIGATION OF THE EFFECTS OF HYPOTHALAMIC NEUROPEPTIDE SPEXIN ON HUMAN GLIOBLASTOMA CELLS

CEREN OY | SEDA IŞIKLAR | SEMA SERTER KOÇOĞLU | ÖZHAN EYİGÖR | FATMA ZEHRA MİNBAY

Bursa Uludağ University, Faculty Of Medicine, Department Of Histology And Embryology, Bursa, Turkey
cerenoy@uludag.edu.tr

Abstract

Introduction: Glioblastoma (GBM) is the most common malignant primary brain tumor in adults. Increasing data indicate that the hallmarks of cancer, as in glioblastoma, arise from disturbances of cellular energy metabolism. Spexin neuropeptide is expressed in the central nervous system in the brain, including the hypothalamus. Studies have shown that spexin, which performs its biological effects through galanin receptors, regulates adipogenesis and processes associated with cellular energy metabolism such as and lipolysis, lipogenesis, and glucose uptake. Awareness of the role of many peptides and neuropeptides as well as the expression of their receptors in cancer development and tumor progression has increased significantly in recent years. The galanin signaling cascade has been shown to be involved in several cancer types.

Objective: In this study, it was aimed to determine the antitumoral effects of energy metabolism-related spexin neropeptide on U373 MG human glioblastoma cells.

Material-Method: Doses of spexin in the range of 1nM-1µM were applied to human glioblastoma (U373MG) cells for 24, 48 and 72 hours. Then, the effects of the spexin on cell viability were determined by CCK-8 assay. After the viability test, the effects of 1 µM spexin peptide on cell migration, colony formation and cell proliferation were investigated by wound healing, colony formation test and Ki-67 immunofluorescence labelling method, respectively. Bax, bcl-2, cleaved caspase 3 and 9, P53, MMP2, MMP19, ATG-5, beclin-1 expression levels were determined by western blot method to evaluate the effects on apoptosis, invasion and autophagy pathway.

Results and Conclusion: It was shown that low doses of spexin had different effects on glioblastoma cell viability. It was determined that 1 µM spexin did not effect colony formation and wound closure in glioblastoma cells. Spexin was shown to induce apoptosis by increasing the expression of Bax, cleaved caspase 3, 9 and autophagy by increasing the expression of beclin 1. In addition, spexin increased the expression of tumor suppressor p53 and decreased the expression of MMP19 involved in invasion. There was a significant decrease in cell proliferation in the spexin group ($P<0.0001$). In this study, it was shown that spexin activated tumor suppressor p53 in U373 MG cells and triggered various pathways such as apoptosis and autophagy, and thus may have reduced cell invasion and proliferation.

Our results suggest that spexin may be an effective anticarcinogenic agent on U373 MG glioblastoma cells. However, these results need to be supported by further studies.
*This study supported by Bursa Uludağ University Scientific Research Project Coordination Unit (TGA-2022-1055).

Poster Presentation

CONFOCAL ANALYSIS REVEALS LACK OF GLUR2 OR GLUR7 EXPRESSION IN MCH AND GABABR NEURONS WITHIN THE LATERAL HYPOTHALAMIC AREA

BİLGE ARICAN | *K. ZÜLAL HALK* | *TALHA YASİN DURDU* | *GONCA TOPAL* | *DUYGU GÖK YURTSEVEN* | *ZEHRA MİNBAY* | *ÖZHAN EYİGÖR*

Bursa Uludag University, Faculty Of Medicine, Department Of Histology And Embryology, Bursa, Turkiye
bilgearican@gmail.com

Abstract

Introduction: Melanin-concentrating hormone (MCH) is a cyclic 19-amino acid neuropeptide encoded by Pmch gene. Nearly all of the MCH-expressing neurons are located in Zona incerta (ZI), Perifornical area (PFx) and Lateral hypothalamic area LHA where implicated in regulation of crucial functions such as energy homeostasis, reproduction and stress responses. Most of the MCH-containing neurons are expressing ionotropic GABAARs or metabotropic GABABRs. In addition, MCH neurons are known to express ionotropic glutamate receptors. However, specific subtypes of ionotropic glutamate receptors are still to be defined.
Objective: In this study, in order to determine a triple colocalization we investigated the existence of AMPA subtype GluR2 or kainate receptor (KAR) subtype GluR7 on both MCH- and GABABR-expressing neurons within the LHA.
Materials and Methods: 60-90-day old male Sprague-Dawley rats were used in this study. Rats were fed with standard rat chow and housed on a 12-12 h light-dark cycle at room temperature. Any drugs or manipulations were not been applied on these rats before transcardial perfusion. Following by transcardial perfusion brains were removed and free-floating sections were collected. Immunohistochemistry was performed using 3-antibody cocktail; MCH, GABABR and GluR2/GluR7 followed by DyLight-, Texas Red- and FITC-conjugated secondary antibodies, respectively. Labelled sections were captured on Zeiss LSM 900 with Airyscan confocal microscope and analysed on Zeiss ZEN Lite 3.10 software.
Results: Confocal analysis reveals that none of the GABABR-expressing MCH neurons express GluR2 and GluR7 within the LHA. Furthermore, none of the MCH neurons, even not expressing GABABRs does not expressing any of this ionotropic glutamate receptor subtypes within the LHA.
Conclusions: There are a few evidences to existence of ionotropic glutamate receptors on MCH-expressing neurons. In many of the ionotropic glutamate receptor subtypes, AMPA subtype GluR2 and KAR subtype GluR7 are not expressed in MCH neurons whether expressing GABABRs. In conclusion, specific glutamate receptor subtypes co-expressing with GABA receptors in MCH neurons are still to be uncovered. Further analyses with other glutamate receptor subunits including the NMDA receptor subtypes are underway in our laboratory.

Keywords: MCH, GABABR, GluR2, GluR7, immunohistochemistry.
This study was supported by B. U. U. Scientific Research Projects Unit (Project number: TAY-2022-773)

Poster Presentation

EFFECTS OF PROPHYLACTIC VITAMIN D APPLICATION ON NEURONAL ACTIVATION AND BEHAVIORAL HYPERACTIVITY IN MICE EXPOSED TO SEVOFLURANE ON POSTNATAL DAY 10

MUHAMMET ÜNVERDİ | FERİDE KARACAER | UFUK ÖZGÜ METE | SAMET KARA | DİLEK ŞAKER | KÜBRA AKILLIOĞLU | TUĞÇE AĞAR GÜLERYÜZ

Çukurova University Faculty Of Medicine Department Of Anesthesia And Reanimation
tugce-2400@hotmail.com

Abstract

Introduction: Sevoflurane is the most commonly used inhalational anesthetic in pediatric patients, and it has been demonstrated that exposure to anesthetics during neurodevelopmental periods can lead to neuroinflammation and neuronal apoptosis. Vitamin D is known to be a regulator in various physiological pathways including brain development, inflammation, neurological functions, cell cycle control, immunomodulation, and apoptosis.
Objective: This study investigated the effects of prophylactic Vitamin D (Vit D) on behavioral hyperactivity, neuronal activation, neuroinflammation, and neuroapoptosis in mice exposed to sevoflurane on postnatal day 10.
Method: Twenty-eight Swiss albino mice were randomly divided into four groups: Vitamin D group (Group D), control group (Group K), sevoflurane group (Group S), and Vitamin D+sevoflurane group (Group SD). Mice in Groups D and SD received daily intraperitoneal injections of 5 µg/kg calcitriol from postnatal day 2 to 10, while mice in Groups K and S received saline injections. On postnatal day 10, mice in Groups S and SD were placed in an anesthesia chamber (35x15x15 cm) for 5 minutes to acclimate to the environment, and their behaviors were recorded. Mice in Groups S and SD were exposed to 2% sevoflurane in 98% O2 for 10 minutes with a flow rate of 2 L/min. Mice in Groups K and D received 100% O2. After exposure, all mice were allowed to recover in a chamber for 40 minutes. Behavioral activities of each mouse were recorded using a camera. Brain sections of the hippocampus and prefrontal cortex from six mice in each group were examined using immunohistochemistry (IH) and electron microscopy (EM). IH was used to evaluate the expression of Interleukin-6 (IL-6), Brain-Derived Neurotrophic Factor (BDNF), Tumor Necrosis Factor-α (TNF-α), c-Fos, B-Cell
Lymphoma 2 (Bcl-2), Bcl-2 Associated X Protein (Bax), and Oligodendrocyte Transcription Factor 2 (Olig2).
Results: IH analysis revealed that in Group S, the expression of Bax, IL-6, TNF- α, and c-Fos in prefrontal cortex and hippocampus tissues was significantly increased, while the expression of Bcl-2, Olig2, and BDNF was significantly decreased compared to Group SD. EM images supported these findings. Behavioral hyperactivity scoring indicated that Vitamin D reduced behavioral activity scores when comparing Group SD to Group S.
Conclusion: Our study demonstrated that prophylactic vit D treatment in mice exposed to sevoflurane on the 10th postnatal day significantly reduced the behavioral activity score during the recovery phase. Additionally, it was immunohistochemically shown that Vit D could prevent neuroapoptosis and neuroinflammation caused by a 10-minute single exposure to sevoflurane in the developing brain.

Poster Presentation

INVESTIGATION OF THE AQP5 MOLECULE EXPRESSION IN THE LENSES OF DIABETIC RATS

FİKRET GEVREK | ASİYE YANCI | SEMİR GÜL

Department Of Histology And Embryology, Faculty Of Medicine, Tokat Gaziosmanpaşa University, Tokat, Turkiye, asiye.yanci@gop.edu.tr

Abstract

Introduction: Diabetes mellitus (DM) is a metabolic disease marked by hyperglycemia due to insulin resistance, insufficient insulin secretion, or excessive glucagon secretion. It leads to structural and physiological changes in eye tissues. The lens, responsible for focus and light adaptation, is an avascular spheroid structure of specialized epithelial cells within a thick collagen capsule. Aquaporins (AQPs), membrane proteins regulating water flow, are increasingly recognized for their role in conditions like diabetes, though their non-canonical functions are still under early research.

Objective: Our aim in this study is to analyze the expression of aquaporin molecules in the lenses of diabetic rats to evaluate their possible roles in diabetes mellitus and to contribute to research on the treatment and mechanism of this disease.

Methods: This study was conducted on 14 adult male Wistar albino rats (150-250 g), divided into two groups: 1) Control and 2) Diabetes Model. Type II diabetes was induced in the diabetes group by intraperitoneal injection of streptozocin (STZ) (150 mg/kg), while no treatment was given to the control group. Rats were fasted 24 hours before and on the 10th day after STZ administration, and fasting blood glucose levels were measured. Rats with levels ≥250 mg/dL were considered diabetic. After the experiment, rats were anesthetized, eye tissues were collected, and sacrificed. AQP5 expression in the lens was analyzed using immunohistochemical and immunofluorescence methods. Immunostaining intensities were converted to H-score values for statistical analysis.

Results: Blood glucose levels in the STZ-administered diabetes model rats were significantly increased (≥250 mg/dL) compared to the control group. After immunohistochemical and immunofluorescence analyses, AQP-5 immunostaining intensity H-score values in the experimental diabetes induced group were decreased in both the lens epithelium and lens fiber cells compared to the control. However, this decrease was more noticeable in the lens epithelium cells ($p = 0.016$).

Conclusions: Our current findings suggest that diabetes may cause a decrease in AQP-5 molecule immune expression in the lens organ of the eye. It would be more appropriate to make a definitive decision after high-level studies support repeated studies.

Keywords: Aquaporin, Diabetes, Immune Expression, Lens

Poster Presentation

MORINGA OLEIFERA AMELIORATES VALPROATE INDUCED PANCREAS DAMAGE BY INHIBITING THE INTERACTION VIA HISTOCHEMICAL AND BIOCHEMICAL ALTERATIONS

PINAR KOROGLU[1] | EDA DAGSUYU[2] | UMAR FARUK MAGAJİ[3] | OZLEM SACAN[2] | NIHAL OMUR BULAN[4] | REFİYE YANARDAG[2]

[1]Halic University, Faculty Of Medicine, Department Of Histology And Embryology, Istanbul, Türkiye | [2]Istanbul University-Cerrahpaşa, Faculty Of Engineering, Department Of Chemistry, Avcilar, Istanbul, Türkiye. |[3] Federal University Birnin Kebbi, Department Of Biochemistry And Molecular Biology, Birnin Kebbi, Kebbi State, Nigeria | [4]Istanbul University, Faculty Of Science, Department Of Biology, Vezneciler, Istanbul, Türkiye
pinarkoroglu@halic.edu.tr

Abstract

Introduction: Sodium valproate is the sodium salt of valproic acid (VPA) and is an anticonvulsant used in the treatment of epilepsy, panic attacks, anxiety disorder, posttraumatic stress disorder, migraine and bipolar disorder, as well as other psychiatric conditions. In general, almost all antiepileptic drugs are potentially teratogens. It is also known that they cause direct damage to many tissues with toxic effects. Today, phytochemicals are one of the best options, especially in the treatment of diseases. Moringa oleifera is a plant that grows in the tropics and known to have many pharmacological and phytochemical properties. These properties include antiproliferation, hepatoprotective, antiinflammatory, antiatherosclerotic, DNA damage protective, antiperoxidative and cardioprotective roles.

Aim: In this study, it was aimed to show the protective effects of moringa extract on oxidative pancreas damage caused by sodium valproate, which is widely used in the clinic, by using histopathological and biochemical methods.

Material methods: In our study, 10 week old Sprague Dawley female rats were divided into 4 groups. Control, Moringa (M), VPA, VPA+M. 500 mg/kg VPA, 300 mg/kg M and physiological saline were administered to the groups. The rats were sacrificed on the 16 th day. In addition to light microscopic examinations, biochemical parameters such as total antioxidant status, total oxidant status, reactive oxygen species were also examined in the pancreas tissues taken.

Results: The histopathological and biochemical findings obtained as a result of our study showed that the damage in the pancreas increased in the VPA group, but it was found that these damages decreased in the M group given for treatment. Similar results were found in the control group in the VPA+M group.

Conclusion: According to the results obtained from our study, it was concluded that the M extract had a protective and therapeutic effect against VPA induced pancreas damage. Demonstrating the ameliorative effect of M extract in pancreas damage caused by VPA will contribute to the treatment of epilepsy.

Keywords: Moringa, Sodium Valproate, Pancreas, Oxidative stress, Microscopy, Phytomedicine

Poster Presentation

EVALUATION OF THE RELATIONSHIP OF BLOOD LIPID PROFILE WITH SEMEN QUALITY AND ICSI PARAMETERS IN IDIOPATHIC MALE INFERTILITY: A RETROSPECTIVE STUDY

DERYA ADIGÜZEL[1] | GÜLNUR TAKE KAPLANOĞLU[1] | İSMAİL GÜLER[2] | ESRA KARABAY[3] | GÖKÇE NUR ARIK EROL[1]

[1]Gazi Üniversitesi Histoloji Ve Embriyoloji Anabilim Dalı, Ankara, Türkiye | [2]Gazi Üniversitesi Kadın Hastalıkları Ve Doğum Anabilim Dalı, Ankara, Türkiye, | [3]Gazi Üniversitesi Yardımcı Üreme Teknikleri Laboratuvar Sorumlusu, Ankara, Türkiye,
dr.deryaadiguzel@gmail.com

Abstract

Introduction: Idiopathic male infertility occurs in 30-40% of infertile men and the cause of reduced semen quality is unknown. The Longitudinal Investigation of Fertility and the Environment (LIFE) study emphasised the importance of cholesterol and lipid homeostasis for male fertility by showing that serum lipid levels can affect semen parameters, especially sperm head morphology. The role of cholesterol in the post-testicular alteration of sperm plasma membrane composition and dynamics is essential for fertility; however, the effect of high cholesterol and other dyslipidaemias on fertility is still to be clarified.

Objective: Since cholesterol is the main source of steroidogenesis and plays an important role in spermatogenesis, a potential link between serum lipids and fertility may be possible. For this purpose, we aimed to investigate the relationship between lipid profiles and semen quality and ICSI (intracytoplasmic sperm injection) parameters in patients admitted to Assisted Reproductive Techniques (ART) for idiopathic male infertility.

Material and Method: The lipid profile values of 121 patients who were referred to ART for idiopathic male infertility in the last 5 years were retrospectively analysed within 6 months before ICSI and 36 patients who met the criteria were included in the study. Eight of the patients had undergone TESE (testicular sperm extraction) operation due to azoospermia and a total of 11 patients had morphology examination before ICSI. The relationship between blood lipid profiles (LDL, VLDL, HDL, Total (T.) Cholesterol, Triglyceride values) and semen parameters (total sperm count, motility and morphology) and ICSI parameters (Fertilisation Rate, Good quality embryo rate) were analysed by Spearman correlation test.

Results: The median age and body mass index (BMI) of the patients were 31.5 and 28.9, respectively. The relationship between lipid profiles of the patients and ICSI parameters is shown in Table 1. The relationship between lipid profiles and sperm morphology percentages of patients is shown in Table 2. The relationship between lipid profiles of the patients and sperm motility percentage is shown in Table 3. There was no significant correlation between blood lipid profiles and ICSI parameters ($p>0.05$). There was a strong negative correlation between VLDL and acrosome anomaly. There was no significant correlation between lipid parameters and other sperm morphological findings ($p>0.05$). There was also no significant correlation between lipid profiles and sperm concentration and motility percentages ($p>0.05$).

Concluison: In our study, it was shown that VLDL carrying substances such as cholesterol and vitamin E was negatively correlated with acrosome anomaly.

Poster Presentation

INVESTIGATION OF THE EFFECT OF NESFATIN-1 PEPTIDE ON CELLULAR AND MOLECULAR MECHANISMS DISRUPTED IN NEONATAL HYPEROXIC BRAIN INJURY

KIYMET ZÜLAL HALK | CEREN OY | BELİZ AKÇAKOCA | ESMA GÜR | BÜLENT GÖREN | FATMA ZEHRA MİNBAY

Bursa Uludag University, Faculty Of Medicine, Department Of Histology And Embryology
zulaluygul@gmail.com

Abstract

Aim: In neonatal intensive care units, premature newborns are exposed to supraphysiological doses of oxygen required for conditions such as resuscitation, pulmonary hypertension and respiratory distress. However, this dose of oxygen damages the brain as well as many organs such as the retina, lungs and intestines. Hyperoxia has been shown to cause pathological changes in processes affecting neuronal survival such as apoptosis, oxidative stress and inflammation in neonatal animal models. Recent studies have focused on the search for neuroprotective agents aimed at reducing neuronal damage caused by hyperoxia. There are studies showing that nesfatin-1, an anorexigenic peptide, has anti-inflammatory and anti-apoptotic effects. However, there is no data in the literature yet on the role of nesfatin-1 in hyperoxic brain damage. The aim of this study was to demonstrate the mechanisms through which nesfatin-1 peptide mediates hyperoxia-induced brain damage in the developing rat brain.

Materials and Methods: 6 day old Wistar albino newborn rats were used in the study. Normoxia + SF, hyperoxia + SF, hyperoxia + nesfatin-1, normoxia + nesfatin-1 groups were established. Nesfatin-1 was administered intraperitoneally at a dose of 20 µg/kg/day to the rat pups exposed to hyperoxia for 2 or 5 days. Subsequently, changes in the expressions of autophagy, apoptosis, inflammation and oxidative stress process-specific proteins and neurotrophins in the whole brain homogenates of the rat pups were evaluated by ELISA and Western Blotting analyses.

Findings: According to our findings, autophagy (beclin-1, ATG5 and LC3A-B), apoptosis (BAX) and inflammation (IL18) proteins, whose protein levels increased after 2 days of hyperoxia, were significantly reduced by nesfatin-1 treatment. In addition, it was determined that the protein levels of important neurotrophins BDNF and GDNF decreased significantly with 5 days of hyperoxia and increased significantly after nesfatin-1 treatment. In addition, it was shown that the antioxidant enzymes SOD and GSH-Px, whose protein levels decreased after 5 days of hyperoxia, increased significantly with nesfatin-1 application.

Conclusion: It was shown that nesfatin-1 peptide reduces brain damage caused by hyperoxia and has a protective effect on the disrupted cellular and molecular mechanisms.
This study was supported by the BAP Commission of Bursa Uludag University (project no: TGA-2022-1173).

Key Words: Apoptosis, autophagy, hyperoxia, nesfatin-1, neuron protection.

Poster Presentation

ANTIPROLIFERATIVE AND ROS-INDUCING EFFECTS OF THYMUS THRACICUS VELEN. EXTRACTS' SOLVENTS ON VARIOUS CELL LINES

YASEMİN YUCEL YUCEL[1] | EBRU OZDEMİR NATH[2] | GUL IPEK GUNDOGAN[3]

[1]Department Of Biochemistry, Faculty Of Pharmacy, Altinbas University, Istanbul, Türkiye |[2] Faculty Of Pharmacy, Department Of Pharmaceutical Botany, Altınbaş University, İstanbul, Turkey |[3] Faculty Of Medicine, Department Of Histology And Embryology, Biruni University, İstanbul, Turkey
gulipekgundogan@gmail.com

Abstract

Introduction:Natural products derived from plants have long been explored for their potential therapeutic benefits, especially in cancer treatment. *Thymus thracicus Velen.*, a species from the Thrace region, has shown medicinal properties, including antioxidant and antimicrobial activities. In this study, we evaluated the antiproliferative effects of ethanol and methanol extracts of *Thymus thracicus* on several cell lines: murine fibroblast cells (L929), human umbilical vein endothelial cells (HuVeC), human hepatocellular carcinoma cells (HepG2), and human glioblastoma cells (U87MG). The study also explored the role of reactive oxygen species (ROS) in the extracts' cytotoxic effects using the DCF-DA assay to measure oxidative stress.

Objective:The primary goal of this study was to assess the antiproliferative effects of *Thymus thracicus* extracts on cancerous and non-cancerous cell lines. Additionally, the study aimed to measure ROS levels in treated cells to determine the oxidative stress induced by the extracts and their potential use as natural anticancer agents.

Material-Method:L929, HuVeC, HepG2, and U87MG cell lines were cultured in DMEM with 10% fetal bovine serum and antibiotics. Cells were treated with various concentrations of ethanol and methanol extracts of *Thymus thracicus* (0.0125–1 mg/mL) for 24, 48, and 72 hours. Cell viability was measured by the MTT assay, which indicates the metabolic activity of cells. ROS production was assessed by DCF-DA fluorescence, where fluorescence intensity correlates with intracellular ROS levels. IC50 values, the concentration required to inhibit 50% of cells, were calculated based on dose-response curves.

Results:Both ethanol and methanol extracts significantly reduced cell viability in a dose- and time-dependent manner. IC50 values for the 48-hour treatment ranged from 0.2574 mg/mL for HuVeC cells to 1.346 mg/mL for U87MG cells. The highest antiproliferative activity was observed after 72 hours. ROS production was markedly elevated in the treated cells, indicating that oxidative stress contributed to the cytotoxic effects of the extracts.

Conclusion: *Thymus thracicus* extracts exhibit strong antiproliferative effects across different cell lines, with a dose- and time-dependent inhibition of cell viability. The significant increase in ROS production suggests that the extracts may induce apoptosis via oxidative stress. These findings highlight the potential of *Thymus thracicus* as a natural source of anticancer compounds. Further studies are needed to explore the specific molecular mechanisms involved and to evaluate its therapeutic potential in cancer treatment.

Poster Presentation

CIRCADIAN RHYTHM GENE DYSREGULATION IN NAFLD TO NASH PROGRESSION: A PATIENT-BASED STUDY

ULVİYE NUR SENER[1] | İREM KUMRU[2] | MURAT KIYICI[3] | SECİL AK AKSOY[1]

[1]Department Of Medical Microbiology, Faculty Of Medicine, Bursa Uludag University | [2]Bursa Uludag University | [3]Department Of Gastroenterology, Faculty Of Medicine, Bursa Uludag University
senerulviye@gmail.com

Abstract

Background: Non-alcoholic fatty liver disease (NAFLD) is a common cause of chronic liver disease worldwide. This spectrum of liver disease ranges from simple steatosis to non-alcoholic steatohepatitis (NASH), cirrhosis and hepatocellular carcinoma (HCC). The mechanisms driving the transition from NAFLD to NASH are not yet fully understood, but in-vivo studies suggests that disruptions in circadian rhythms may play a critical role. This patients-based study aims to investigate the role of circadian rhythm genes in the progression of NAFLD to NASH.

Method: We investigated the circadian rhythm genes (PER1, PER2, CLOCK and BMAL1) levels in NAFLD (n=10) and NASH (n= 25) patients by using RT-PCR and analyzed their association with outcomes. This study was supported within the scope of TÜBİTAK 2209-A project number 1919B012302692.

Results: The expression levels of PER2, CLOCK and BMAL1 were higher in NASH tissues compared with normal liver tisses ($P<0.05$). High levels of CLOCK was associated with progression of NASH ($P<0.001$).

Conclusion: Our findings support the hypothesis that circadian rhythm disturbances may contribute to the pathogenesis of NASH and offer a new avenue for understanding the molecular mechanisms underlying this disease. Further studies are needed to explore the therapeutic potential of targeting circadian genes in NASH treatment.

Key words: NAFLD, NASH, HCC, Circadian Rhythm Genes

Poster Presentation

NEUROPEPTIDE W AMELIORATES BRAIN DAMAGE INDUCED BY CHRONIC UNPREDICTABLE STRESS IN RATS

AYÇA KARAGÖZ KÖROĞLU[1,2], MUSTAFA KUTAY KÖROĞLU[1], MERVE MERİÇ KAHRAMAN[3], FERİHA ERCAN[1], BERRAK C. YEĞEN[3], DİLEK AKAKİN[2]

1 Histology and Embryology Department, School of Medicine, Marmara University,, İstanbul, Turkiye
2 Histology and Embryology Department, School of Medicine, Istinye University, İstanbul, Turkiye
3 Physiology Department, School of Medicine, Marmara University İstanbul, Turkiye

Abstract

Introduction: Chronic stress severely affects both physiological and psychological health and causes neurological abnormalities and memory dysfunction. Neuropeptide W (NPW), defined with two (23 and 30 amino acids) molecular isoforms, has been suggested to perform neuroprotection and anti-inflammation in experimental studies.

Objective: In this study, we examined the possible neuroprotective effects of NPW in a model of chronic unpredictable stress (CUS) through morphological and biochemical analyses.

Materials and Methods: Sprague Dawley male rats were divided into five (Control, NPW, CUS, CUS+NPW, and CUS+Diazepam) groups. Stressors were randomly applied for 40 days to induce CUS and NPW (1 µg/kg) was administered to the NPW and CUS+NPW groups before each stressor was applied. Saline was administered similarly to the control group and the CUS+Diazepam group rats were administered diazepam (5 mg/kg). Behavioral tests (passive avoidance and open field tests) were performed before the rats were euthanized and blood and brain samples were obtained. Serum levels of ACTH, corticosterone, pro-inflammatory cytokines (IL-1β, IL-6 and *Tumor necrosis factor*-α, TNF-α), and anti-inflammatory cytokine IL-10 were determined by ELISA. Nuclear Factor kappa B (NF-κB) and ionized calcium-binding adaptor molecule 1 (IBA1) levels were assessed using Western blot, while mRNA expressions of IL-6, IL-10, and Nuclear Receptor Subfamily 3 Group C Member 1 (NR3C1) were determined using reverse transcriptase-quantitative real-time PCR (RT-qPCR) in the brain homogenates. The brain tissues were subjected to morphological evaluation by hematoxylin and eosin staining and immunohistochemistry for GFAP. Finally, data were analyzed statistically using One-way ANOVA and Tukey's multiple comparison tests.

Results: Compared to controls, CUS group showed increased ACTH and corticosterone levels, and pro-inflammatory cytokines in the serum samples, however, decreased anti-inflammatory cytokine levels were observed ($p<0.001$). Increased NFκB and IBA1 protein levels and IL-6, IL-10, and NR3C1 mRNA expression were observed in the CUS group rats compared to controls ($p<0.01$-$p<0.001$). Biochemical parameters were reversed with both diazepam and NPW treatments ($p<001$-$p<0.001$). Moreover, the histological evaluation revealed chronic stress-induced neurodegeneration and increase in brain GFAP immunostaining in the CUS group regarding controls, which were ameliorated with NPW administration. Behavioral tests supported the biochemical and histological findings.

Conclusion: These results indicate that NPW could exert a protective effect against stress-induced neuronal damage in chronic unpredictable stress model of rats by preventing inflammation. The study here supports neuropeptide W as a potential for the development of alternative strategies in neurological disorders resulting from chronic stress.

Key Words: Neuropeptide W, chronic stress, brain, GFAP
This study was supported by the Scientific Research Projects Unit of Marmara University (TDK-2022-10580).

Oral Presentation

EVALUATION OF POTENTIAL PROTECTIVE EFFECTS OF NEUROPEPTIDE W ON TESTICULAR DAMAGE INDUCED BY CHRONIC PSYCHOLOGICAL STRESS IN RATS

MUSTAFA KUTAY KÖROĞLU[1], AYÇA KARAGÖZ KÖROĞLU[1,2], MERVE MERİÇ KAHRAMAN[3], DİLEK AKAKIN[1], BERRAK Ç. YEĞEN[3], FERİHA ERCAN[1]

[1]Marmara University, School of Medicine, Department of Histology and Embryology, İstanbul, Türkiye
[2]İstinye University, School of Medicine, Department of Histology and Embryology, İstanbul, Türkiye
[3]Marmara University, School of Medicine, Department of Physiology, İstanbul, Türkiye

Abstract

Introduction: Chronic psychological stress can lead to cognitive dysfunction, metabolic syndrome, cardiovascular and gastrointestinal diseases, and immune system dysfunction. It also adversely affects the reproductive system, resulting in infertility. In males, chronic stress has been shown to induce testicular damage and impairement of sperm parameters. Neuropeptide W (NPW), a neuropeptide synthesized in the central nervous system and various other organs, is known for its antioxidant and anti-inflammatory properties.

Aim: The aim of this study is to evaluate the potential protective effects of NPW on chronic psychological stress-induced testicular damage.

Materials and Methods: Sprague-Dawley male rats (n=40) were used in the study. A chronic unpredictable mild stress (CUMS) model (predator sound, cat litter, flashing light, wet bedding, food deprivation, tilted bedding, and reversed light/dark cycle) was applied randomly for 40 days. Diazepam (5 mg/kg), NPW (1 µg/kg) or saline was administered before each stress session. Saline was applied to control groups. Anxiety levels induced by CUMS were assessed using the tail suspension test. Corticosterone, testosterone, luteinizing hormone (LH) and follicle-stimulating hormone (FSH) levels were measured in blood samples. Testicular morphology and epididymal sperm parameters (concentration, viability, motility, and morphology) were evaluated. The blood-testis barrier proteins claudin-11 and occludin amounts were measured by Western blotting. Gene expressions of transition protein-1 (TNP-1), claudin-11 and zonula occludens-1 (ZO-1) were evaluated using reverse transcriptase-quantitative real-time PCR (RT-PCR). Oxidative damage markers, malondialdehyde (MDA) and glutathione (GSH) levels, and the inflammatory marker myeloperoxidase (MPO) levels were measured in testicular homogenates using biochemical methods. All data were analyzed statistically using One-way ANOVA and Tukey's multiple comparison tests.

Results: CUMS increased anxiety level, decreased testosterone, LH and FSH levels, and altered sperm parameters compared to controls, indicating impaired testicular function. Histopathological analysis revealed significant testicular damage, including structural disruption of the seminiferous tubules in the CUMS group. Decrease of claudin-11 and occludin protein levels, and the down-regulated expression of TNP-1, claudin-11, and ZO-1 were observed in the CUMS group compared to control rats. Moreover, increase in MDA and MPO levels, but no changes in GSH level were observed in the CUMS group rats regarding to

controls. Similar to diazepam, NPW treatment demonstrated a protective effects against CUMS-induced testicular damage by improving all these parameters.

Conclusion: The findings of present study show that neuropeptide W prevents chronic unpredictable mild stress-induced testicular damage by inhibiting oxidative stress and regulating blood-testis barrier protein expression and improves sperm parameters.

Keywords: Chronic psychological stress, blood-testis barrier, Neuropeptide W, spermatoza
This study was supported by the Scientific Research Projects Unit of Marmara University (TDK-2022-10556)

Poster Presentation

THE IMPACT OF DYSREGULATED CIRCADIAN RHYTHM GENE EXPRESSION ON RECURRENCE AND PROGNOSIS IN HBV-MEDIATED HEPATOCELLULAR CARCINOMA FOLLOWING LIVER TRANSPLANTATION

BUSE BİRİNCİ[1] | BEYZANUR YAGCİ[2] | SECİL AK AKSOY[2] | FUAT AKSOY[3]

[1]Department Of Histology & Embryology, Faculty Of Veterinary Medicine, Bursa Uludag University | [2]Department Of Medical Biology, Faculty Of Medicine, Bursa Uludag University | [3]Department Of General Surgery, Faculty Of Medicine, Bursa Uludag University, birincibuse7@gmail.com

Abstract

Background: Liver transplantation (LT) is the best treatment option for hepatitis B virus (HBV)-mediated hepatocellular carcinoma (HCC). Nevertheless, recurrence is the most important issue after LT. The aim of the present study was to evaluate the relationship between dysregulated expression of circadian rhythm genes and the prognosis of HBV-mediated HCC cases.

Method: Formalin-fixed paraffin-embedded (FFPE) tumor samples of 50 patients diagnosed with HBV-related HCC were enrolled in this study. Circadian rhythm genes expressions were assessed using quantitative real-time polymerase chain reaction. This study was supported by the TÜBİTAK project number 1919B012303273.

Results: A total of 50 HBV-mediated HCC patients were evaluated in this study. Among circadian rhythm genes (PER1, PER2, CLOCK, BMAL1), the expression level of all genes were higher in patients with HCC compared with noncancerous liver tissues ($P<0.05$). Compared with nonrecurrent patients, the expression level of BMLA1 was 4.2-fold higher in patients with recurrence during the 5-year follow-up ($P<0.05$).

Conclusion: These findings highlight the importance of further research into the role of circadian rhythm genes in HCC progression and recurrence, which may offer new avenues for therapeutic interventions and improving post-transplant outcomes.

Key words: Circadian Rhythm Gene, HCC, Liver Transplantation

Poster Presentation

DIFFERENTIAL EXPRESSION OF BECLIN1 AND ENOS IN THE CARDIAC TISSUE OF ANATOLIAN GROUND SQUIRRELS DURING PRE-HIBERNATION AND HIBERNATION PERIODS

AHMET CABİR[1] | HARUN KARACA[2] | FEYZULLAH BEYAZ[1] | MEHMET FATİH BOZKURT[3] | MUSTAFA ÖZTOP[4] | MEHMET ÖZBEK[2]

[1]Department Of Histology And Embryology, Faculty Of Veterinary Medicine, Erciyes University, Kayseri, Turkey | [2]Department Of Histology And Embryology, Faculty Of Veterinary Medicine, Burdur Mehmet Akif Ersoy University, Burdur, Turkey | [3]Department Of Pathology, Faculty Of Veterinary Medicine, Afyon Kocatepe University, Afyon, Turkey | [4]Department Of Biology, Faculty Of Science And Art, Burdur Mehmet Akif Ersoy University, Burdur, Turkey ahmetcabirvet@gmail.com

Abstract

Background: Hibernation is an essential adaptation for the survival of numerous mammals, including Anatolian ground squirrels, as it enables them to endure extended periods of metabolic depression. The heart is essential for this adaptation, necessitating the precise regulation of cellular processes. Beclin1, which is involved in autophagy, and eNOS, which is responsible for nitric oxide production and vascular function, are vital components of the cellular homeostasis system. This study examines the differential expression of Beclin1 and eNOS in the cardiac tissue of Anatolian ground squirrels, comparing pre-hibernation and hibernation periods to reveal the physiological changes that support cardiac function during extreme conditions.

Material and Methods: All the experimental protocols on animals were carried out in accordance with the guidelines on the Care and Use of Animals by the Ethical Committee, Erciyes University and approved by Erciyes University Local Ethics Committee for Animal Experiments (HADYEK) (approved number: 15/140), Kayseri. A total of 12 male Anatolian ground squirrels (Spermophilus xanthoprymnus) were used in the study, each of which 6 animals used in prehibernation and hibernation. Streptavidin-biotin-peroxidase technique was employed to demonstrate immunoexpression of eNOS and Beclin1 in the heart.

Results: In the pre-hibernation period, eNOS expression was intense in atrial cardiomyocytes and endothelial cells, moderate in ventricular myocytes, weak in elastic arteries, and weak to moderate in beige adipose tissue. During hibernation, eNOS levels decreased, showing weak to moderate expression in atrial myocytes, very weak expression in elastic arteries and endothelial cells, and weak expression in ventricular myocytes. Similarly, Beclin1 showed weak immunoreactivity in atrial cardiomyocytes, elastic arteries, beige adipose tissue, and ventricular cardiomyocytes during pre-hibernation. In the hibernation period, Beclin1 immunoreactivity became very weak in all of these tissues, including atrial and ventricular cardiomyocytes, as well as elastic arteries.

Conclusion: The results of this study demonstrate a substantial decrease in the expression of eNOS and Beclin1 in Anatolian ground squirrels from pre-hibernation to hibernation. eNOS levels were elevated in atrial cardiomyocytes and endothelial cells during pre-hibernation, suggesting an active role in cardiovascular function. Conversely, Beclin1 expression was muted across tissues. A downregulation of autophagy and nitric oxide pathways is suggested by the significantly reduced expression of both proteins in all tissues examined during

hibernation. This decrease is likely indicative of an energy-conserving mechanism that is crucial for the sustenance of cells during the low metabolic demands of hibernation.

Keywords: Hibernation, Spermophilus xanthoprymnus, Anatolian ground squirrels, Beclin1, eNOS, heart.

Poster Presentation

EXPRESSION OF BCL2 AND BAX PROTEINS IN ANATOLIAN GROUND SQUIRREL HEARTS: A COMPARATIVE ANALYSIS BETWEEN PRE-HIBERNATION AND HIBERNATION PERIODS

HARUN KARACA[1] | YAHY ABOOD KAREEM ALESAWİ[2] | AHMET CABİR[3] | FEYZULLAH BEYAZ[3] | MEHMET FATİH BOZKURT[4] | MUSTAFA ÖZTOP[5] | MEHMET ÖZBEK[1] | EMEL ERGÜN[2]

[1]Department Of Histology And Embryology, Faculty Of Veterinary Medicine, Burdur Mehmet Akif Ersoy University, Burdur, Turkey | [2]Department Of Veterinary Histology And Embryology, Graduate School Of Health Sciences, Ankara University, Ankara, Turkey | [3]Department Of Histology And Embryology, Faculty Of Veterinary Medicine, Erciyes University, Kayseri, Turkey | [4]Department Of Pathology, Faculty Of Veterinary Medicine, Afyon Kocatepe University, Afyon, Turkey | [5]Department Of Biology, Faculty Of Science And Art, Burdur Mehmet Akif Ersoy University, Burdur, Turkey

harunkaraca@mehmetakif.edu.tr.

Abstract

Background: Anatolian ground squirrels utilize hibernation as a critical adaptation to endure severe winters by decreasing their metabolic rates. This study examines the differential expression of Bcl2 and Bax, which are critical apoptotic regulators, in the cardiac tissues of the animals during the pre-hibernation and hibernation phases. Our objective is to elucidate insights into cardiac adaptations and resilience against physiological extremes by comparing these proteins, thereby emphasizing potential protective mechanisms.

Material and Methods: All the experimental protocols on animals were carried out in accordance with the guidelines on the Care and Use of Animals by the Ethical Committee, Erciyes University and approved by Erciyes University Local Ethics Committee for Animal Experiments (HADYEK) (approved number: 15/140), Kayseri. A total of 12 male Anatolian ground squirrels (Spermophilus xanthoprymnus) were used in the study, each of which 6 animals used in prehibernation and hibernation. Streptavidin-biotin-peroxidase technique was employed to demonstrate immunoexpression of Bax and Bcl2 in the heart.

Results: During the pre-hibernation phase, cardiomyocytes displayed moderate to intense Bcl2 immunostaining, with particularly strong expression in ventricular regions. Beige adipose tissue, along with elastic artery walls and endothelial cells, also showed moderate to intense Bcl2 staining. In contrast, Bax was intensely stained in beige adipose tissue but exhibited weak immunoreactivity in cardiomyocytes and moderate expression in elastic arteries. In the hibernation phase, Bax staining remained weak in both arteries and cardiomyocytes, whereas Bcl2 showed moderate staining in atrial cardiomyocytes and arteries, and intense staining continued in ventricular cardiomyocytes.

Conclusion: The present work emphasizes the crucial significance of apoptotic control in Anatolian ground squirrels during the period of hibernation. Enhanced anti-apoptotic mechanisms are shown by increased Bcl2 and decreased Bax expression during pre-hibernation, which prepare tissues for metabolic decline. During hibernation, the presence of maintained Bcl2 and lowered Bax levels suggests a suppression of apoptosis, which is essential for preserving cellular integrity in settings of reduced physiological activity. The adaptive responses undoubtedly enhance the survival of cardiomyocytes throughout protracted periods of low metabolic activity, providing valuable understanding of how

hibernating mammals safeguard their cells from stress and damage during extended dormancy.

Keywords: Hibernation, Spermophilus xanthoprymnus, Anatolian ground squirrels, Bax, Bcl2, heart.

Poster Presentation

FABRICATION AND CHARACTERIZATION OF MSC-LOADED ALGINATE/SPIRULINA MICROSPONGE AS A TOPICAL DRUG DELIVERY SYSTEM FOR SKIN REJUVENATION

BÜŞRA ÖNCEL DUMAN[1] | UMUT EREN KARABENLİ[2] | MOHADDESEH MOKHTARİASGARABADTAPEH[2] | EYÜP ALTUN[2] | ECEM ROMA[2] | YUSUFHAN YAZIR[3]

[1]Kocaeli Sağlık Ve Teknoloji Üniversitesi, Avrupa Myo, Tıbbi Laboratuvar Teknikleri Programı | [2]Kocaeli Sağlık Ve Teknoloji Üniversitesi, Eczacılık Fakültesi | [3]Kocaeli Üniversitesi, Sağlık Bilimleri Enstitüsü, Kök Hücre Ad., Kocaeli Üniversitesi, Tıp Fakültesi, Histoloji Ve Embriyoloji Ad.
romaaec@gmail.com

Abstract

Introduction: Skin-aging is closely related to the appearance of lines and wrinkles on the face, the appearance of pores, lentigo and hyperpigmentation. Today, there are many methods that delay or treat skin-aging to some extent, including surgeries, laser treatments, creams and the like. The new approach to skin renewal treatments that fail to yield results with existing surgical or drug applications is cellular and tissue-engineering treatments. Stem cells are a newly developing science and are increasingly used in regenerative medicine. Nowadays, mesenchymal stem cell (MSC)-based cosmetic products are emerging to solve various skin changes that occur due to aging.

Aim: To design a new topical skin-targeted drug-delivery system, alginate/spirulina microsponge, to develop a stem cell-based active ingredient that treats skin wrinkles and to investigate the cytokine and protein release capacity of MSCs in its in vitro dosage form.
Material-Method: Alginate solution was prepared with water at 2% and 4% low viscous concentration and 200µg/ml spirulina powder form was added to it to provide a homogeneous mixture and biocomposite-microsponge was produced. Characterization tests were performed with swelling ratio, SEM, FTIR and rheometer analyses on the biocomposite-microsponge. Micro BCA test was applied to determine the protein release profile and loading efficiency of loaded MSCs. The effect of Alginate/Spirulina biocomposite-microsponge on MSC was analyzed by WST and LDH methods.

Results: The swelling properties of the microsponges were determined by the liquid retention capacity of the capsules in the culture medium for 14 days and the change in volume accordingly. As a result of the examination of the capsules, it was determined that the pore size they carried was 0.174-1 µm. A decrease in viscosity was observed due to increased shear stress in the material. It was determined that microsponge supports cell proliferation in the best way without showing toxic effects on MSCs

Conclusion: In this study, the synthesis and characterization of biocomposite-microsponge obtained by copolymerizing polysaccharide extract obtained from spirulina-platensis with alginate for skin tissue-engineering applications was carried out. The next goal of the study is to examine the effect of microsponge by creating a wound-healing model on fibroblast cells in vitro. If the treatment effectiveness of MSCs on cells in the in vitro experimental model is proven as a result of this study, an autologous, minimally invasive and non-pharmacological

effective method will be provided to individuals with skin wrinkles and wounds that can be treated with stem cell and tissue-engineering approaches.

Poster Presentation

THE EFFECTS OF PIOGLITAZONE ON METABOLIC SYNDROME IN KIDNEY TISSUE

ŞEYMA KİPEL[1] | GİZEM İLTER AKTAŞ[2] | HİLAL NAKKAŞ[1] | AYÇA BİLGİNOĞLU[3]

[1]Ankara Yıldırım Beyazıt Üniversitesi - Tıp Fakültesi - Histoloji Ve Embriyoloji Anabilim Dalı | [2]Yüksek İhtisas Üniversitesi- Tıp Fakültesi- Histoloji Ve Embriyoloji Anabilim Dalı | [3]Ankara Yıldırım Beyazıt Üniversitesi - Tıp Fakültesi - Biyofizik Anabilim Dalı
seymakipel@gmail.com

Abstract

Introductıon: Metabolic syndrome (MS) is a condition characterized by a combination of certain metabolic factors, including obesity, insulin resistance, high blood pressure, high triglyceride levels, and low HDL cholesterol levels. The basic pathophysiological mechanisms that occur in metabolic syndrome are inflammatory mechanisms and as a result MS damages many organs such as liver, heart, pancreas, adipose tissue and kidney and can inrease risk of developing serious health problems. Pioglitazone (PGZ), a thiazolidinedione, is an insulin-sensitizing diabetes drug. It provides effective and long-term glycemic control in patients with type 2 diabets. Also pioglitazone helps prevent serious complications of diabetes, such as kidney damage and blindness.

Aım:Studies have shown that PGZ has beneficial effects on MS. Based on this, we aimed to examine the effect of PGZ on the kidney of MS-rats.

Materıals And Methods: Three-month-old male Wistar Albino rats were used and randomly grouped in three (n=8). Control group (C) received standart diet and water. MS group received 32% sucrose (935 mM) including drinking water for 20 weeks. Pioglitazone treated MS group (MS-PGZ) received pioglitazone treatment (30 mg/kg/day, via gavage) for 2 weeks at the end of the 18th weeks of MS group. To paraffin sections hematoxylin - eosin and azan trichrome stainings were performed. Morphological structure of the tissues were evaluated and the diameters of the kidney glomerulus were measured by two histologists blind to groups.

Results And Dıscussıon:MS gave damage to kidney as an end-organ, reduced glomerular size, thickened basal membrane and fibrosis, increased interstitial area and degenerated tubules were more significant. Light microscopy data and their quantification demonstrated that PGZ-treatment prevented the reduction of glomerular area, expansion in mesangium cell size, thickening and fibrosis in glomerular basement membrane. This result was also supported by glomerular diameter measurements. Many studies have shown that PGZ improves the destructive effects of diabetes and metabolic syndrome in different tissues. This study was a fundamental study to demonstrate the effect of PGZ on MS-kidneys. Further studies will clarify the effect and mechanisms of pioglitazone on MS.

Key words: Metabolic syndrome, pioglitazon, kidney, diabet

Poster Presentation

CURCUMİN-ACTİVATED APOPTOSİS İN ENDOPLASMİC RETİCULUM STRESS-İNDUCED BRAİN TUMOUR

YELİZ BOZDEMİR DÖNMEZ[1], OĞUZHAN DOĞANLAR[2], ZEYNEP BANU DOĞANLAR[2], AYTEN BOSTANCI[1]

1 Technology Research Development Application and Research Center, Trakya University, Edirne, Turkiye,
2Faculty of Medicine, Department of Medical Biology, Trakya University, Edirne, Turkiye,
yelizdonmez@trakya.edu.tr
oguzhandoganlar@trakya.edu.tr
zdoganlar@trakya.edu.tr
aytensari@trakya.edu.tr

Abstract

Glioblastoma multiforme (GBM) is the type of the brain tumor that is associated with the extremely deadly with the most aggressive. The objective of this study to assess the pro-apoptotic effect of curcumin in ER stress induced and analyzed the anticancer mechanism of action of Curcumin against brain tumour (C6) and healty (C8) cells. Following treatment with curcumin or curcumin+tunicamycin, cell survival and IC50 value was determined using a MTT assay. Curcumin combined with tunicamycin and suppressed the proliferation of C6 in a dose-dependent manner and induced particularly apoptotic death without significantly affecting healthy C8 according to Annexin V/PI staining and AO/EB staining analyses. After treatment, effectively inhibited the proliferation of cancer cells and stimulated apoptosis in a dose and time-dependent manner as shown by the MTT and Tali Cytometer assays. Taken together, our findings suggest that Curcumin combined with tunicamycin appears to be an promising approach for effective brain tumour chemotherapy.

Keywords: ER stress, Curcumin, Glioblastoma multiforme.

Poster Presentation

INVESTIGATION OF THE APOPTOTIC EFFECT OF THE COMMERCIAL ELDERMAFILL EXO KIT ON MDA-MB-231 CELLS

TALAT YASİN ACAR[1] | BİRCAN KOLBASİ[2] | BEGUM SAHİN[2] | ILKNUR KESKİN[2]

[1]Istanbul Medipol University, Health Sciences Institute, Department Of Histology And Embryology, Istanbul, Turkiye |[2] Istanbul Medipol University, School Of Medicine, Department Of Histology And Embryology, Istanbul, Turkiye.
talat.acar@medipol.edu.tr

Abstract

Introduction: Breast cancer is one of the most common cancers affecting women worldwide and ranks among the leading causes of cancer-related mortality. Due to its tendency to metastasize to organs such as the bones, liver, lungs, and brain, it is often challenging to treat. Apoptosis, or programmed cell death, has become a key area of research, particularly in cancer, as disruptions in the balance between cell proliferation and death often result in the failure of cancer cells to undergo apoptosis. Exosomes, secreted by various cell types, reflect the physiological state of their parent cells and have been implicated in virtually all hallmarks of cancer, including sustained proliferation, genomic instability, resistance to apoptosis, and metastasis. In recent years, studies examining the role of exosomes in tumorigenesis and cancer progression have increased. Some studies have demonstrated that exosomes can exhibit both supportive and suppressive effects in cancer. The Eldermafill Exo kit contains exosomes derived from human dermal fibroblast-induced multipotent cells, and these exosomes are noted for their effects on reducing signs of aging, promoting skin regeneration, and protecting cells from apoptosis by supporting angiogenesis in damaged tissues. However, the effects of this product in individuals with undiagnosed conditions, such as breast cancer, remain unexplored.

Aim: This study aims to investigate the efficacy of the commercial Eldermafill Exo kit on the triple-negative breast cancer cell line MDA-MB-231, which is capable of maintaining dormancy for years and proliferating covertly by forming cancer stem cells.
Methods: MTT cell viability analysis was performed to investigate the effect of Eldermafill exo kit on the viability of MDA-MB-231 cells. To examine the apoptotic effects, (Caspase 3/7- Sytox) flow cytometry analysis was conducted.
Results: In MDA-MB-231 cells, the Eldermafill Exo kit significantly reduced cell viability at higher doses. Flow cytometry analysis using Caspase 3/7-Sytox staining revealed a statistically significant increase in cell death in the Eldermafill Exo-treated group compared to the control group.

Conclusion: Eldermafill Exo application reduced cell viability in MDA-MB-231 cells by inducing cell death. The decrease in cell viability was demonstrated both through MTT viability assays and flow cytometry analysis using Caspase 3/7-Sytox staining. The reduction in cell viability showed a statistically significant difference.

Keywords: Apoptosis, Caspase 3/7, Cell Viability, Exosome, Triple Negative Breast Cancer,

Poster Presentation

EVALUATION OF REGULATORY T CELLS AND EXOSOMES IN THE PLACENTAL TISSUE OF PATIENTS WITH MATERNAL HYPOTHYROIDISM

ŞEYDA DEMİR YÜKSEL

Dokuz Eylül Üniversitesi Tıp Fakültesi Histoloji Ve Embriyoloji Anabilim Dalı, ciydademir@gmail.com

Abstract

Introduction: Maternal hypothyroidism is defined as a deficiency of thyroid hormones during pregnancy and affects 4% of the population. Thyroid hormone deficiency during pregnancy influences the health of both the mother and the fetus. Thyroid hormones are crucial for the healthy development and neurodevelopment of the fetus, and their deficiency is well known to cause neurological developmental problems. These hormones reach the fetus via the placenta, and thyroid hormones play an active role in placental tissue throughout pregnancy. They are significant in the proliferation and differentiation of placental cells, and their deficiency has been shown to disrupt the anti-inflammatory environment in the placenta. The disruption of this anti-inflammatory environment leads to the impairment of maternal-fetal immune tolerance, which negatively affects maternal and fetal health by causing various pregnancy pathologies such as preterm birth, miscarriages, and preeclampsia. Maternal immune tolerance is essential for the maternal tissue's acceptance of the semi-allogeneic fetus. The establishment and maintenance of this tolerance depend on an active maternal immune tolerance state mediated by regulatory T cells (Tregs).
Treg cells are a subgroup of T cells responsible for balancing excessive immune responses and controlling autoimmunity. Tregs are characterized by CD4, CD25, and FoxP3 (Forkhead family transcription factor forkhead box p3), and a deficiency in FoxP3 expression impairs their functions. In many pregnancy-related pathologies, a reduction in Treg cell populations has been observed. It is known that the release of exosomes increases under pathological conditions. Furthermore, exosomes have been shown to influence the proliferation and differentiation of Treg cells. However, the behavior of Tregs and exosomes in the placenta under conditions of maternal hypothyroidism remains unknown.

Objective: In this study, we aimed to investigate the distribution and concentration of FoxP3+ Treg cells and exosomes in healthy and hypothyroid placentas.

Method: In human placental tissues, Treg cells and exosomes were labeled using FoxP3 and CD63 antibodies, respectively, through immunohistochemistry (IHC). The distribution of Treg cells in the decidua and exosomes in the villi was determined. For quantitative analysis, the expression levels of FoxP3 and CD63 were compared between healthy and patient groups using ELISA. Additionally, histomorphological changes in the placentas were evaluated between these two groups.

Results: IHC results showed a significant decrease in FoxP3 immunoreactivity in hypothyroid placentas compared to the control. Similarly, ELISA results supported the IHC findings.

However, no significant difference was observed in CD63 expression in either the IHC or ELISA results.

Conclusion: In light of these results, we can suggest that FoxP3+ cells are involved in the pathology of maternal hypothyroidism. Additionally, this study observed FoxP3 expression in trophoblasts within the chorionic villi, indicating that further research is needed to understand the role of FoxP3+ cells in feto-maternal tolerance in the context of maternal hypothyroidism.

Keywords: Maternal hypothyroidism, Treg, exosome, FoxP3, CD63

Poster Presentation

IMMUNOHISTOCHEMICAL DEMONSTRATION OF GLUTAMATE AND GABA RECEPTORS IN OREXIN-A NEURONS

TALHA YASİN DURDU | GONCA TOPAL | BİLGE ARICAN | KIYMET ZÜLAL HALK | DUYGU GÖK YURTSEVEN | FATMA ZEHRA MİNBAY | ÖZHAN EYİGÖR

Bursa Uludag University Institute of Health Sciences
tlhysndru@gmail.com

Abstract

Aim: The main center in the central nervous system that regulates food intake is the hypothalamus. Dozens of neurohormones that increase or decrease food intake are secreted from many nuclei located in the hypothalamus. One of these neurohormones/neuropeptides, orexin, expressed primarily by neurons localized in the lateral hypothalamus, functions as a peptide that is increased during fasting states and induces food intake. There are studies showing that both peripheral signals and central excitatory and inhibitory signals play a role in controlling the activity of orexinergic neurons. The excitatory effects of the neurotransmitter glutamate are mediated by n-methyl-d-aspartate (NMDA), alpha-amino-3-hydroxy-5-methyl-4-isoxazole propionate (AMPA), kainate and metabotropic receptors. Subfamily members of the ionotropic glutamate receptor family can form homomeric ion channels individually or heteromeric ion channels between their subunits. The neurotransmitter GABA shows its inhibitory effect by binding to ionotropic GABAA and metabotropic GABAB receptors.
This study was aimed to demonstrate the presence of glutamate receptor subunits and GABA receptor subunits that form a functional receptor channel in neurons expressing Orexin-A peptide, as well as to identify neurons that co-express both glutamatergic and GABAergic functional receptors.

Materials and Methods: Sprague Dawley male rats weighing 200-250 g (60-90 days old) were used in the study. Animals were sacrificed by perfusion fixation with 4% paraformaldehyde administered under deep anesthesia. 40 µm coronal sections were taken from the removed brains in 5 series using a vibratome device. Sections were stained with multiple immunofluorescence method and evaluated under a confocal microscope.

Results: As a result of the findings obtained from our study, it was shown that Orexin-A neurons localized in the lateral hypothalamus expressed GABA receptor subunits GABABR1 and GABABR2 and glutamate receptor subunits GRIA1 (AMPA group subunit) and GRIK5 (kainate group subunit). At the same time, it was determined that GABA and glutamate receptor subunits were co-expressed in some of the Orexin-A positive neurons.
Conclusion: Our study showed that some of the Orexin-A neurons expressed only the glutamate receptor subunits GRIA1 or GRIK5 and the GABAB receptor subunits GABABR1 or GABABR2, while others expressed receptor proteins that mediate the reception of both inhibitory and excitatory signals. It was determined for the first time in the literature that Orexin-A neurons synthesize both glutamate and GABA receptors.

Keywords: Orexin-A, GABAB, GRIA1, GRIK5, Immunohistochemistry.
This study has been supported by B.U.Ü. BAP Unit (Project number: TAY-2022-773).

Poster Presentation

ELABELA AMELIORATES ISCHEMIA/REPERFUSION- INDUCED HEPATIC DAMAGE

AYŞEGÜL BAHAR ÖZOCAK | LEYLA SEMİHA ŞEN | NUR ÖZKEÇECİ | FERİHA ERCAN | BERRAK C. YEĞEN | ALİ EMRE ATICI | CAN ERZİK | İREM PEKER EYÜPOĞLU | MERAL YÜKSEL | LEMAN ARSLAN ARITÜRK

Marmara University School Of Medicine, Department Of General Surgery, Istanbul, Türkiye
nur_ozkececi@hotmail.com

Abstract

Introduction: Hepatic ischemia/reperfusion (HIR) injury can arise following major liver surgeries or in clinical situations such as sepsis, bleeding, and trauma. A newly discovered peptide called Elabela (ELA), which is a new endogenous ligand for the G protein-coupled apelin receptor (APJ), has been shown to protect against renal and myocardial ischemia/reperfusion injury.

Aim: We aimed to evaluate possible therapeutic effects of ELA on HIR injury.

Materials and Methods: Under anesthesia, Sprague Dawley rats of both sexes (n=30) were injected subcutaneously with saline, N-Acetylcysteine (NAC;150 mg/kg) or ELA (ELA-32, 40 μg/kg) and were then induced with HIR by blocking portal vein and hepatic artery (70%) with vascular clamp for 45 minutes, and the injections were repeated at 60 and 120 minutes. Control rats had sham-surgery and were injected with saline (n=10). At the 180th min of reperfusion, hepatic blood flow was measured using laser Doppler flowmeter. Following blood flow recording, liver tissues were obtained to measure levels of malondialdehyde (MDA), antioxidant glutathione (GSH) and myeloperoxidase (MPO) activity by spectrophotometry, while luminol- and lucigenin-enhanced chemiluminescence (CL) levels were measured in the liver samples to assess formation of reactive oxygen species (ROS). General histopathological evaluation was done on hematoxylin and eosin-stained sections. Serum interleukin (IL)-6 levels were measured by ELISA. Statistical analyses were made by one-way ANOVA.

Results: In saline-treated HIR group, hepatic blood flow was significantly reduced ($p<0.001$) while treatment with ELA ($p<0.01$) or NAC ($p<0.001$) reversed blood flow back to control levels. Increased microscopic damage scores in the liver of saline-treated HIR group ($p<0.001$) were reduced by both ELA ($p<0.001$) and NAC treatments ($p<0.01$). Compared to saline-treated HIR group, hepatic MDA was reduced in ELA- or NAC-treated groups ($p<0.05$), while hepatic GSH level was elevated only by NAC ($p<0.05$). Increased hepatic MPO activity in saline-treated HIR group ($p<0.05$) was abolished in ELA- or NAC-treated groups. Elevated CL levels, showing enhanced ROS generation in liver tissues of saline-treated HIR group ($p<0.01$-0.001) were significantly reduced in ELA-treated group ($p<0.05$-0.01). IL-6 levels were increased in ELA-treated ($p<0.001$) and NAC-treated ($p<0.01$) groups as compared to saline-treated HIR group.

Conclusion: Elabela mitigated hepatic ischemia/reperfusion injury by regulating hepatic blood flow and preserving the balance between oxidants and antioxidants, likely by reducing ROS production. Additionally, hepatoprotective effects of elabela may also involve its ability to counteract inflammation, particularly through its action on IL-6.

Keywords: Ischemia/reperfusion injury, elabela, liver surgery

Poster Presentation

MYRTUS COMMUNIS LESSENS IONIZING RADIATION-INDUCED ILEUM, COLON, LIVER AND PANCREATIC DAMAGE IN RATS

MELİSA BAĞCI KILIÇ, MELİKE PEKYÜREK VARAN, ÖZÜM ATASOY, NAGEHAN ÖZYILMAZ, SEREN EDE PAZARBAŞI, BÜŞRA ERTAŞ, ALİ ŞEN, CEMİLE CEYLAN, TUĞBA TUNALI AKBAY, FERİHA ERCAN, BESTE M. ATASOY

Marmara University, nagehanozyilmaz@hotmail.com

Abstract

Introduction: Radiation therapy is curative in cancer treatment however it has side effects on healthy tissues. The ionizing radiation leads cellular damage by increasing reactive oxygen species and triggering inflammatory responses. These effects of ionizing radiation cause repairable or permanent damages in tissues. Myrtus communis L. subsp. communis (MC) is known to have antioxidative, anti-inflammatory, anti-mutagenic, anti-emetic, analgesic and anticancer effects.

Objective: The aim of this study was to investigate the possible protective effects of MC on ionizing radiation induced abdominal organ damage including the ileum, colon, liver and pancreas.

Materials and Methods: Rattus norvegicus rats were divided into four groups (n=30) as control, irradiation (IR) only, MC-pretreatment and MC-treatment. MC extract was administered orally at 100 mg/kg once daily for four days and started four days before IR in MC-pretreatment group while MC treatment group received oral MC for four days beginning on the day of IR. Irradiation with a fraction of 10 Gy was performed on all IR groups. On the fourth day of irradiation, rats were sacrified and ileum, colon, liver, and pancreas samples were taken for histological and biochemical analyses. Histopathological scores were calculated for each tissue. Malondialdehyde (MDA), glutathione (GSH), myeloperoxidase (MPO) levels and Na-K ATPase activities were measured in tissue homogenates. Statistical analyses were evaluated by comparing groups in t-test and significance was accepted at the level of $p<0.05$.

Results: Flattened villus damage, dilated glandular structures in ileum, degenerated epithelium and dilated mucosal glands in colon; cellular damage and disorganization of cells in both pancreatic acini and islets of Langerhans in pancreas and sinusoidal congestion, disorganization of hepatic cords and hepatocyte damage in liver were observed in the IR group. Increase in MDA and MPO activity ($p<0.001$) and decrease in GSH level and Na-K ATPase activity ($p<0.001$) were observed in IR group comparing to the control group. These histological and biochemical effects were significantly reduced in all tissues in the MC-pretreated and MC-treated groups comparing to the IR group.

Conclusion: According to the findings of this study, prophylactic or treatment of MC administration ameliorated the ionizing radiation induced oxidative damage in rat's gastrointestinal system via the antioxidative and anti-inflammatory effects.
Key words: gastrointestinal system, ionizing radiation, Myrtus communis, rats

Poster Presentation

IMMUNOHISTOCHEMICAL ASSESSMENT OF THE DISTRIBUTION AND QUANTIFICATION OF IMMUNOCOMPETENT CELLS IN THE RATS' LUNGS

ALIYARBAYOVA AYGUN | SULTANOVA TAMILLA | NAJAFOVA TARANA | ALIYEVA IRADA | IBRAHIMOVA TUBUXANIM | HAQVERDIYEVA RAYA

Azerbaijan Medical University, alyarbayova@gmail.com

Abstract

Introduction. The lung is an organ that is constantly and freely exposed to external environmental influences, especially microbes, bacteria, dust particles, tobacco, and hazardous substances. It is important to study the distribution and types of immunocompetent cells in the lungs that perform the protective and defensive function of the organ.

Objective. The aim of the research was to study the position and proportion of immunocompetent cells in the lungs of rats by immunohistochemistry.

Material and Methods. The study was carried out on the lungs from 24 adults male Wistar albino rats of 200-220 grams weight, obtained from the Scientific Research Centre of Azerbaijan Medical University. The principles of behaviour with used animals was followed in experimental scientific study. Immunohistochemical studies were performed on 4-5µm thick formalin-fixed and paraffin-embedded tissues, that serially sectioned H&E stained and using appropriate monoclonal antibodies CD3, CD20, and CD68 ("eBioscienceTM"). Immunocompetent cells were identified by histological, and immunohistochemical criterias. Morphometric parameters were analyzed by methods of variational and nonparametric statistical analysis (M±m; P=0.95; $p<0.05$; $\chi 2$; r).

Results. In the lungs of intact rats, histotopographically, 2 main location types of cells were identified, that can be considered as "immunocompetent cells".

I. "Lymphoid collections " included broncho-associated lymphoid tissue (BALT; 62.3±6.1% of the total), perivascular lymphoid tissue (PVLT; 17.7±1.9%), and intraorganic lymphoid clusters (9.1±1.0%). It should be noted that within PVLT and BALT of rats' lung are histologically absent follicular ("reactive") centre, intermediate and peripheral zones, which may be one of the manifestations of the difference between these structures and lymph nodes located at the gate of the lung. Intraorganic lymphoid clusters also histologically were evaluated as "lymphoid pseudonodes" and were revealed their difference from portal lymph nodes of the organ by size, topography, architecture and the ratio of cell types.
II. "Free" cells. It consists of stromal lymphoid cells, dendritic cells, plasma cells and macrophages, which are found freely, individually, singly or in small groups. It should be noted that the alveolar macrophages also belong to this group, which contains 10.9%± 0.9% of the total composition of macrophages of the organ. The "free" cells are unevenly distributed throughout the organ and have no specific topographical features. These cells have the ability to migrate within the organ during acute inflammation and prepare an immediate immune response.

Conclusion. Summarizing the data on distribution and quantitative analysis of immunocompetent cells, it should be noted that the lungs are rich in lymphoid tissue and active participated organ in immune responses to environmental antigens.

Keywords: immunocompetent cells, lung, immunohistochemistry.

Poster Presentation

ROTTLERIN APPLICATION SLOWED THE MIGRATION OF GLIOBLASTOMA CELLS

ALEYNA ŞIŞANECİ | EMİNE YAZICI | MERZUKA KALAY | ECE OYLUMLU | SENDEGÜL YILDIRIM | ORHAN KOCAK | GAMZE TANRIÖVER

Akdeniz University, Faculty Of Medicine, Department Of Histology And Embriyology, Antalya
asisaneci@gmail.com

Abstract

Introduction and Aim: Glioblastoma Multiforme (GBM) is most common primary malignant brain tumor of the central nervous system and its treatment is complex and challenging in every aspect. Currently, treatment consists of surgical resection followed by radiotherapy and concurrent chemotherapy (Temozolomide; TMZ). However, patients develop resistance to TMZ over time and do not respond to treatment. Rottlerin (ROT) is a product obtained from the Mallotus philippinensis plant and inhibits eEF2 kinase, which induces tumor development, proliferation and metastasis.

Aim: ROT may have an inhibitory effect on GBM cells, but its effect on these cells has not yet been defined. The aim of this study was to demonstrate the impact of ROT alone and in combination with TMZ on cell viability and migration in TMZ-resistant GBM cells.

Materials and Methods: In TMZ-resistant GBM cell line, appropriate doses of ROT (low and high dose) and TMZ were determined and cells were treated with ROT individually and in combination with TMZ. Cells were stained with Trypan Blue and their viability was analyzed. Subsequently, wound healing assay was performed to evaluate migration ability of cells.

Results: The viability observed in control group showed a significant decrease in groups in which ROT was administered individually and in combination with TMZ. Migration was also slowed down in combination groups compared to control group.

Conclusion: ROT, which has not been previously described in TMZ-resistant GBM cells, has been shown to affect viability of tumor cells and limit their migration. These preliminary data from our project are beginning of new in vitro studies.

Keywords: Rottlerin, Temozolomide, Glioblastoma Multiforme, migration

Poster Presentation

EFFECT OF NORMOBARIC INTERMITTENT HYPOXIA ON BONE TENDON JUNCTION HEALING: A RAT MODEL

ANIL TARIK SAYGILI | MUSTAFA TEKİN | BUĞRA KUNDAKÇI | ERAY CEYLAN | ARZU AVŞAR | SAİT POLAT | SAMET KARA

Orthopedy And Traumatology, Faculty Of Medicine, University Of Çukurova, 01330 Balcali, Adana, Turkey
asmtkara@gmail.com

Abstract

Objective: The aim of this study is to investigate the biomechanical and histological effects of normobaric intermittent hypoxia on the healing process of the bone-tendon junction. Considering the challenges encountered in the natural healing processes of the bone-tendon junction, the potential impact of normobaric intermittent hypoxia on this process was explored.

Materials and Methods: In this study, 64 adult female Wistar-Albino rats were used. The subjects were divided into two main groups: control and experimental, with each main group further divided into two subgroups for biomechanical and histological analyses. The intermittent hypoxia application involved exposing the subjects to an average of 10.5% oxygen level for 5 hours a day, 5 days a week. The rats were subjected to an 8-week follow-up period during which the healing processes of surgically induced Achilles tendon injuries were evaluated. Two observation points were determined with samples taken at the 4th and 8th weeks. Biomechanical analyses were conducted using a Testometric (M500-50CT, UK) device, while histological evaluations were performed using Safranin-O and Picro-Sirius stains, assessed microscopically according to Bonar, Movin, and Nourissat scoring systems.

Results: Significant improvements were observed in the biomechanical strength and histological structure of the healing bone-tendon junction in the experimental group subjected to intermittent hypoxia. At the end of the 8th week, the experimental group showed statistically significant higher values in extension at break, maximum extension, stress at break, and maximum stress compared to the control group (p-values: 0.016, 0.031, 0.016, 0.033, respectively). Evaluations according to Bonar, Movin, and Nourissat scoring systems indicated that the experimental group had significantly lower Bonar and Movin scores than the control group, demonstrating better healing (p-values: 0.009, 0.004, respectively). Additionally, the parameter analyses of these scoring systems revealed significant findings at the 8th week: increased collagen content in the Bonar scoring system, decreased hyalinization in the Movin scoring system, and improved collagen organization in the Nourissat scoring system compared to the control group (p-values: 0.009, 0.041, 0.015, respectively).

Conclusion: This study demonstrates that intermittent hypoxia application has beneficial effects on the healing process of the bone-tendon junction. Biomechanical and histological findings indicate that intermittent hypoxia supports the reformation of the enthesis structure by reducing scar tissue formation and enhancing the tendon's elasticity, load-bearing capacity, extension capacity, and stress tolerance. These results suggest that intermittent hypoxia could be a potential therapeutic approach in the treatment of orthopedic injuries.

Poster Presentation

A NEW APPROACH TO THE TREATMENT OF GLIOMA TUMORS; COULD IT BE INDOXIMOD?

EMİNE YAZICI | ALEYNA SISANECI | MERZUKA KALAY | ECE OYLUMLU | SENDEGÜL YILDIRIM | ORHAN KOCAK | GAMZE TANRIOVER

Akdeniz University, Faculty Of Medicine, Department Of Histology And Embryology, emineyazici2525@hotmail.com

Abstract

Introduction: Glioma is an aggressive malignant tumor of central nervous system. Temozolomide (TMZ) is a chemotherapeutic agent widely used for clinical treatment of glioma patients. IDO enzyme is a component that converts tryptophan (Trp) to kynurenine (Kyn) and causes T cell loss. Indoximod is an IDO inhibitor that reverses the immunosuppressive effects of low Trp and high Kyn levels. Melatonin is an agent known to strengthen immune system and increase natural killer cells in defence against cancer.

Aim: Based on the hypothesis that survival of GBM cells becomes difficult when Indoximod and Melatonin are applied together, our project was designed to evaluate the effect of Indoximod alone and combination with Melatonin on cell viability and migration in T98G resistant glioma cells.

Materials and Methods: Doses of Indoximod and Melatonin were determined for T98G cells, Indoximod and Melatonin were applied to cells both individually and in combination. The cells were stained with Trypan Blue and their viability at 24, 48, 72 hours was analysed. In addition, we analysed the movement potential of tumor cells by migration assay.

Results: Indoximod and Melatonin were applied to GBM cells in combination for the first time. In addition, it was shown that the application of Indoksimod and Melatonin after scarring in resistant glioma cells slowed down cell migration and reduced survival.

Conclusion: As a result of the combined application of Indoximod and Melatonin; in our study, it was observed that the survival of glioma cells decreased, and their movement/migration potentials slowed down. The findings we have obtained will lead to new studies and will make a significant contribution to the literature.

Keywords: Glioma, resistant T98G cell line, Indoximod, Melatonin.

Poster Presentation

MITOCHONDRIAL AND APOPTOTIC PROTEOMIC PROFILE OF MESENCHYMAL STEM CELLS IN ENDOMETRIOSIS

SELENAY FURAT RENCBER | YUSUFHAN YAZİR | MEHMET SARIHAN

Kocaeli University Faculty Of Medicine Department Of Histology And Embryology
selenay.furat@hotmail.com

Abstract

Introduction:Endometriosis is characterized by the growth and invasion of endometrial tissue outside the uterine cavity, and this condition affects 20 to 50% of infertile women. Recent studies suggest that stem cells contribute to the etiology of endometriosis. Microenvireonment of endometriotic lesions characterized by increased concentrations of hormones, inflammation, and oxidative stress. Dysfunctional mitochondria seen in endometriosis increase energy production to sustain proliferation demand and consequently leading to reactive oxygen species (ROS) overproduction. Also mitochondrial dysfunction is related to human diseases, particularly regulation of apoptosis and mitochondrial metabolic activities. Additionally, endometriosis is an estrogen-dependent disease and estrogen can modify ROS production and apoptotic processes to favor lesion development.

Objective: We aimed to elucidate mitochondrial activity and apoptosis profile of mesenchymal stem cells (MSCs) in endometriosis pathophysiology.

Material-Method: MSCs were isolated from both eutopic and ectopic samples of women with endometriosis. Women who underwent surgery for benign gynecological procedures were considered as a control group. Following the characterization and differentiation assays, MSCs were analysed with LC MS/MS to reveal mitochondrial and apoptotic proteom profile. Raw MS/MS fragmentation spectra were analysed with Proteome Discoverer 2.2 software and searched against UniProt Homo sapiens reference proteome database with all isoforms. String analysis and heatmap were used for distribution and relation of proteins.

Results: In proteomic analysis, a fold change of more than 5 and less than 0.2 was considered significant in terms of fold increase or decrease in proteins. According to this parameter, significant difference was observed between control and endometriosis groups in terms of mitochondrial and apoptotic proteins. In the proliferative phase, it was determined that the translation of oxidative phosphorylation, mitochondrial electron transport, mitophagy, and regulation of apoptosis proteins were decreased in eutopic MSCs compared to the control MSCs. When ectopic MSCs and control MSCs were compared, it was determined that programmed cell death, intrinsic apoptotic signaling pathways and aerobic electron transport chain proteins were downregulated in ectopic MSC group. When endometriosis groups (eutopic and ectopic) were compared among themselves, IRE1-mediated UPR, mitochondrial electron transport and apoptotic processes proteins were increased in eutopic MSCs; whereas translation of proteins related to mitophagy, oxidative phosphorylation and aerobic respiration is decreased.

Discussion: Downregulation of apoptosis and mitochondrial electron transportation proteins in endometriosis groups (both in eutopic and ectopic MSCs) compared to the control group

indicates that disrupted apoptotic pathways and disfunctional mitochondria of MSCs may involved in the pathophysiology of endometriosis.

Poster Presentation

DO MICROPLASTICS EFFECT TIGHT JUNCTION PROTEINS AT SERTOLI CELLS?

RUKİYE ŞEYMA BAY[1] | HİLAL NAKKAŞ[2] | E. NAZLI HAYIRLI ÖZYOL[3] | SEMİH ÇALAMAK[4] | ŞULE KIZIL[1]

[1]Lokman Hekim University, Faculty Of Medicine, Department Of Histology And Embryology, Ankara, Turkiye | [2]Ankara Yildirim Beyazit University, Faculty Of Medicine, Department Of Histology And Embryology, Ankara, Turkiye | [3]Hitit University, Faculty Of Medicine, Department Of Histology And Embryology, Çorum, Turkiye | [4]Lokman Hekim University, Faculty Of Pharmacy, Department Of Basic Pharmaceutical Sciences, Ankara, Turkiye
221712002@lhu.edu.tr

Abstract

Introduction: As a result of the increasing use of plastics in every aspect of daily life, the accumulation of their residues in the tissues and organs of living beings and the damage they cause are also increasing. Microplastics (MPs) are defined as plastic particles and fibers smaller than 5 mm that can accumulate in the organism, have toxic effects, and serve as transport media for various endocrine disrupting and carcinogenic substances. There are 11 types of MP polymers and polypropylene (PP) is one of them that can be easily found in many of the consumer goods we use today. Studies have shown that MPs have effects on development, growth, reproduction, behavior and mortality in aquatic and terrestrial animals. Recent studies have shown that administration of different types of MPs induce male reproductive toxicity in mice or rats, including testicular inflammation, reduced testosterone level and disruption of blood-testis barrier. The blood-testis barrier (BTB) not only acts as an immune barrier to separate antigens from the blood circulation and post-meiotic germ cells, but also creates a unique microenvironment for spermatogenesis. BTB is composed of junctions that present between Sertoli cells.

Aim: Even it is known that MPs give harm to BTB, there is no study examining the effect of polypropylene on the blood-testis barrier. In this study we aimed to show if there is an effect of PP on BTB over junction proteins zonula occludens (ZO-1) and Claudin 3 (Cldn3).

Materials And Methods: PP-MPs were obtained by fragmenting transparent drinking straws in distilled water using a blender and Ultra Thorax device, followed by filtration with a 1000 µL filter and drying at room temperature. 15P-1/CRL-2618 mouse Sertoli cells (ATCC) were cultured in DMEM-HEPES medium containing 10% FBS, 1% penicillin-streptomycin, and 1% L-glutamine. Sertoli cells were incubated for 24 and 48 hours with culture medium containing PP-MPs at concentrations of 10 and 50 µg/ml. Following incubation, immunofluorescence labeling was performed using ZO-1 and Cldn3 primary antibodies. The immunofluorescence intensity was measured using the ImageJ program, and the data obtained were analyzed using the ANOVA statistical test.

Results And Discussion: The decrease in ZO-1 expression in Sertoli cells incubated with PP-MPs compared to the control group was not statistically significant. However, Cldn3 expression showed a statistically significant decrease in Sertoli cells incubated with PP-MPs

compared to the control group. These findings suggest that PP-MPs may potentially disrupt the blood-testis barrier, warranting further investigation.

Key Words: Microplastic, polypropylene, Sertoli, zonula occludens, claudin-3

Poster Presentation

ESTABLISHMENT OF AN IMIQUIMOD-INDUCED PSORIASIS-LIKE IN VITRO MODEL IN $CACL_2$-DIFFERENTIATED HUMAN KERATINOCYTES: MORPHOLOGICAL, BIOCHEMICAL, AND MOLECULAR APPROACHES

SEDA KESKİN[1] | MUSTAFA CAKİR[2] | YİGİT UYANİKGİL[3] | SERİFE CAKİR[4] | EDA ACİKGOZ[1]

[1]Department Of Histology And Embryology, Faculty Of Medicine, Van Yuzuncu Yil University, 65090, Van, Turkey | [2]Department Of Medical Biology, Faculty Of Medicine, Van Yuzuncu Yil University, 65090, Van, Turkey | [3]Department Of Histology And Embryology, Faculty Of Medicine, Ege University, 35100, Izmir, Turkey | [4]Department Of Biomedical Engineering, Faculty Of Engineering, Erciyes University, 38039, Kayseri, Turkey
sedakeskin@yyu.edu.tr

Abstract

Introduction: Psoriasis is a chronic inflammatory skin disease involving complex immune cell and keratinocyte interactions, with no definitive treatment due to its complex pathogenesis. The development of anti-psoriatic drugs is lengthy, costly, and marked by high clinical phase failure rates, underscoring the need for in vitro models with high predictive accuracy. Existing models inadequately reflect keratinocyte properties, highlighting the potential of new models simulating keratinocyte differentiation and psoriatic inflammation to enhance drug efficacy and reduce time and cost in clinical trials.

Objective: The aim of the present study was to investigate the mechanisms of imiquimod (IMQ)-induced inflammation and cell-cell interactions in CaCl2-differentiated human keratinocytes (HaCaT) using morphological, biochemical, and molecular methods in a modified in vitro psoriasis-like model.

Material &Method: To establish an in vitro psoriasis-like model, HaCaT cells were first differentiated with 2 mM CaCl2 for 48 h and then stimulated with 25 µM IMQ for 24 h to induce psoriasis-like inflammation. The experimental groups were divided into four categories: Ca-free control, 2 mM CaCl2, 25 µM IMQ, and 2 mM CaCl2 + 25 µM IMQ. Cell morphology in all groups was evaluated using an inverted microscope. Hematoxylin and eosin (H&E) staining was used to examine cell morphology, while immunofluorescence (IF) staining for cytokeratin 17 (CK17) and proliferating cell nuclear antigen (PCNA) was performed to assess proliferation. Actin and prohibitin IF staining was conducted to analyze intercellular connections. Psoriasis-associated inflammatory cytokines were measured using ELISA, and the expression of Toll-like receptors (TLRs), NOD-like receptor protein 3 (NLRP3) inflammasome, angiogenic, hypoxia, and transforming growth factor (TGF)-β/Smads genes was analyzed using qRT-PCR.

Results: IMQ-stimulated HaCaT cells exhibited morphological features and structural changes similar to psoriatic keratinocytes. IF staining revealed that the expression levels of CK17, PCNA, actin, prohibitin, and pro-inflammatory cytokines were significantly elevated in the IMQ group compared to the control. Additionally, angiogenic, hypoxia, and TGF-β/Smads

gene expressions were markedly increased in the IMQ group, primarily through the activation of the TLR and NLRP3 inflammasome pathways, compared to other groups.

Conclusion: The findings demonstrate that the IMQ-induced in vitro psoriasis-like model in CaCl2-differentiated HaCaT cells successfully replicated the inflammatory responses observed in psoriatic tissue at the microscopic, molecular, and biochemical levels in human keratinocytes. Moreover, the ability of this in vitro model to mimic psoriatic inflammation offers a practical and valuable tool for evaluating the antipsoriatic efficacy of new drug candidates.

Keywords: Psoriasis, CaCl2, Imiquimod, Keratinocyte, Inflammation, In Vitro Model

Acknowledgement: This research was conducted as part of the doctoral project numbered TDK-2022-10132 and was supported by the VAN YYU Scientific Research Projects Unit.

Poster Presentation

EFFECTS OF PSEUDOEPHEDRINE ON RAT FETAL BONE DEVELOPMENT

HÜSEYİN YİĞİT[1] | ESRA BALCIOĞLU[2] | İLYAS UÇAR[3] | MUHAMMET DEĞERMENCİ[4] | GÖZDE ÖZGE ÖNDER[2] | TAYFUN CEYLAN[5] | ERDOĞAN UNUR[3]

[1]Department Of Medical Services And Techniques, Cappadocia Vocational School, Cappadocia University, Nevşehir,Turkey | [2]Department Of Histology And Embryology, Faculty Of Medicine, Erciyes University, Kayseri,Turkey | [3]Department Of Anatomy, Faculty Of Medicine, Erciyes University, Kayseri, Turkey | [4]Department Of Anatomy, Faculty Of Medicine, Ordu University, Ordu, Turkey | [5]Department Of Basic Sciences, Faculty Of Dentistry, Cappadocia University, Nevşehir, Turkey
tyf.ceylan@gmail.com

Abstract

Introduction: Pseudoephedrine (PSE) is an agent that is included in the amphetamine class, which is the stereoisomer of ephedrine. Drugs containing PSE are the 4th most commonly prescribed drug group in the USA and usually prescribed for the treatment of cold and cough. Thus, PSE is one of the most commonly used over-the-counter medications. Although the drug is used so frequently, it is not known what effects it has on the newborn as a result of maternal exposure (1, 2). Although there is insufficient evidence of a negative effect of PSE, the results of some studies suggest that it should be used with caution (3).

Objective: Considering previous public health studies and warnings in the literature, we decided to investigate the effects of the drug on long bones. Our hypothesis was that this drug had adverse effects on neonatal bones and adversely affected ossification.

Material-Method: Pregnant rats were divided into five groups: control and four experimental groups (25 mg/kg, 50 mg/kg, 100 mg/kg, 200 mg/kg PSE). Between 1 and 20 days of pregnancy, PSE was given to them by gavage. Weights and heights of fetuses isolated by cesarean on the 21st day were measured. We analyzed bone and ossification ratios and lengths by the double staining skeleton staining method. We determined the differences between the groups by measuring the ossification stages, the diameters and lengths of the lacunae and chondrocytes with Scanning Electron Microscope (SEM). We analyzed the differences between the groups by detecting the minerals directly affecting ossification by SEM-energy-dispersive X-ray (EDX) analysis (4).

Results and Conclusion: In this study, the negative effects of PSE on rat embryos were investigated on bone. Both double staining, SEM and EDX analyzes were consistent with each other and clearly revealed the destruction of PSE on long bones. Although this study is the first to reveal the detailed effects of this drug, which is widely used by the population, we believe that the mechanism of the drug causing fetal long bones destruction should be investigated in the future.

Poster Presentation

THE EFFECTS OF INTERMITTENT FASTING ON URINARY SYSTEM FUNCTIONS IN GENETIC ABSENCE EPILEPTIC RATS IN TERMS OF GENDER DIFFERENCES

ZARİFE NİGAR ÖZDEMİR-KUMRAL[1] | MEHMET ALİ BERKYÜREK[3] | ÖZLEM TUĞÇE ÇİLİNGİR-KAYA[3] | DAMLA GÖKÇEOĞLU KAYALI[3]

[1]Department Of Physiology, School Of Medicine, Marmara University, Istanbul, Türkiye | [2]Medical Student, Marmara University, Faculty Of Medicine, Istanbul, Turkey. | [3]Department Of Histology And Embryology, School Of Medicine, Marmara University, Istanbul, Türkiye damlagokceoglu@yandex.com

Abstract

Introductıon: Epilepsy is a complex neurological disorder that can impact multiple organ systems beyond the central nervous system, including the urinary, endocrine, and cardiovascular systems, highlighting its systemic effects on overall health. Absence epilepsy, a subtype, involves brief seizures with loss of consciousness, occurring multiple times daily. Research links epilepsy with urinary dysfunction, such as bladder incontinence and frequent urination, likely due to neurological factors, autonomic nervous system dysfunction, or antiepileptic drug side effects. Animal models like GAERS and WAG/Rij rats show similar issues, suggesting a neurophysiological link. Dietary interventions, such as alternate-day fasting, may help modulate central nervous system inflammation and influence bladder function in epilepsy.

Aım :The aim of this study is to investigate the effects of food restriction, specifically alternate-day fasting, on urinary system damage in genetic absence epileptic rats.

Materıals & Methods: In our study, 80 rats (40 female, 40 male) were used, divided into four experimental groups: Control, IF, GAERS, and GAERS+IF (each with 10 female and 10 male rats). Bladder tissue responses to contraction and relaxation were assessed using KCl, carbachol, and isoproterenol in an organ bath. Oxidative stress markers (MDA, MPO, GSH, SOD) were measured biochemically, while histopathological analysis included H&E and Toluidine Blue staining to evaluate mast cell changes. Statistical analysis was conducted with GraphPad Prism 10, using one-way ANOVA and Tukey's test, with a significance level of $p < 0.05$.

Results: Compared to the GAERS group, the GAERS+IF group exhibited a significant reduction in MDA levels ($p<0.05$) and a significant increase in GSH and SOD levels ($p<0.05$) in kidney tissues, indicating a reduction in oxidative stress due to IF. In bladder function tests, GAERS on IF showed reduced hyperreactivity to carbachol and normalized relaxation responses to papaverine ($p<0.05$) compared to the GAERS group. The histopathological score of bladder tissue in the GAERS group showed a significant increase compared to the control and IF group ($p<0.05$, $p<0.01$). This increase was significantly reduced with IF treatment ($p<0.05$). Additionally, female rats exhibited more severe histopathological changes compared

to males. The number of mast cells was significantly higher in the GAERS group compared to all other experimental groups ($p<0.01$, $p<0.05$).

Conclusıons: These results suggest that IF could be a potential dietary strategy for managing epilepsy-related urinary dysfunction, highlighting the need for further research to explore its underlying mechanisms, potential gender differences, and long-term effects.

16. ULUSAL HİSTOLOJİ VE EMBRİYOLOJİ KONGRESİ

ÖZET METİN KİTABI

Davetli Konuşmacı

İMPLANTASYON ŞIFRESININ ÇÖZÜLMESI: FARE MODELLERINDEN İPUÇLARI

NURAY ACAR AYDEMİR

Akdeniz Üniversitesi Tıp Fakültesi Histoloji ve Embriyoloji Anabilim Dalı, Antalya
nurayacar@akdeniz.edu.tr.

Özet: Embriyo implantasyonu en basit ifadeyle embriyonun uterusa yerleşmesidir. Bu olay, implante olma yeteneği olan blastosist ile reseptif uterus arasındaki etkileşim sonucu implantasyon penceresi olarak bilinen zaman aralığında gerçekleşir. Farelerde yapılan çalışmalar, ortak özellikleri nedeniyle insan implantasyonunun moleküler temeline dair öngörüler sağlamıştır. Fare ve insanda implantasyon süreçlerindeki benzerlikler arasında hem fare hem insan embriyolarının basit medyumlarda in vitro gelişebilmesi; her iki türde desidualizasyon görülmesi, embriyonun antimezometriyal stromaya gömülmesi ve plasentanın hemokoryal olması yer alır. İki tür arasında önemli farklılıklar da bulunur. Farede implantasyon eksentrik, insanlarda interstisyeldir. İmplantasyon sırasında farede embriyo iç hücre kitlesi mezometriyal, insanlarda ise antimezometriyal yönlendirilir. Farenin aksine, insanda desidualizasyon embriyo varlığı olmadan başlar. Fare türlerinde aylık doğurganlık oranı yaklaşık 3 kat daha yüksektir ve ortalama yavru sayısı 10-12'dir. Vajinal tıkaç oluşumu 1. gün kabul edildiğinde farelerde gebelik 20 gündür. Gebeliğin 1-3. günlerinde uterus pre-reseptif, 4. günü gecesi reseptif, 5. gün öğleden sonradan itibaren ise non-reseptif durumdadır. Farelerde ovulasyondan hemen önce östrojen (E2) salgılanması gebeliğin ilk iki günü boyunca lümen ve bez epiteli hücrelerinin proliferasyonunu uyarır. Korpus luteumdan salgılanan progesteron (P4) gebeliğin 4. gününde pre-implantasyon E2 salgısı ile proliferasyonun epitelden stromaya kaymasını sağlar. Epitel hücreleri çoğalmayı bırakır ve 4. günde farklılaşır. Kemirgenlerde implantasyon apozisyon, adezyon ve invazyon olarak 3 evreye ayrılmıştır. Apozisyonda P4 artışına bağlı ödem sonucu trofoblast ile lümen epiteli hücreleri yakın hale gelerek karşılıklı konumlanırlar. Adezyon farelerde gebeliğin 4. günü gecesi başlar. Blastosistin tutunduğu yerde endometriyal vasküler geçirgenlik artar, bu nedenle Chicago mavisi gibi makromoleküler bir boyanın intravenöz enjeksiyonuyla implantasyon bölgeleri mavi bantlar şeklinde görülür. İnvazyon safhasında anne ile vasküler bir ilişki kurabilmek için blastosist trofoblast hücreleri lümen epiteli ve bazal laminayı geçerek stromaya ulaşır. Kemirgenlerde invazyon sonrasında implante olan blastosistin etrafındaki stroma hücreleri desidualize olurlar (desidualizasyon). Embriyo antimezometriyumdaki stromaya gömülür. Embriyo implantasyonu, ovaryum steroidlerinin birincil etkisi altında blastosist ve uterus arasındaki hücre-hücre etkileşimleri sonucu gerçekleşir. Embriyo implantasyonu sırasında ovaryum steroidlerinin birincil etkisi altında blastosist trofektodermi ile uterus lümen ve bez epiteli, stroma hücreleri arasında gerçekleşen otokrin, parakrin ve jukstakrin etkileşimlerde birçok sitokin, büyüme faktörü, homeobox transkripsiyon faktörü, lipid aracı ve morfogen rol alır. İmplantasyonun kalitesi devam eden gebeliğin kalitesini belirler. Bu aşamadaki herhangi bir hata, erken gebelik kaybına veya çeşitli gebelik komplikasyonlarına neden olacaktır. Sinyal yolaklarına ilişkin yapılacak daha fazla çalışma, gebelik başarısını artırabilir ve daha gelişmiş kontraseptiflerin tasarlanmasına yardımcı olabilir.

Sözlü Bildiri

MİKRO-TESE İLE SPERM ELDE EDİLEN NONOBSTRÜKTİF AZOSPERMİK ERKEKLER VE KRİPTOZOOSPERMİK ERKEKLERDE ICSI SONUÇLARININ RETROSPEKTİF DEĞERLENDİRİLMESİ

LEYLA MAMMADLI[1] | HALE BAYRAM[2] | MEHMET CINCIK[2]

1Maltepe Üniversitesi Lisansüstü Eğitim Enstitüsü Klinik Embriyoloji Ad, halebayram@maltepe.edu.tr
2Maltepe Üniversitesi Tıp Fakültesi Histoloji Ve Embriyoloji Ad

Özet

Giriş: Üreme çağındaki çiftlerde infertilitenin küresel prevalansı %15 olup, tüm infertilite vakalarının %40-50'sinde erkek faktörü birincil neden olarak tanımlanmaktadır. Sperm sayısı ve sperm motilitesinin düşük olduğu kriptozoospermik erkeklerde ve semende sperm elde edilemeyen azospermik erkeklerde üremeye yardımcı tekniklerin kullanılması gerekir.

Amaç: Bu çalışmada azospermi sebebiyle mikro-TESE ile sperm elde edilen olgular ile kriptozoospermik olgular arasında fertilizasyon ve gebelik oranlarının retrospektif karşılaştırılması amaçlandı.

Materyal-Metot: Çalışmaya 2010-2019 tarihleri arasında infertilite tedavisi gören ve çalışma kriterlerine uyan 528 (azospermik n=256 (%48,5); kriptozoospermik n=272 (%51,5)) erkek dahil edildi. Vakaların % 100'ünde (n=528) döllenme olduğu görüldü. 528 vakanın 92 tanesinde çeşitli sebeplerden ötürü embriyo transferi yapılamadı, 436 olguda embriyo transferi yapıldı.

Bulgular: Emriyo transferi yapılan 436 olgudan %44,3'ünde (n=193) gebelik oluşmazken, %55,7'sinde (n=243) gebelik oluştu. Katılımcılar semen parametrelerine göre kriptozoospermik ve azospermik olarak iki gruba ayrıldı. Gruplar 2PN embriyo sayıları, gebelik oranları, kese sayıları ve dondurulmuş embriyo sayıları açısından karşılaştırıldı. Kriptozoospermik grupta dondurulmuş embriyo sayısı ve 2PN embriyo sayısı ≥6 olanların oranı daha yüksekti (sırasıyla p=0,008; p=0,036). Gebelik oranları ve kese sayıları gruplar arasında farklılık göstermedi (sırasıyla p=0,059; p=0,449).

Sonuç: Kriptozoospermik vakalarda başarılı fertilizasyonun göstergesi olan 2PN embriyo sayısı ve dondurulan embriyo sayılarının daha yüksek olduğu ancak sperm elde etme yönteminin gebelik ve kese oluşumunu etkilemediği sonucuna varılmıştır. Kriptozoospermik vakalardaki farklılığın elde edilen sperm sayısından kaynaklı olabileceği düşünülmektedir.

Anahtar sözcükler: Intrasitoplazmik sperm injeksiyonu; Kriptozoospermi; Azospermi; İnfertilite; In vitro fertilizasyon

Sözlü Bildiri

NAR VE ARONYA EKSTRELERİNİN SIÇANLARDA L-ARGİNİNLE OLUŞTURULAN PANKREAS HASARI ÜZERİNE TEDAVİ EDİCİ ETKİLERİ

EMİNE RÜMEYSA HEKİMOĞLU[1] | MUKADDES EŞREFOĞLU[1] | SEDA KIRMIZIKAN[1] | HURİ DEDEKAYOĞULLARI[2] | ÖZGE PASİN[3] | BİRSEN ELİBOL YÜCESOY[4]

1Bezmialem Vakıf Üniversitesi, Tıp Fakültesi, Temel Tıp Bilimleri, Histoloji Ve Embriyoloji Anabilim Dalı |2Biruni Üniversitesi, Tıp Fakültesi, Temel Tıp Bilimleri, Tıbbi Biyokimya Anabilim Dalı 3Bezmialem Vakıf Üniversitesi, Tıp Fakültesi, Temel Tıp Bilimleri, Biyoistatistik Ve Tıp Bilişimi Anabilim Dalı 4İstanbul Medeniyet Üniversitesi, Tıp Fakültesi, Temel Tıp Bilimleri, Tıbbi Biyoloji Anabilim Dalı
seda.krmzkn@gmail.com

Özet

Giriş ve Amaç: Akut Pankreatit (AP) morbidite ve mortalite oranı yüksek bir hastalıktır. Yeni tedavi stratejileri geliştirmeyi hedefleyen deneysel ve klinik çalışmalara rağmen, AP'nin tedavisi hala semptomatiktir. AP'de artan serbest oksijen radikallerinin yol açtığı oksidatif stres, pankreasta hasara neden olur. AP'in en sık görülen histopatolojik bulguları, inflamatuar hücre infiltrasyonu, nekroz, interstisyel ödem ve hemorajidir. Nar (Punica granatum) ve Aronya (Aronia melonocarpa) antioksidan ve anti-inflamatuar özelliklere sahip olan iki meyvedir. Çalışmamızda nar ve aronya ekstrelerinin bu özelliklerinin AP tedavisindeki etkinliğinin araştırılması amaçlandı.

Materyal-Metot: 32 adet Sprague-Dawley erkek sıçan kullanıldı. Sıçanlar, Kontrol, Pankreatit, Pankreatit+Nar, Pankreatit+Aronya grupları şeklinde 4 gruba ayrıldı (n=8). Kontrol grubu hariç tüm gruplara intraperitoneal yolla bir saat ara ile iki doz 2.5 g/kg L-arginin enjeksiyonu yapıldı. Pankreatit+Nar grubuna enjeksiyonun ardından 7 gün boyunca gavaj yolu ile 500 mg/kg nar ekstresi, Pankreatit+Aronya grubuna enjeksiyonun ardından 7 gün boyunca gavaj yolu ile 500 mg/gün aronya ekstresi, kontrol grubuna ise aynı sürede gavaj yolu ile serum fizyolojik verildi. Deney bitiminde pankreas dokuları ışık ve elektron mikroskobik olarak incelendi. Kalpten alınan kandan ve pankreas örneklerinden ayrıca biyokimyasal, Western-blotting ile Bcl-2, Bax, RIP3 ve LC3β, ELISA ile IL-1β seviyeleri ölçüldü.

Bulgular: AP grubunda ciddi nekrotik AP bulguları saptandı. Asiner hücre dejenerasyonu, hücre infiltrasyonu, ödem, nekroz ve apoptoz görüldü. Kontrol grubuna göre ortalama histopatolojik hasar skoru (OHHS) yüksekti ($p=0.001$). Elektron mikroskobik düzeyde intrasellüler ve intersellüler ödem, inflamatuar hücre infiltrasyonu, organel dejenerasyonu ve nekroz belirgindi. Çok sayıda apoptotik cisime, otofajik vakuole ve miyelin figüre rastlandı. Biyokimyasal analizlerle kontrol grubuna göre bu grupta serum amilaz ($p<0.005$), lipaz ($p<0.05$) ve Total Oksidan Seviyesinde (TOS) ($p<0.001$) artış, Total Antioksidan Seviyesinde (TAS) ($p<0.05$) düşüş saptandı. Nar ve aronya ($p<0.05$) uygulanan gruplarda AP grubuna oranla OHHS, serum amilaz ($p<0.05$), lipaz ve TOS ($p<0.001$) seviyeleri düşüktü, TAS ($p<0.05$) seviyeleri ise yüksekti. Elektron mikroskobik düzeyde kesitlerde her iki grupta genellikle sağlam pankreas dokusu görüldü. Zaman zaman organel dejenerasyonu, ödem, hücre infiltrasyonu ve nekroz izlendi.

Sonuç: Nar ve aronya ekstrelerinin başlıca antioksidan ve anti-inflamatuar güçleri sayesinde AP'e bağlı pankreas hasarının giderilmesinde etkili oldukları görüldü. Kolay ulaşılabilir, ucuz ve yan etkisiz olan bu iki ajanın AP'in tedavisinde tek başlarına tedavi edici ajan olarak kullanılamasalar bile uygulanan tedavi protokollerine olumlu ve destekleyici katkı sağlayacaklarını düşünmekteyiz.

Sözlü Bildiri

FORMALDEHİTİN YOL AÇTIĞI ORGAN HASARI ÜZERİNE TİMOKİNONUN ETKİLERİNİN İNCELENMESİ

SEDAT MEYDAN | BİLAL SAYGIN | KÜBRA BAŞOL BAKİ | MUKADDES EŞREFOĞLU

[1]Bezmialem Vakıf Üniversitesi, Tıp Fakültesi, Anatomi Anabilim Dalı | [2]İstanbul Medipol Üniversitesi, Tıp Fakültesi, İç Hastalıkları Anabilim Dalı | [3]Bezmialem Vakıf Üniversitesi, Sağlık Hizmetleri Meslek Yüksekokulu, Tıbbi Hizmetler Ve Teknikler Bölümü, Patoloji Laboratuvar Teknikleri Programı | [4]Bezmialem Vakıf Üniversitesi, Tıp Fakültesi, Histoloji Ve Embriyoloji Anabilim Dalı
kubra.basol@bezmialem.edu.tr

Özet

Giriş ve Amaç: Aldehitin en basit formu olan formaldehit çevreyi kirleten, kanserojen etkili bir maddedir. Özellikle histologlar, patologlar, anatomistler ve tıp öğrencileri formaldehitin zararlı etkilerine sık maruz kalmaktadırlar. Formaldehit maruziyet sıklığına göre organlarda değişen derecelerde hasara yol açmaktadır. Bu hasarın engellenmesi ve/veya giderilmesi insan sağlığı açısından çok önemlidir. Nigella sativa bitkisinin bir bileşeni olan timokinonun antioksidan, antiinflamatuar ve antitümör özelliklerinin olması bu ajanın tedavi edici etkilerinin olabileceğini düşündürmektedir. Bu çalışmada formaldehitin karaciğer, böbrek, testis ve kalp dokularında yol açtığı hasara karşı timokinonun etkinliği incelenmesi amaçlanmıştır.

Materyal-Metot: 40 adet Wistar albino erkek sıçan 5 gruba (n=8) ayrıldı. Formaldehit grubuna 15 gün boyunca intraperitoneal yolla %10'luk serum fizyolojikte seyreltilmiş formaldehit 10 mg/kg dozunda uygulandı. Formaldehit+Timokinon grubuna aynı sürede, aynı dozda formaldehitin yanı sıra gavajla 1 ml mısır yağı içinde 20 mg/kg timokinon, Timokinon grubuna aynı sürede gavaj yoluyla sadece 1 ml mısır yağı içinde 20 mg/kg Timokinon, Serum Fizyolojik grubuna aynı sürede intraperitoneal yolla serum fizyolojik, Mısır Yağı grubuna aynı sürede sadece gavaj yoluyla 1 ml mısır yağı uygulandı. On beş günlük deney sonunda sıçanlar sakrifiye edilerek karaciğer, böbrek, testis ve kalp dokuları alındı. Rutin doku takibi sonucu elde edilen kesitler Hematoksilen-Eozin yöntemiyle boyandı, ayrıca TUNEL immunohistokimyasal işaretleme yöntemi uygulandı.

Bulgular: Formaldehit grubunda karaciğerde vakuolizasyon ve intrasellüler ödem, böbrekte vakuolizasyon, tübül atrofisi, skleroz, nekroz, intersellüler ödem ve hemoraji, kalpte nekroz, hemoraji ve konjesyon, testiste intratübüler ve intertübüler ödem, tübül dejenerasyonu ve nekroz belirgindi. Formaldehit grubunda karaciğerin ortalama vakuolizasyon skoru ($p<0.005$), böbreğin sklerotik glomerül sayısı ($p<0.005$) ve ortalama histopatolojik hasar skoru (OHHS) ($p<0.005$), kalbin ($p<0.005$) ve testisin ($p<0.005$) OHHS Serum Fizyolojik grubuna göre yüksekti. Formaldehit+Timokinon grubunda karaciğerin ortalama vakuolizasyon skoru ($p<0.005$), böbreğin sklerotik glomerül sayısı ($p<0.005$) ve OHHS ($p<0.05$), kalbin ve testisin ($p<0.005$) OHHS Formaldehit grubuna oranla düşüktü. Formaldehit grubunun karaciğerlerinde, kalplerinde, böbreklerinde ($p<0.05$) ve testislerinde ($p<0.05$) ortalama TUNEL + hücre sayısı Serum Fizyolojik grubuna göre yüksekti. Formaldehit+Timokinon grubunda bu sayı karaciğerde ($p<0.05$), böbrekte ($p<0.05$) ve kalpte Formaldehit grubuna oranla düşüktü.

Sonuç: Formaldehitin farklı organlarda farklı derecelerde hasara yol açtığı görüldü. Timokinonun da farklı organlardaki etkinliğinin farklı derecelerde olduğu görüldü. Histopatolojik açıdan yararlı etkilerin karaciğer, böbrek ve testiste daha belirgin olduğu, apoptotik hücre ölümünü baskılayıcı gücünün ise karaciğer ve böbrekte daha belirgin olduğu saptandı. Timokinonun tedavi edici ajan olarak potansiyelinin olduğu, en azından formaldehite sık maruz kalan kişilerde yüksek oranda timokinon içeren gıdaların tüketilmesinin yararlı olacağı sonucuna varıldı.

Sözlü Bildiri

DOKSORUBISIN KAYNAKLI KARDIYOTOKSISITEDE ÜZÜM (VITIS VINIFERA L.) ÇEKIRDEĞI EKSTRAKTININ KORUYUCU ETKISININ ARAŞTIRILMASI

EMİNE SARMAN[1]*, İBRAHİM AYDIN CANDAN[2], JALE AKGÖL[3], İREM NAZIROĞLU[1]

**1 Afyonkarahisar Sağlık Bilimleri Üniversitesi, Tıp Fakültesi, Histoloji ve Embriyoloji A.D., Afyonkarahisar, Türkiye, emine.sarman@afsu.edu.tr*
2 Alanya Alaaddin Keykubat Üniversitesi, Tıp Fakültesi, Histoloji ve Embriyoloji A.D., Alanya, Türkiye,
3 Afyonkarahisar Sağlık Bilimleri Üniversitesi, Tıp Fakültesi, Tıbbi Farmakoloji A.D., Afyonkarahisar, Türkiye,

Özet

Giriş: Kanser, dünyada morbidite ve mortalitenin önde gelen nedenlerinden biridir. Doksorubisin (DXR), geniş spektrumlu antrasiklin türevi antibiyotiklerden biri olarak kanser tedavisinde kullanılmaktadır. DXR'nin tedavi amaçlı kullanımları sırasında kalp başta olmak üzere birçok dokuda toksisiteye neden olduğu çalışmalarda gösterilmiştir. Antioksidanlar, vücudumuzu serbest radikallerin toksik etkilerine ve normal oksijen metabolizmasına karşı savunmada önemli bir role sahiptir. Üzüm çekirdeği ekstraktının güçlü bir antioksidan özelliğinin olduğu ve serbest radikalleri temizleme kapasitesinin yüksek olduğu araştırmalarda bildirilmiştir.

Amaç: Literatürde üzüm (Vitis vinifera L.) (VIT) ile ilgili yapılmış çalışmalar olsa da, DXR kaynaklı hasarın kalp dokusu üzerindeki etkisine dair bir çalışmaya raslanmamıştır. Bu nedenle çalışmamızda, ratlarda DXR kaynaklı kalp hasarına karşı VIT çekirdeği ekstraktı etkisinin araştırılması amaçlanmıştır.

Materyal-Metot: 30 adet erkek rat, rasgele her grupta 6 hayvan olacak şekilde 5 gruba ayrılmıştır: Kontrol grubu: Ad libitum su ve yemle beslenen grup. Sham grubu: 14 gün gavajla distile su verilen sıçanlara, deneyin 5. gününde intraperitoneal (i.p.) serum fizyolojik uygulaması yapılan grup. DXR Grubu: Deneyin 5. Günü 15 mg/kg tek doz i.p. DXR uygulanan sıçanlardan oluşan grup. DXR+VIT: 14 gün boyunca gavajla 120 mg/kg Vitis vinifera L. (VIT) çekirdeği ekstraktı uygulanan sıçanlara deneyin 5. Günü 15 mg/kg tek doz i.p. DXR uygulanan sıçanlardan oluşan grup. VIT: 14 gün boyunca gavajla 120 mg/kg Vitis vinifera L. çekirdeği ekstraktı uygulanan sıçanlardan oluşan grup. Son ilaç uygulamasından 24 saat sonra deney hayvanları anestezisi altında sakrifiye edilerek kan ve kalp dokuları alınmıştır. Kan örnekleri santrifüj edilerek serumlarında TOS (Total Oksidan Seviye), TAS (Total Antioksidan Seviye), OSI (Oksidatif Stres İndeksi), TNF-α (Tümör Nekroz Faktörü-α) incelenmiştir. Kalp dokuları ise %10 formolde tespit edildikten sonra rutin doku takip serilerinden geçirilerek bloklanmış ve kesit alınarak histokimyasal ve immunohistokimyasal olarak incelenmiştir.

Bulgular: DXR grubunun histolojik incelenmesinde kas liflerinde düzensizleşme, ayrılma ve bozulma, kas lifleri arasında kollajenöz madde birikimi, damarlarda konjesyon görülmüştür. Tedavi grubu olan DXR+VIT'de bu bulgular önemli derecede azalmıştır.

İmmunohistokimyasal incelemelerde ise kaspaz-3, NF-κB-p65 (Nükleer Faktör-kappa B-p65), TNF-α immunreaktiviteleri değerlendirilmiştir. Kontrol grubuyla karşılaştırıldığında; DXR grubunda kaspaz-3, NF-κB-p65, TNF-α yoğun bir boyanma görülürken, DXR+VIT grubunda boyanmanın şiddeti önemli derecede azalmıştır. Biyokimyasal parametlerde çıkan sonuçlar histopatolojik sonuçlarımızı doğrulamıştır. TOS ve TNF-α düzeyleri DXR grubunda anlamlı artarken, DXR+VIT grubunda ise azalmıştır. TAS düzeyi ise VIT ve DXR+VIT gruplarında anlamlı olarak artmıştır.

Sonuç: DXR'nin apoptotik süreci hızlandırdığı, oksidatif stresi ve inflamasyonu arttırdığı görülmüştür. VIT'in ise kardiyak yeniden yapılanmayı hızlandırdığı ve DXR kaynaklı kalp hasarına karşı koruyucu bir etkisinin olduğu görülmüştür.

Anahtar Kelimeler: Doksorubisin, Vitis vinifera L., Kaspaz-3, NF-κB-p65, TNF-α

Sözlü Bildiri

MCF-7 VE MDA-MB-231 MEME KANSERI HÜCRELERININ METASTATIK KARAKTERINE SILYMARIN'İN ETKISININ 2 BOYUTLU VE 3 BOYUTLU KÜLTÜR YÖNTEMLERIYLE KARŞILAŞTIRMALI OLARAK DEĞERLENDIRILMESI

TUĞÇE ALADAĞ | HÜLYA ÇETİN | FATMA FIRAT

Afyonkarahisar Sağlık Bilimleri Üniversitesi Tıp Fakültesi, tugcealadagg@hotmail.com

Özet

Giriş: Meme kanseri, dünya genelinde kadınlar arasında en yaygın kanser türlerinden biridir ve metastaz, kanserin ölümcül hale gelmesinde kritik bir rol oynamaktadır. Bu çalışmada, silymarin'in iki farklı meme kanseri hücre hattı (MCF-7 ve MDA-MB-231) üzerindeki etkileri incelenmiştir. Hücreler, hem iki boyutlu (2D) hem de üç boyutlu (3D) kültürlerde yetiştirilmiş ve silymarin ile tedavi edilmiştir. Araştırmada, silymarin'in hücrelerin yayılmasını ve metastazla ilişkili gen ve proteinlerin ekspresyonunu nasıl etkilediğini belirlemek için çeşitli analizler yapılmıştır.

Amaç: meme kanseri hücre hatları olan MCF-7 ve MDA-MB-231'de, silymarin'in metastatik özellikler üzerindeki etkilerini araştırmak ve bu etkilerin iki boyutlu (2D) ve üç boyutlu (3D) hücre kültür modellerinde nasıl farklılaştığını değerlendirmektir.

Materyal-Metod: Çalışmada silymarinin etkin dozunu belirlemek amacıyla MTT hücre canlılığı analizi hem 2D hem de 3D kültür metodları kullanılarak tayin edildi. Belirlenen dozlar 2D kültür metodları olan yara iyileşme deneyi, PCR, Western Blot ve immünohistokimyasal analizler kullanılarak epiteliyal mezenkimal geçiş proteinlerinin ifadelerini belirlendi. Eş zamanlı olarak 3D kültür yöntemiyle sferoid oluşturularak transwell hücre göçü, PCR, Western blot ve immünohistokimyasal analizler gerçekleştirildi. Genetik analizleri ve histokimyasal analizler için hücrelere uygulamalar yapılmıştır.

Bulgular: Silymarin hücre göç yöntemiyle değerlendirildi ve hem 2D hem de 3D kültürde iki hücre içinde hücre göçünü yavaşlattı. E-kaderinin ekspresyon azaldığı N-kaderin, vimentin, fibronektin ekspresyon seviyelerinin uygulama sonrasında gruplarda değişiklik gösterdiği görüldü. MMP-9 proteinin mRNA seviyesinde ve protein ifadesinde azalma belirlendi.

Sonuç: Silymarinin meme kanseri hücrelerinde 2D ve 3D uygulamaları sonucunda hücrelerde metastaz ve hücre göçünü hem epiteliyal ve mezenkimal proteinler bakımından hem de hücre göç davranışı bakımından etkilediği görülmüştür.

Anahtar Kelimeler: EMT; Meme Kanseri; Metastaz; Silymarin; 2D ve 3D hücre kültürü

Sözlü Bildiri

YUMURTA TAVUKLARINDA DIYET KALSIYUM, FOSFOR VE MIKROBIYAL FITAZIN BAĞIRSAK MORFOLOJISI ÜZERINDEKI ETKILERI

NURAY VAROL KAYAPUNAR[1] | ŞERİFE ŞULE BAYRAMİÇ[2] | SABİRE GÜLER[1]

1 Bursa Uludağ Üniversitesi Sağlık Bilimleri Enstitüsü Veteriner Histoloji Ve Embriyoloji Abd |2 Bursa Uludağ Üniversitesi Veteriner Fakültesi Hayvan Besleme Ve Beslenme Hastalıkları Anabilim Dalı
vetnvk@gmail.com

Özet

Giriş ve Amaç: Hayvan sağlığını korumak ve bağışıklığı ve üretimi artırmak için kümes hayvanı endüstrisinde farklı zorluklar uygulanmaktadır. Mikrobiyal fitaz takviyesi hem inorganik fitaz oranını düşürmek hem de diğer minerallerin emilimine katkıda bulunmak açısından önemlidir. Bu çalışmada, yeni izole edilmiş bir mikrobiyal fitaz, kalsiyum (Ca2+) ve kullanılabilir fosfor (AP) ile birlikte diyete farklı konsantrasyonlarda eklendi ve bu takviyenin bağırsak emilim kapasitesi ve Ca2+ bağlama kapasitesi üzerindeki etkileri, duodenum ve ileumun morfolojik ölçümleri ve immünohistokimyasal incelemesi yoluyla araştırıldı.

Materyal-Yöntem: Bu amaçla, 90 Lohmann LSL-White yumurta tavuğu üç ana diyet grubuna ayrıldı: 1. Standart Ca2+ ve AP (Ca+AP), 2. Standart Ca2+ ve düşük AP (Ca+düşük AP) ve 3. Düşük Ca2+ ve düşük AP (düşük Ca+düşük AP). Bu üç grup ayrıca her biri üç fitaz alt grubuna ayrıldı (fitazsız [Phy-], ticari fitaz [CP] ve mikrobiyal fitaz [MP]). Deneyin sonunda hayvanlar ötanazi edildi ve duodenum ve ileum örnekleri sabitlendi ve histolojik inceleme için işlendi. Villus yüksekliği, kript derinliği, toplam mukoza kalınlığı ve villus genişliği ölçüldü ve villus yüksekliği: kript derinliği oranı ve villus emilim alanı hesaplandı. Duodenum ve ileumdaki kaldesmon ekspresyonu ayrıca immünohistokimyasal olarak araştırıldı.

Sonuçlar: Sonuçlar, Ca+AP+MP ile beslenen kuşlarda villus yüksekliğinin, toplam mukoza kalınlığının ve villus emilim alanının arttığını ($p \leq 0,05$) gösterdi. MP ile tedavi edilen gruplarda daha güçlü kaldesmon ekspresyonu gözlemlendi. Bacillus megaterium EBD 9-1 bakterisinden üretilen MP'nin Ca2+ ve AP kullanımını artırdığı ve bu nedenle bu makromineraller yetersiz kullanıldığında yararlı bir rol oynayabileceği sonucuna vardık.

Sonuç: Fitaz uygulamasının duodenum ve ileumun histomorfolojisi üzerinde etkili olduğunu ve yeni izole edilen MP uygulamasının villus yüksekliği, kript derinliği, toplam mukoza, VH:CD oranı, villus genişliği ve villus yüzey alanını olumlu yönde etkilediğini gözlemledik. Standart seviyelerde Ca2+ ve AP sağlanması, eklenen MP'nin etkinliğini artırdı ve böylece bağırsak mukozası morfolojisi ve emilim kapasitesini iyileştirdi.

Sözlü Bildiri

SIÇANLARDA SIKLOFOSFAMID İLE OLUŞTURULAN DENEYSEL OVARYUM HASARI ÜZERINE GALLIK ASIT'IN ETKILERI

ELİF KOYUN ALVUROĞLU[1], DERYA ÖZTÜRK OKATAN[1], ELİF ŞAHİN[2], AHMET ALVER[2]

1Karadeniz Teknik Üniversitesi Tıp Fakültesi, Histoloji ve Embriyoloji Anabilim Dalı, Trabzon
2 Karadeniz Teknik Üniversitesi Tıp Fakültesi, Tıbbi Biyokimya Anabilim Dalı, Trabzon
elifkyn.61@gmail.com

Özet

Giriş: Siklofosfamid (CP) malign, otoimmün hastalıkların tedavisinde yaygın kullanılmaktadır (1). CP reaktif oksijen radikallerini ve apopitozu arttırak ovaryumda hasara neden olur. Folikül dejenerasyonuna, folikül sayısında azalmaya, prematür ovaryan yetmezliğine, menstrüel bozukluklara, metabolik anormalliklere, infertiliteye neden olabilir (2,3). Gallik asit (GA) yeşil çay, üzüm, mango ve cevizde bulunan önemli bir polifenolik maddedir (4). GA, güçlü ve doğal bir antioksidandır ve serbest radikallerin temizlenmesi, antiinflamatuvar ve antiapoptotik gibi bir dizi biyolojik ve farmakolojik aktiviteye sahiptir (5).

Amaç: Bu çalışmada; sıçanlarda CP uygulanması ile oluşan ovaryum hasarına karşı GA'nın profilaktik etkilerinin histolojik ve biyokimyasal yöntemlerle araştırılması amaçlandı.

Metotlar: Araştırma için 32 adet Sprague Dawley ırkı erişkin dişi sıçan rastgele 4 eşit gruba (Kontrol, CP, GA, CP+GA) ayrıldı. Tüm denekler deneyin 1. ve 8. gününde tartıldı. Kontrol grubuna herhangi bir uygulama yapılmadı. CP grubuna deneyin 7. gününde 150mg/kg intraperitoneal CP uygulandı. GA grubuna deneyin 1. gününden itibaren 7 gün boyunca günlük 20mg/kg GA oral gavaj yoluyla uygulandı. CP+GA grubuna deneyin 1. gününden itibaren 7 gün boyunca, oral gavaj yoluyla günlük 20mg/kg GA ve 7. günde 150mg/kg intraperitoneal CP uygulandı. Deneyin 8. günü sıçanlardan kan örnekleri alındı ve ovaryumları çıkarıldı. Sağ ovaryum histopatolojik değerlendirmeler için sol ovaryum biyokimyasal analiz için kullanıldı. Kesitler hematoksilen-Eozin, Masson trikromu, Periyodik Asit-Schiff ve TUNEL yöntemiyle boyandı. Histopatolojik değerlendirmeler, folikül sayımı ve skorlama yapıldı. Biyokimyasal analizde glutatyon peroksidaz (GPX), süperoksit dismutaz (SOD), katalaz (CAT), malondialdehit (MDA), doku anti Müllerian hormon (AMH), serum AMH düzeylerine bakıldı.

Bulgular: CP grubunda foliküler hücre dejenerasyonu, kontrol ve GA grubuna göre anlamlı olarak artmıştı. CP+GA grubunda foliküler hücre dejenerasyonu, CP grubuna göre anlamlı olarak azalmış olup, kontrol ve GA grubuna göre yüksekti. GA grubu kontrol grubuna benzer morfolojideydi. CP grubunda Aİ kontrol ve CP+GA gruplarına göre artmıştı. Primordiyal folikül sayısı CP grubunda, kontrol ve CP+GA gruplarına göre azalmıştı. CP grubunda kontrol ve GA gruplarına göre unilaminar primer folikül sayısı azalmış, atretik folikül sayısı artmıştı. CP+GA grubunda unilaminar primer folikül sayısı kontrol grubuna göre azalmış olup atretik folikül sayısı kontrol ve GA gruplarına göre yüksekti. CP grubunda MDA kontrol ve GA gruplarına göre yüksekti. CP+GA grubunda MDA seviyesi CP grubuna göre azalmıştı. SOD aktivitesi; CP grubunda kontrol, CP+GA ve GA gruplarına göre azaldı. CAT aktivitesi,

CP+GA ve GA gruplarındadiğer gruplara göre yüksekken, CP grubunda kontrol grubuna göre azalmıştı. Doku AMH değerleri CP grubunda kontrol grubuna göre azaldı. Serum AMH değeri GA grubunda diğer gruplarına göre yüksekti.

Sonuçlar: CP'nin erişkin sıçan ovaryumunda neden olduğu folikül hücre hasarını önlemede GA'nın etkili olabileceği sonucuna varıldı.

*Bu çalışma Karadeniz Teknik Üniversitesi Bilimsel Araştırma Projeleri Koordinasyon Birimi tarafından desteklenmiştir (Proje No: TTU-2021-9805).

Sözlü Bildiri

MORINGA OLEIFERA İNSAN GLIOBLASTOMA HÜCRE HATLARINDAKI AKT-FOXO3A-BIM YOLAĞINA ETKI EDER MI?

DİLŞAD ARISOY DEMİR[1] | NURAY BOSTANCIERİ[2] | HÜLYA ÖZTATLICI[2] | BÜŞRA ŞEN HALICIOĞLU[2] | MEHMET YÜNCÜ[2]

[1]Gaziantep Şehir Hastanesi Üremeye Yardımcı Tedavi Merkezi | [2]Gaziantep Üniversitesi Tıp Fakültesi
dr.dilsadarisoydemir@gmail.com

Özet

Glioblastom, WHO tarafından evre 4 olarak kabul edilen, mevcut tedavilere rağmen hala mortal bir tümördür. Moringa oleifera birçok kanser türünde antikanser ve apoptoz indükleyici etkileri keşfedilmiş bir bitkidir. Bu çalışmada Moringa oleifera'nın, glioblastomun tedavi seçeneklerine katkı sağlamak üzere patogenezinde bilinen AKT/FOXO3a/Bim yolağı üzerine etkisi araştırıldı.

Glioblastom hücre hatları olan U87-MG (epitelyal kökenli) ve T98-G (fibroblast kökenli) in vitro ortamda kültüre edildi. U87-MG (kontrol grubu) ve U87-MG+MOLE (deney grubu) ile T98-G (kontrol grubu) ve T98-G+MOLE (deney grubu) oluşturuldu.

Kontrol ve deney gruplarında Image J yazılımı ile immuositokimyasal optik dansite ölçümleri ve Colony Count J yazılımı ile koloni oluşum yüzdeleri değerlendirildi. Ayrıca kontrol ve deney gruplarında RT-qPCR analiziyle mRNA seviyeleri karşılaştırıldı.

Deney gruplarında kontrol grubuna göre immuositokimyasal optik dansite ölçümlerinde her iki hücre hattında AKT'nin azalışı, FOXO3a ve Bim'in artışı istatistiksel olarak anlamlı bulundu. Yine deney gruplarında kontrol grubuna göre koloni oluşum yüzdelerindeki azalma da anlamlıydı. Yapılan RT-qPCR analizinde deney gruplarında kontrol gruplarına göre mRNA seviyeleri karşılaştırıldığında U87-MG+MOLE grubunda Akt seviyesindeki azalış ve Foxo3a ve Bim seviyesindeki artış istatistiksel olarak anlamlıydı. Ancak T98-G+MOLE grubunda Akt seviyesinde azalış ve Bim m RNA seviyesindeki artış istatistiksel olarak anlamlı saptanırken Foxo3a seviyesindeki artış anlamlı değildi.

Sonuç olarak Moringa oleifera'nın U87-MG ve T98-G glioblastom hücre hatlarında apoptozu AKT/FOXO3a/Bim yolağı üzerinden tetiklediği tespit edildi.

Anahtar Kelimeler: U87-MG ve T98-G, AKT/FOXO3a/ Bim Yolağı, Moringa oleifera.

Sözlü Bildiri

STREPTOZOTOSIN ILE SIÇANLARDA OLUŞTURULAN T1DM MODELINDE CARVACROL'ÜN PANKREAS HÜCRELERINDEKI PI3K/AKT YOLAĞI, GLUT-2 VE INSULIN EKSPRESYON DÜZEYINE ETKILERININ ARAŞTIRILMASI

DAMLA IRMAK | KAYIHAN KARAÇOR

Gaziantep Şehir Hastanesi Üyte Merkezi | Düzce Üniversitesi Histoloji Ve Embriyoloji Anabilim Dalı
damlasaybasili@gmail.com

Özet

Giriş: Dünyada görülme sıklığı hızla artmakta olan diabetes mellitus (DM) hiperglisemi ile seyrederek birçok metabolik hastalığı tetikleyebilen önemli bir endokrinolojik bozukluktur. Tedavisinde insülin ve oral anti-diyabetikler kullanılsa da uzun süreçte yan etkileri nedeniyle organlara zarar vermektedir. Günümüzde bu yan etkileri minimize etmek ve hastaların yaşam kalitesini yükseltmek için alternatif tedaviler ön plana çıkmaktadır. Kekik yağında bulunan Carvacrol'ün (CRV), antidiyabetik özelliği daha önceki çalışmalarda gösterilmiştir. Ancak pankreatik dokuda CRV'nin bu etkiyi hangi yolak üzerinden gerçekleştirdiği bilinmemektedir.
Amaç: Bu çalışmada diyabetik ratlarda CRV'nin, kan glikoz seviyesi ve hücresel düzeyde etkilediği mekanizmaların daha iyi anlaşılabilmesi için pankreatik dokuda PI3K/Akt yolağı, Glut-2 ve Insulin proteinlerinin ekspresyon değişimlerinin araştırılması amaçlanmıştır.
Materyal-Metot: 40 Wistar Albino rat rastgele 5 gruba ayrıldı: Sham, Kontrol CRV 40 (40 mg\kg CRV), Streptozotosin (STZ), STZ + CRV 20 (20 mg\kg CRV) ve STZ + CRV 40 (40 mg/kg CRV). Deney başlangıcında STZ ile belirtilen gruplara 55 mg/kg Streptozotosin intraperitoneal olarak verilerek tip I diyabet modeli oluşturuldu. CRV belirtilen dozlarda gavaj yolu ile 6 hafta uygulandı. Belirli aralıklarla hayvanların kan glikoz seviyesi kuyruk veninden ölçüldü. Deney sonunda hayvanlar sakrifiye edilerek pankreas dokusunda PI3K, pAkt, Glut-2 ve Insulin antikorları kullanılarak immünohistokimya metodu uygulandı.
Bulgular: 6 haftanın sonunda STZ grubunun kan glikoz ortalaması 562 mg/dL iken STZ +CRV 40 grubunda 348 mg/dL; STZ + CRV 20 grubunda ise 230 mg/dL tespit edilmiş ve CRV'nin farklı dozlarının STZ grubuna kıyasla kan glikoz düzeyini istatistiksel olarak anlamlı şekilde düşürdüğü belirlendi ($p<0.05$). Ayrıca CRV'nin 20 mg/kg/gün uygulanmasının 40 mg/kg/gün'e kıyasla kan glikoz düzeyini düşürmede daha etkili olduğu belirlendi ($p<0.05$). Diyabetik grupta kontrole göre azalan PI3K, pAkt, Glut-2 ve Insulin proteinlerinin ekspresyonlarının 20 mg/kg ve 40 mg/kg CRV'nin 6 hafta uygulanması ile anlamlı olarak arttığı belirlendi ($p<0.05$).
Sonuç: Bu çalışmada Carvacrol'ün daha önceki çalışmalarda bildirilen dozlardan daha düşük bir dozda pankreastan insülin salınımını tetikleyerek kan glikoz seviyesini düşürmede etkili olabileceği belirlenmiştir. Sonuç olarak Carvacrol'ün, pankreatik dokuda PI3K/Akt yolağını aktive etmesiyle, β hücrelerinde Glut-2 ve Insulin ekspresyon düzeylerinin artmasını sağlamış olabileceğini ve bunların artışının da kan glikoz seviyesindeki düşüşü açıklayabileceğini öngördük.

Anahtar Kelimeler: Diabetes Mellitus, Pankreas, Streptozotosin, Carvacrol, PI3K, Akt, Glut2, Insulin, İmmünohistokimya

Sözlü Bildiri

ERKEN VE GEÇ BAŞLANGIÇLI PREEKLAMPSI VAKALARINDA TIGIT, PVRIG, CD155, CD112 EKSPRESYONLARININ DEĞERLENDIRILMESI

HÜLYA ÇETİN | YELİZ ARMAN KARAKAYA | ÖZLEM KOŞAR CAN | AYŞEN BUKET ER URGANCI | İLKNUR LAFCI

Pamukkale Üniversitesi, ilknurlafci93@gmail.com

Özet

Giriş: Preeklampsi (PE), daha önce normotansif olan kadınlarda gebeliğin 20.haftasından sonra hipertansiyon ve proteinüri ile karakterize bir hastalıktır. Bağışıklık sistemi yanıtı kendine karşı toleransı sürdürmek ve doku bütünlüğünü korumak için farklı düzenleyici mekanizmalar tarafından kontrol edilir. Sinyallerde ya da reseptörlerde meydana gelebilecek bir aksaklık homeostazın bozulmasına neden olabilmektedir. T hücresi Ig ve ITIM alanı (TIGIT), 2009 yılında bağımsız üç farklı grup tarafından doğal öldürücü hücreler üzerinde inhibe edici bir reseptör olarak keşfedilmiştir. Poliovirus reseptör ilişkili immunoglobulin alanı (PVRIG, CD112R), 2016 yılında tanımlanmıştır. Genellikle T hücresi üzerinde eksprese edilir ve T hücresi aracılı sinyalleri inhibe eder. Sadece yüksek afiniteyle PVRL2 (Poliovirus reseptör ligand) ligandına bağlanır.

Amaç: Bu reseptörlerin tümör hücresinde eksprese olması ve bu yolla immün mekanizmalardan korunmasından yola çıkarak gebelikle ilişkili bir sendrom olan preeklampside daha önce çalışılmamış immün hücre reseptörlerinden TIGIT ve PVRIG varlığı ve bu reseptörlerin ligandları olan CD155 ve CD112 ekspresyon düzeylerinin araştırılmasının gelecekte preeklampsi ve bununla ilişkili hastalıklarda bir tedavi yöntemi için kaynak oluşturabileceğini düşünmekteyiz.

Materyal Metod: Çalışmamızda 2017 yılı sonrasında Paü Kadın Hastalıkları ve Doğum Anabilim Dalı'nda gerçekleştirilmiş doğumlara ait, preeklamptik plasenta materyalleri kullanılmıştır. Örnekler kontrol (n=24) grubu, erken preeklampsi (EOP, n=19) grubu, geç preeklampsi (LOP, n=20) grubu olarak 3'e ayrılmıştır. Plasenta materyalleri TIGIT, PVRIG, CD155, CD112 antikorlarıyla immunohistokimyasal (IHC) olarak boyanmış ve aynı materyalde TIGIT, PVRIG, CD155, CD112 gen ekspresyonları RT-PCR analiziyle değerlendirilmiştir.

Bulgular:İmmunohistokimyasal olarak H sokoru hesaplanmıştır. (Tablo 1) CD112 ve CD155 ekspresyonu kontrol grubuna göre hem EOP hem LOP grubunda azalmıştır. PVRIG ekspresyonu ise kontrol grubuna göre her iki preeklampsi grubunda artmıştır.
Kontrol grubuna göre CD112, CD155, TIGIT ve PVRIG genleriyle yapılan değerlendirmede EOP grubunda tüm genlerin ekspresyonu 2 kat artmıştır. LOP grubunda ise tüm genlerin ekspresyonu yarıya düşmüştür.

Sonuç: PVRIG seçici olarak CD112 reseptörüne bağlanmaktadır. H skoru tablosunda PVRIG ekspresyonu kontrole göre EOP ve LOP grubunda artmış görünmektedir. Buna karşılık reseptörü CD112 kontrole göre EOP ve LOP grubunda azalmış görünmektedir. Hücre

yüzeyinde PVRIG ekspresyonu artsa da karşılığında bağlanacağı reseptör yeterli eksprese olmağı için yeterli yanıt oluşmamaktadır. TIGIT yüzey ekspresyonu şiddeti çok düşük düzeyde olduğu için İHC olarak yorumlanamamıştır. Önceki çalışmaların ışığında preeklampside bu reseptörlerin ekspresyonlarının azalmasını beklemekteyiz. Ancak EOP grubunda reseptör ekspresyonları iki katına çıkmıştır. Bu durum Erken preeklampsi için farklı fizyolojik süreçlerin olduğunu düşündürmektedir. Bu nedenle RT-PCR sonuçlarına göre bu genlerin erken ve geç başlangıçlı preeklampsi için biyobelirteç olabileceği düşünülmüştür. İşlevleri aydınlatılmamış bu reseptörlerin hastalığın tanı ve tedavisinde kullanılabilmesi için detaylı araştırmalar yapılması gerekmektedir.

Sözlü Bildiri

PREEKLAMPSININ GÖBEK KORDONU MEZENKIMAL STROMA HÜCRELERININ VEGFR-2 İFADESI ÜZERINE ETKISI

İBRAHİM ALPTEKİN [1],BİLGE SERDAROĞLU [1], DERYA UYAN HENDEM[3], EZEL ERKAN [1], FERDA TOPAL ÇELİKKAN [1] , DİLEK ŞAHİN[2], ALP CAN [1]

1 Ankara Üniversitesi Tıp Fakültesi, Histoloji ve Embriyoloji Anabilim Dalı, Üreme biyolojisi ve kök hücre laboratuvarı, Sıhhiye, Ankara
2 Ankara Şehir Hastanesi, Kadın Hastalıkları ve Doğum Anabilim Dalı, Perinatoloji, Çankaya, Ankara
3 Şanlıurfa Eğitim ve Araştırma Hastanesi, Kadın Hastalıkları ve Doğum Anabilim Dalı, Perinatoloji, Yenice, Şanlıurfa
ibrahimalptekin4221@gmail.com

Özet

Giriş: Erken embriyon döneminde embriyon dışı mezoderm kaynaklı uyarımla damarlanma odakları gelişir (vaskülogenez) ve ağ yaparak genişler (anjiyogenez). Göbek kordonu stroması, bağlayıcı sapın gelişmesiyle içerisinde embriyon dışı mezoderm kökenli stromayı barındırarak gelişir; bu esnada umbilikal damarların gelişmesinde rol alır. Stroma, farklı özellikleri olan bölgeler subamniyotik stroma (SA); intervasküler stroma (IVC), perivasküler stroma (PVC) içerir ve her bir bölgede multipotent özellikte stroma hücreleri bulunur (iGK-MSH). Bu hücreler üzerinde yapılan in vitro çalışmalar, hücrelerin bölgesel farklılıklara (proliferasyon, farklanma, immün düzenleme) sahip olduğunu göstermektedir ve bu farkın anjiyogenez potansiyeline de yansıması olasıdır. Ancak bu farklılığın varlığı ve niteliği henüz ortaya konmamıştır. VEGFR-2, iGK-MSH'da bulunur ve uyarılara yanıt verme potansiyelini gösterir. Bu uyarılar gelişimin ilerleyen dönemlerinde farklı etkilere bağlı değişim gösterebilir. Preeklampsi gebeliğin 24. haftasından sonra ortaya çıkabilen, plasenta odaklı bir gelişme anomalisidir ve "kusurlu anjiyogenez" sonucunda ortaya çıktığı kabul edilir. Bu sayede iGK-MSH'ın farklanma potansiyelini etkileyebilir. Bu konuda yapılmış olan çalışmalar endotel hücreleri ve damara ilişkin yapılarla kısıtlıdır ve bugüne kadar bu sürecin nicel olarak karşılaştırmasını yapan bir çalışma literatürde bulunmamaktadır.

Amaç: Biz bu çalışmamızda erken ve geç dönem preeklampsi olgularının göbek kordonu stromasının farklı bölgelerinde (SA, IVC, PVC) VEGFR-2 dağılımı ve yoğunluğunu nicel karşılaştırmasını yapmayı amaçladık.

Materyal-Metod: Paraformaldehit (%3,5) ile fikse edilen üç ayrı gruptan alınan 11´ar göbek kordonunun 10µm'lik kriyokesitleri VEGFR-2 antikoru işaretlendi ve kesitler konfokal süper çözünürlük mikroskobunda 15 ardışık görüntü alınarak 5.75µm kalınlığında üç boyutlu küme olarak kaydedildi. görüntü. Alınan görüntülerden yapılan entegrasyon analizleri sonucu elde edilen sinyal yoğunlukları SPSS 23.0 programında nicel olarak analiz edildi. P<0,05 anlamlı kabul edildi.

Bulgular: Kontrol gruplarında, SA (13,74±1,11), IVC (16,67±1,71), PVC (18,00±2,04); EPE gruplarında (13,63±1,667), IVC (15,75±,07), PVC (17,30±2,12); GPE olgularında SA (16,01±1,36), IVC (19,86±2,33), PVC (1,78±3,06) olarak ölçüldü. Bölgeler arasındaki sinyal yoğunluğu değerleri karşılaştırıldığında SA ile IVC (p=0,003, p=0,031, p=0,000) ve PVC (p=0,008, 0,02, p=0,001) arasındaki farklar istatistiksel olarak anlamlı bulundu. SA, IVC ve

PVC gruplarına ait sinyal yoğunluğu ortalamalarında olgu türüne bağlı olarak (her alan ayrı ayrı olgu türüne bağlı karşılaştırıldı) meydana gelen farklar istatistiksel olarak anlamlı bulunmadı. (p=0,431; 0,355; 0,395).

Sonuç: Göbek kordonu stromasının farklı bölgeleri VEGFR-2 ifadesi bakımından farklıdır. Ancak, kontrol ve preeklampsi olguları arasında incelenen bölgelerde bir farklılığın bulunmaması stromanın farklı bölgelerindeki IGK-MSH´lerin anjiyogenik uyarılara yanıt verme potansiyelinin farklı olabileceğini göstermekte ve preeklampsinin şiddeti ve başlangıç zamanının bu potansiyeli etkilemediğini çağrıştırmaktadır.(Bu çalışma Ankara Üniversitesi Bilimsel Araştırma Projeleri Koordinatörlüğü TSG 2545 nolu güdümlü proje ve 121S821 nolu TÜBİTAK 1001 projesiyle desteklenmiştir.)

Sözlü Bildiri

İNSAN GÖBEK KORDONU MULTIPOTENT STROMA HÜCRELERI KAYNAKLI EKZOZOMLARIN İN-VITRO HIPOKSIK VE NORMOKSIK KOŞULLARDA ENDOTEL HÜCRELERI ÜZERINDE ANJIYOGENEZ ETKINLIĞININ SINANMASI VE KARŞILAŞTIRILMASI

BİLGE SERDAROĞLU[1] | İBRAHİM ALPTEKİN[1] | EZEL ERKAN[1] | MOHAMMADREZA DASTOURI[2] | ŞERİFE ESRA ÇETİNKAYA[3] | MESUT AKYOL[4] | ALP CAN[1] | FERDA TOPAL ÇELİKKAN[1]

1 Ankara Üniversitesi Tıp Fakültesi Histoloji Ve Embriyoloji Anabilim Dalı Üreme Ve Kök Hücre Laboratuvarı, Altındağ, | 2 Ankara Medipol Üniversitesi Tıp Fakültesi, Tıbbi Biyoloji Anabilim Dalı, Altındağ, Ankara | 3Ankara Üniversitesi Tıp Fakültesi Kadın Hastalıkları Ve Doğum Anabilim Dalı, Mamak, Ankara | 4 Ankara Yıldırım Beyazıt Üniversitesi Tıp Fakültesi, Biyoistatistik Ve Tıbbi Bilişim Anabilim Dalı, Etlik, Ankara
bilgeserdaroglu7@gmail.com

Özet

Giriş: MSH'ler (Multipotent stroma hücreleri), insan göbek kordonu (iGK) dahil olmak üzere birçok dokudan izole edilirler. MSH'ler etkilerini sadece doğrudan hücre-hücre etkileşimleri yoluyla değil, aynı zamanda ekzozomlar aracılığıyla parakrin olarak da gösterir. Ekzozomlar, 30-200 nm çapında lipid çift zarla çevrili, içeriğinde proteinler, lipitler, metabolitler ve nükleik asitler gibi biyomoleküller bulunan hücre dışı veziküllerdir. Ekzozomların içeriği, elde edildikleri hücre tipi ve dış çevre koşullarına göre değişebilir ve dolayısıyla bu içerik düzenlenebilir. Anjiyogenez, mevcut damarlardan yeni damarların oluştuğu süreçtir. MSH'den elde edilen ekzozomların in-vitro ve in-vivo anjiyogenik kapasiteyi artırdığı gösterilmiştir. Ayrıca, normoksik ve hipoksik ön koşullandırmaya tabi tutulan MSH'den elde edilen ekzozomların farklı anjiyojenik kapasiteyi artırma düzeyleri olduğuna dair çalışmalar bulunmaktadır.

Amaç: Normoksi (%21 O_2) ve hipoksi (%1 O_2) koşullarındaki iGK-MSH'den elde edilen ekzozomların 50 µg/mL ve 200 µg/mL konsantrasyonlarda insan umbilikal ven endotel hücreleri (HUVEC) üzerinde in-vitro tüp formasyonu oluşturma etkinliğini karşılaştırmayı amaçlıyoruz.

Materyal-Metod: Eksplant kültür ile elde edilen pasaj$_{4\text{-}5}$ iGK-MSH, 48 saat boyunca %10 ekzozom içermeyen fetal sığır serumu içeren kültür ortamı ile normoksi ve hipoksi koşullarında inkübe edildi ve sonrasında toplanan kültür ortamından diferansiyel ultrasantrifüjle ekzozomlar ayrıştırıldı ve taramalı elektron mikroskobu, Western blot, MicroBCA, ayarlanabilir dirençli darbe algılama sistemiyle karakterize edildi. HUVEC, Matrigel® ile kaplı ortama ekilerek 50 µg/mL ve 200 µg/mL konsantrasyonlarda ekzozom içeren endotel bazal medium (EBM) ile kültüre edildi. Negatif kontrol olarak EBM, pozitif kontrol olarak ekzozom içermeyen, büyüme faktörleri içeren EBM kullanıldı. 12. saatte görüntülenen anjiyogenez deneylerinde, ImageJ Angiogenesis Analyzer eklentisiyle anjiyogenik kapasiteyi gösteren toplam uzunluk, düğüm sayısı, ağ sayısı ve ağ alanı değerleri ölçüldü. Veriler SPSS 22.0 ile analiz edildi. $p<0.05$ istatistiksel olarak anlamlı kabul edildi.

Bulgular: iGK-MSH'den, normokside 21,21µg/10^{6}hücre, hipokside 11,65µg/10^{6}hücre ekzozom proteini elde edildi. Ölçülen parametrelerde normoksik ve hipoksik grupların kendi

içinde iki ekzozom konsantrasyonu arasında anjiyogenik kapasitesiteyi gösteren değişkenler açısından istatistiksel olarak anlamlı fark belirlenmedi. Hipoksi grubundaki 50 µg/mL konsantrasyonunun anjiyogenik kapasitesinin, normoksi gruplarından düşük olduğu bulundu.
Sonuç: iGK-MSH'ın, normoksi koşullarında hipoksi koşullarına göre daha fazla miktarda ekzozom ürettiği ve normoksi koşullarında elde edilen ekzozomların, hipoksi koşullarında elde edilen ekzozomlara göre anjiyogenezi arttırdığı sonuçları ortaya çıktı. Ayrıca ekzozomların O_2 düzeyinden bağımsız olarak 50-200 µg/mL konsantrasyonlarının tüp oluşturma etkinlikleri benzer bulundu. %1 O_2 düzeyindeki hipoksinin, ekzozomların içeriğinde bulunan anjiyogenezi başlatıcı ve devam ettirici faktörlerin miktarını olumsuz yönde etkilemiş olabileceği; doz artırımının bu olumsuz etkiyi azaltıcı yönde bir etki yaptığı düşünülebilir. Bu sonucu aydınlatmak amacıyla daha büyük bir örneklemle farklı ekzozom konsantrasyonu ve O_2 düzeyleriyle gerçekleştirilen hipoksi deneyleri planlanabilir.

Sözlü Bildiri

DEHIDROEPIANDROSTERON İLE İNDÜKLENEN SIÇAN POLIKISTIK OVER SENDROMU MODELINDE PHOENIXIN-14 PEPTIDININ OVARYUM MORFOLOJISI ÜZERINE ETKILERI

MİRAY BERBER[1] | ASLIGÜL BULUT[1] | GONCA TOPAL[1] | GAMZE GÜNEY ESKİLER[2] | DUYGU GÖK YURTSEVEN[3]

[1]Bursa Uludağ Üniversitesi Sağlık Bilimleri Enstitüsü |[2] Sakarya Üniversitesi Tıp Fakültesi Tıbbi Biyoloji Anabilim Dalı | [3]Bursa Uludağ Üniversitesi Tıp Fakültesi Histoloji Ve Embriyoloji Anabilim Dalı
aslibulut97@hotmail.com

Özet
Polikistik Over Sendromu (PKOS), üreme çağındaki kadınların üreme ve endokrin sistemlerini etkileyen heterojen metabolik bozukluklardan biridir. Phoenixin (PNX), hipotalamusta üretilen ve hipofiz gonadotropları üzerinde doğrudan etki göstererek üremenin regülasyonunda görev alan bir nöropeptiddir. Çalışmamızda dehidroepiandrosteron (DHEA) ile indüklenen polikistik over sendromu (PKOS) sıçan modelinde, Phoenixin-14 peptidinin PKOS kaynaklı olası fertilite değişikliklerine karşı ovaryum dokusu üzerindeki iyileştirici etkinliğinin gösterilmesi amaçlandı.

30 adet yetişkin dişi sıçan; kontrol, sham, PKOS, PNX-14 (2,5 nmol), PNX-14 (5 nmol) ve PNX-14 (30 nmol) şeklinde 6 gruba ayrıldı. Kontrol grubuna herhangi bir işlem uygulanmadı. Sham grubuna 0,01 ml %95 etanol ve 0,09 ml susam yağı karışımı subkutan olarak verildi. PKOS modeli, 6 mg/100 g vücut ağırlığı dozunda 21 gün boyunca subkutan DHEA uygulamasıyla oluşturuldu. PNX-14 dozları ise intraperitoneal olarak uygulandı. Deneklere ait doku ve kan örnekleri biyokimyasal, moleküler, histolojik ve immünohistokimyasal açıdan incelendi.

PKOS grubu deneklerin östrus siklusu döngülerinin bozulduğu ve vücut ağırlıklarının istatistiksel olarak arttığı belirlendi. Biyokimyasal parametrelerden serum folikül stimülan hormon (FSH), estradiol (E2) ve progesteron (PRG) düzeylerinin azaldığı, luteinizan hormon (LH):FSH oranları ile testosteron (T) seviyelerinin arttığı tespit edildi. Tedavi gruplarının, deneklerin östrus siklusunu düzelterek, serum seviyelerini kontrole yaklaştırdığı gözlendi. Hücre proliferasyon biyobelirteci olarak PCNA protein ekspresyonları değerlendirildiğinde, PKOS grubundaki ekspresyon seviyelerinin kontrol ve sham gruplarına göre azaldığı, sadece 5 nmol'lük PNX-14 doz grubundaki etkinin anlamlı olduğu bulundu. İmmünohistokimyasal veriler de bu bulguyu destekledi. Histomorfolojik analizler sonucunda, DHEA etkisiyle bozulan folikülogenezin PNX-14 peptidinin farklı dozları ile düzelebileceği saptandı.

Sonuç olarak, DHEA kaynaklı PKOS sıçan modelinde ovaryum dokusunda meydana gelen histopatolojik değişikliklerin, PNX-14 peptidinin teröpatik etkisi ile iyileştirilebileceği bulundu. PKOS kaynaklı anormal folikülogenez ve anovulasyonda, PNX-14 peptidinin gelecekte PKOS tedavisi için kullanılabilecek potansiyel bir hedef olabileceğini düşünmekteyiz.
Bu çalışma, Bursa Uludağ Üniversitesi BAP birimi tarafından TYL-2023-1558 nolu proje ile desteklenmiştir.

Sözlü Bildiri

DENEYSEL EPILEPSI MODELINDE KORTEKS VE HIPOKAMPÜSTE NÖROPLASTIN, TRAF6, GLUA1, GABA(A/B) RESEPTÖRLERI ÜZERINE RUTININ ETKILERININ IMMÜNOHISTOKIMYASAL VE MOLEKÜLER ANALIZI

ASLI OKAN[1] | SÜMEYYE UÇAR[2] | HABİBA EYVAZOVA[3] | A.CİHANGİR UĞUZ[4] | ŞÜKRÜ ATEŞ[5] | ENES AKYÜZ[6] | SEHER YILMAZ[5] | ZÜLEYHA DOĞANYİĞİT[1]

[1]Yozgat Bozok Üniversitesi Tıp Fakültesi, Histoloji Ve Embriyoloji Anabilim Dalı, Yozgat, Türkiye | [2]Erciyes Üniversitesi Tıp Fakültesi Anatomi Anabilim Dalı, Kayseri, Türkiye | [3]Sağlık Bilimleri Üniversitesi, Uluslararası Tıp Fakültesi, İstanbul, Türkiye | [4]Karamanoğlu Mehmetbey Üniversitesi Tıp Fakültesi Biyofizik Anabilim Dalı, Karaman, Türkiye | [5]Yozgat Bozok Üniversitesi Tıp Fakültesi Anatomi Anabilim Dalı, Yozgat, 66100, Türkiye | [6]Wisconsin-Madison Üniversitesi Çocuk Hastalıkları Bölümü | asli.okan@yobu.edu.tr

Özet

Giriş: Epilepsi, merkezi sinir sisteminde anormal nöral aktivite ile karakterize bir nörolojik bozukluktur. Epileptik nöbetler, uyarıcı ve engelleyici iletim dengesinin bozulması nedeniyle sinir hücrelerinin (nöronların) eşzamanlı ateşlemelerinin artmasından kaynaklanır. Ek olarak, nöbet geçiren bireyler, bilişsel işlevlerde bozulmaya yol açabilen hipokampüs gibi beyin yapılarında ilerleyici hasar riski altındadır. Bu hasar, nöronlar arasındaki bağlantıların (sinapslar) dahil olmasından kaynaklanabilir. Ancak, hastalığın altında yatan kesin moleküler mekanizma hala tam olarak anlaşılamamıştır.

Amaç: Bu çalışmada, yaygın olarak tüketilen bir flavonoid olan rutinin antiepileptik etkilerini deneysel epilepsi modelinde korteks ve hipokampüste Nöroplastin, Tümör nekroz faktörü reseptörü ile ilişkili faktör 6 (TRAF6), glutamate A1 (GLUA1) ve gama-aminobütirik asit A ve B (GABA A/B) reseptörlerinin ekspresyon düzeylerini nasıl değiştirdiğini göstererek belirlemeyi amaçladık.

Materyal- Metod: Çalışmamızda 2 aylık, 250-300 gr ağırlığında, 72 adet Sprague Dawley ırkı dişi ve erkek sıçan kullanılarak her grupta 18 (9 dişi ve 9 erkek) sıçan olmak üzere 4 grup oluşturuldu: Kontrol grubu, Rutin grubu, Pentilentetrazol Status Epileptikus (PTZ SE) grubu ve PTZ SE + Rutin grubu. Deneysel epilepsi modellerinde nöbet yoğunluğunu değerlendirmek için Racine Skorlama yöntemi yapıldı. Beyin dokularında hipokampus ve kortekste histolojik hasar skorlaması yapıldı. Alınan kesitlerde Nöroplastin, TRAF6, GLUA1 ve GABA (A/B) reseptörlerinin lokalizasyonları ve protein ifadeleri sırasıyla immünohistokimya ve western blot yöntemleri ile belirlendi.

Bulgular: Hem hipokampus hem de kortekste incelenen nöron dejenerasyonu ve damar dilatasyonu bakımından cinsiyetler arasında fark olmazken, PTZ SE grubuna göre PTZ SE + Rutin gruplarında skorlanan bu histopatolojik parametrelerinin şiddetinin azaldığı tespit edildi. Özellikle hipokampüste PTZ SE grupları ile kıyaslandığında PTZ SE + Rutin gruplarında Nöroplastin, GluA1 ve TRAF6, GABAA reseptörlerinin protein ifadelerinin arttığı, GABAB reseptörünün ifadesinin de baskılandığı gözlenmiştir. Erkek kortekste ise GABAA ve GABAB reseptörlerinin ifadeleri PTZ SE gruplarında daha çok iken, Nöroplastin ve TRAF6 ifadeleri PTZ SE + Rutin gruplarında artmıştır. Dişi kortekste ise GABAB ve

Nöroplastin PTZ SE gruplarında daha çok ifade edilirken, GluA1 ve TRAF6 ifadeleri PTZ SE + Rutin gruplarında artmıştır.

Sonuç: Çalışmamızda rutin uygulanması ile birlikte hipokampus ve kortekste Nöroplastin, GluA1 ve TRAF6, GABAA reseptörlerinin ifadelerinde artış olduğu belirlenmiştir. Anlamlı ifade değişimi gösteren proteinlerin belirlenmesi bu doğrultuda yeni terapötik yaklaşımlara zemin hazırlanmasında etkili olacaktır.

Anahtar Kelimeler: Rutin, Nöroplastin, Deneysel Epilepsi Modeli, Hipokampus, Korteks

Sözlü Bildiri

ANOREKSIJENIK PEPTIT SENTEZLEYEN NÖRONLARDA ÖSTROJEN RESEPTÖR EKSPRESYONUNUN IMMÜNOHISTOKIMYASAL OLARAK BELIRLENMESI

NERGİS COŞKAN | BAHAR POMAK ADALI | ÖZHAN EYİGÖR

Bursa Uludag University, Faculty Of Medicine, Department Of Histology And Embryology, Bursa, Turkiye
nergiscoskan1998@gmail.com

Özet

Giriş: Dişilerde üreme fonksiyonu besin alımı ile yakından ilişkilidir çünkü dişilerde üreme fonksiyonu yüksek enerji kullanımı gerektirir. Phoeniksin (PNX) ve R-Spondin 3 (RSPO-3) besin alımını baskılayan anoreksijenik peptitlerdir ve hipotalamusta yerleşik nöronlar tarafından sentezlenir ve salgılanır. Östrojen ise metabolizma ve enerji homeostazında rol oynayan, ovaryumdan salgılanan önemli bir hormondur. Nükleer reseptör protein ailesine ait ER-α, ER-β ve GPER olmak üzere üç tip reseptörü vardır.

Amaç: Bu çalışma anoreksijenik peptit sentezleyen nöronların periferik östrojen sinyalini almak için ER-α ve/veya ER-β reseptörlerini eksprese edip etmediğini ve östrojenin miktarına göre reseptör miktarındaki değişiklikleri saptamayı amaçlamıştır.

Gereç-Yöntem: Bu çalışmada, erişkin 200-250g Wistar türü sıçanlar kullanılmış olup 2 gruba ayrılmıştır. İlk grup proöstrusta sakrifiye edilen gruptur (n=10). İkinci grup ise ovariektomi uygulandıktan 14 gün sonra sakrifiye edilen gruptur (n=10). Phoeniksin ve RSPO-3 nöronları ile ER-α, ER-β kolokalizasyonu, perfüzyonla fikse edilen dokulardan alınan yüzen kesitlerde ikili immünohistokimyasal tekniği kullanılarak araştırılmıştır. ER-α, ER-β içeren Phoeniksin ve RSPO-3 nöronlarının tüm Phoeniksin ve RSPO-3 nöronları içerisindeki oranı hesaplanmıştır.

Bulgular: Ventromedial çekirdekte Phoeniksin nöronlarındaki ER-α ekspresyonları karşılaştırıldığında proöstrus (34,93±6,91) ve ovariektomi (15,26±2,21) grupları arasında istatiksel olarak anlamlı fark bulunmuştur (p= 0,04). Supraoptik çekirdekte RSPO-3 nöronlarındaki ER-β için proöstrus (25,99±4,58) ve ovariektomi (4,07±1,92) grupları arasında istatiksel olarak anlamlı fark bulunmuştur (p=0,01). Ayrıca hipotalamusta östrojen reseptörlerini eksprese eden Phoeniksin nöronlarının yüzdesi proöstrus ve ovariektomi grupları arasında karşılaştırıldığında ovariektomi grubunda ER-α (30,48±2,67) ve ER-β (19,74±3,40) arasında istatiksel olarak anlamlı fark bulunmuştur (p=0,038). Ek olarak RSPO-3 nöronların yüzdesi proöstrus ve ovariektomi grupları arasında karşılaştırıldığında PNX gibi ovariektomi grubunda ER-α (63,27±4,99) ve ER-β (11,40±5,91) arasında istatiksel olarak anlamlı fark bulunmuştur (p=0,003). Ancak her iki peptit için de proöstrus grubunda anlamlı fark bulunamamıştır.

Sonuç: Phoeniksin ve RSPO-3 nöronlarında ER-α ve ER-β literatürde ilk defa gösterilmiş olup bu nöronların östrojen aracılığı ile oluşan periferik gonadal sinyalleri ER-α ve ER-β reseptörleri üzerinden alabiliyor olduğu düşünülmüştür.

Bu çalışma Bursa Uludağ Üniversitesi (BAP) birimi (TYL-2023-1419) tarafından desteklenmiştir.

Sözlü Bildiri

BLEOMISIN ILE INDÜKLENMIŞ DENEYSEL DERI HASAR MODELINDE ALFA LIPOIK ASIDIN POTANSIYEL ETKILERININ DEĞERLENDIRILMESI

NEŞE ÇÖLÇİMEN | SEDA KESKİN

Van Yüzüncü Yıl Üniversitesi/ Tıbbi Histoloji Ve Embriyoloji Abd
colcimennese@hotmail.com

Özet

Giriş: Bleomisin (BLM), tek başına veya kombine olarak kanser tedavisinde kullanılan antineoplastik bir ajandır. Ancak, BLM'nin sağlıklı deri dokusunda oluşturduğu hasarlar, bilinen yan etkileri arasındadır.

Amaç: Sunulan çalışmada, BLM ile indüklenen deri hasarında, Alfa lipoik asidin (ALA) olası doku koruyucu etkilerinin, histokimyasal ve immunohistokimyasal (İHK) yöntemlerle birlikte incelenmesi amaçlandı.

Materyal-Metot: Toplam 30 adet erişkin Wistar albino sıçan, Kontrol, ALA, BLM ve BLM+ALA olmak üzere rastgele 4 gruba ayrıldı. Kontrol grubuna 1., 8., ve 15. günlerde intramüsküler (i.m) serum fizyolojik (0.1 ml/gün), BLM grubuna 1., 8., ve 15. günlerde i.m BLM enjeksiyonu (30 mg/m2/gün), BLM+ ALA tedavi grubuna BLM enjeksiyonları yanında 2 hafta boyunca subkutan (s.c) her gün tek doz ALA (50 mg/kg/gün), yalnız ALA grubuna ise 2 hafta boyunca s.c yolla aynı ve tek doz ALA uygulandı. Deney sonunda anestezi sonrası, sıçanların sırt bölgesinden alınan deri örnekleri %10'luk nötral tamponlu formaldehitte fikse edildi. Daha sonra örnekler, ışık mikroskobunda değerlendirilmek için rutin histolojik takip prosedürlerinden geçirildi. Mikrotomda alınan 5µm kesitlerde genel histopatolojik inceleme için Hematoksilen &Eozin (H&E) boyama, kollajen lif değişimlerini değerlendirmek için Masson trikrom (MT) boyama ve mast hücre yoğunluk analizleri için ise Toluidin Mavisi (TB) boyama yapıldı. Kaspaz-1 ve Ki-67 antikorlarının İHK boyama analizleri için poli-lizinli lama alınan 5µm'luk kesitler, İHK boyama hazırlık aşamalarından geçirildi. İlgili antikorların ekspresyon yoğunlukları Image J (Fiji) programıyla analiz edildi.

Bulgular: H&E boyama sonuçlarında, kontrole kıyasla BLM grubuna ait deri örneklerinde fokal lenfositik infiltrasyon alanları yanında epidermal kalınlaşma görülürken, ALA verilen tedavi grubunda bu değişimlerin düzeldiği görüldü. Bunun yanı sıra kollagen lif yoğunluğunun BLM grubunda kontrole göre arttığı, ALA verilen tedavi grubunda kollajen lif yoğunluğunun anlamlı ölçüde azaldığı tespit edildi. Diğer yandan mast hücre yoğunluk değişimlerinde, BLM grubunda görülen artışlar, ALA tedavisiyle önemli ölçüde azaldı. İHK analiz bulgularında ise kaspaz-1 ve Ki-67 ekspresyon yoğunlukları, BLM grubunda kontrol ile karşılaştırıldığında önemli derecede artarken, BLM+ALA grubunda ise BLM grubuna kıyasla anlamlı ölçüde azaldı.
Sonuç: Tüm veriler birlikte değerlendirildiğinde, BLM'nin sıçan cildinde neden olduğu inflamasyon, doku hassasiyeti ve fibrozis üzerine ALA'nın anti-inflamatuvar aktivite sergileyerek doku koruyucu etkiler gösterdiği sonucuna varıldı.

Anahtar Kelimeler: Alfa Lipoik Asit, Bleomisin, Deri, İnflamasyon, Mast hücresi

Sözlü Bildiri

SIÇANLARDA METOTREKSAT ILE OLUŞTURULAN TESTIS HASARINA KARŞI LACTOBACILLUS RHAMNOSUS GG'NIN OLASI KORUYUCU ETKILERININ INCELENMESI

YASEMİN CESUR[1] | İSMET BURCU TÜRKYILMAZ MUTLU[2] | DİLEK ÖZBEYLİ[3] | REFİYE YANARDAĞ[4] | SEVİL ÖZKAN[5] | GÖKSEL ŞENER[6] | FERİHA ERCAN[2]

1 Marmara Üniversitesi Tıp Fakültesi, Histoloji Ve Embriyoloji Anabilim Dalı, İstanbul,
2 İstanbul Üniversitesi-Cerrahpaşa, Mühendislik Fakültesi, Kimya Bölümü, İstanbul
3 Marmara Üniversitesi Sağlık Hizmetleri Meslek Yüksek Okulu, Patoloji Teknikleri Bölüm, İstanbul
4 İstanbul Üniversitesi-Cerrahpaşa, Mühendislik Fakültesi, Kimya Bölümü, İstanbul
5 Sağlık Bilimleri Üniversitesi Numune Eğitim Araştırma Hastanesi, İç Hastalıkları Anabilim Dalı, İstanbul
6 Fenerbahçe Üniversitesi Eczacılık Fakültesi, Farmakoloji Anabilim Dalı, İstanbul
yasemincesurr@gmail.com

Özet

Giriş: Metotreksat (MTX), kanser tedavisi ve otoimmün hastalıkların yönetiminde yaygın olarak kullanılan kemoterapötik bir ajandır. Ancak, yüksek dozlarda kullanımı testiste oksidatif stres, hücresel hasar ve sperm parametrelerinde bozulma gibi ciddi yan etkilere neden olmaktadır. Bu nedenle, MTX'in olumsuz etkilerini azaltmaya yönelik koruyucu stratejiler araştırılmaktadır. Probiyotiklerin, özellikle Lactobacillus rhamnosus GG'nin (LGG), antioksidan özellikleri ve inflamasyonu azaltıcı etkileri sayesinde çeşitli doku hasarlarına karşı koruyucu olabileceği düşünülmektedir.

Amaç: Bu çalışmanın amacı, MTX ile indüklenen testis hasarına karşı LGG'nin olası koruyucu etkilerinin histolojik ve biyokimyasal yöntemlerle araştırılmasıdır.

Materyal-Metot: Çalışmada Sprague Dawley ırkı erkek sıçanlar (2-3 aylık) kullanıldı ve Kontrol, MTX, MTX + LGG1 ve MTX + LGG5 olmak üzere dört deney grubu (n=32) oluşturuldu. Çözücü olarak MTX için serum fizyolojik (SF), LGG için zeytinyağı kullanıldı. Kontrol grubundaki sıçanlara SF (ip) ve zeytinyağı (oral) verildi. MTX grubuna, tek doz MTX (20 mg/kg,i.p.) ve oral 0,1 ml/100 gr vücut ağırlığı olacak şekilde çözücü 5 gün boyunca verildi. MTX uygulamasından sonra, MTX + LGG1 grubuna, oral olarak 1 x 109 CFU/gün LGG; MTX + LGG5 grubuna ise 5 x 109 CFU/gün LGG 5 gün boyunca verildi. Deney sonunda sakrifiye edilen sıçanların sağ testislerinde histolojik değerlendirme hematoksilen ve eozin ve periyodik asit Schiff (PAS) ile boyalı kesitlerde yapıldı. Sol testis homojenatlarında ise reaktif oksijen türevleri (ROT), total oksidan (TO), total antioksidan (TAO), lipit peroksidasyon (LPO), glutatyon (GSH), alkali fosfataz (ALP), ve asit fosfataz (ACP) düzeyleri biyokimyasal yöntemlerle değerlendirildi. Elde edilen veriler, istatistiksel olarak tek yönlü ANOVA ve Tukey'in çoklu karşılaştırma testleri kullanılarak yapıldı ve $p<0.05$ anlamlı kabul edildi.

Bulgular: Kontrol grubu ile kıyaslandığında, MTX grubunda, seminifer tübüller arasında açılma, seminifer tübüllerin çapında düşüş, bazal membran yapısında düzensizlik, germinal epitelyum hücre hattında azalma ve epitel hücreleri arasında genişlemeler olan çok sayıda hasarlı seminifer tübüllerin olduğu gözlendi. MTX grubu ile kıyaslandığında ise MTX+LGG1 ve MTX + LGG5 gruplarında seminifer tübül hasarının azaldığı gözlendi. Histolojik bulgulara

paralel olarak MTX uygulaması ile bozulmuş oksidatif hasar parametrelerinin LGG uygulaması ile iyileştiği gözlendi.

Sonuç: Metotreksat uygulaması oksidatif hasar oluşumunu arttırarak spermatogenik hücrelerinin azalmasına ve testis hasarına sebep olur. Lactobacillus rhamnosus GG uygulamasının oksidan ve antioksidan dengeyi düzenleyerek metotreksat ile oluşturulan testis hasarını iyileştirdiği düşünülmektedir.

Anahtar kelimeler: Metotreksat, Lactobacillus rhamnosus GG, probiyotik, testis, sıçan

Sözlü Bildiri

RSPO-1 NÖRONLARINDA GLUTAMATERJIK SISTEMIN AKTIVE EDICI ETKISI

GONCA TOPAL[1] | DUYGU GÖK YURTSEVEN[2]
NURSEL HASANOĞLU AKBULUT[3] | ÖZHAN EYİGÖR[2]

[1]Bursa Uludağ Üniversitesi Sağlık Bilimleri Enstitüsü | [2]Bursa Uludağ Üniversitesi Tıp Fakültesi Histoloji Embriyoloji Ad | [3]Çanakkale Onsekiz Mart Üniversitesi Tıp Fakültesi Histoloji Embriyoloji Ad
goncatopal.1992@gmail.com

Özet

Amaç: Besin alımı, merkezi ve periferik sinyal mekanizmalarıyla kontrol edilen, başlıca merkezi sinir sisteminden dolaşıma salınan nöropeptitler ile davranışa dönüşen kompleks bir mekanizmadır. R-spondin-1'in anoreksijenik bir peptit olduğu ve hipotalamusta eksprese edildiği rapor edilmiştir. Glutamat, eksitatör nörotransmitter olarak, hipotalamik çekirdeklerde yerleşik nöronların kontrolünde yer alır ve Rspo-1 nöronlarını düzenleyici etkisinin varlığı bilinmemektedir. Çalışmamızda, glutamat agonistleri (Kainik asit, AMPA ve NMDA) ve antagonistlerinin (CNQX ve MK-801) SON, PVN ve ARC'deki Rspo-1 nöronları üzerindeki etkilerinin immünohistokimyasal olarak değerlendirilmesi amaçlanmış, c-Fos proteini nöronal aktivasyon belirteci olarak kullanılmıştır.

Gereç ve Yöntem: Çalışmada Sprague Dawley cinsi erkek sıçanlar kullanılmıştır. Deneklere glutamat agonistleri kainik asit (2.5 mg/kg), AMPA (5 mg/kg) ve) NMDA (100 mg/kg), AMPA-kainat reseptör antagonisti CNQX (2 mg/kg), NMDA reseptör antagonisti MK-801(1mg/kg) ve kontrol grupları için salin (%0,9 NaCl) intraperitoneal (i.p.) uygulanarak 9 grup (n=3) oluşturulmuştur. Antagonist enjeksiyonları ilgili reseptör agonisti enjeksiyonundan 15 dakika önce yapılmıştır. Enjeksiyonları takip eden 90. dakika sonunda hayvanlar transkardial yolla verilen fosfat tamponlu %4 paraformaldehit ile fikse edilmiştir. Çıkartılan beyinlerden vibratom ile 40 µm kalınlığında koronal kesitler alınmıştır. Kesitlere ikili indirekt immünoperoksidaz yöntemi kullanılarak Rspo-1 ve c-Fos işaretlemeleri yapılmıştır. SON, PVN ve ARC'nin mikroskobik analizi ile elde edilen sonuçlar ikili işaretlenen (aktive olan) Rspo-1 nöronlarının tüm Rspo-1 nöronlarına oranı alınarak gruplar arasında istatistiki olarak değerlendirilmiştir.

Bulgular: Çalışmamızda SON, PVN ve ARC'de glutamat agonistleri kainik asit, AMPA ve NMDA uygulamalarının, c-Fos pozitif Rspo-1 nöronların yüzdesini salin uygulanan kontrol gruplarına göre anlamlı olarak arttırdığı bulunmuştur ($p<0,001$). Agonist uygulaması öncesi antagonist uygulaması yapılan gruplarda nöronal aktivasyonun anlamlı olarak baskılandığı görülmüştür ($p<0,05$).

Sonuç: Sonuç olarak, glutamaterjik agonistlerin Rspo-1 nöron aktivasyonunu arttırdığı, antagonist verilen deneklerde ise nöronal aktivasyonu baskıladığı gösterilmiştir. Glutamaterjik sistemin bu etkisini Rspo-1 nöronları tarafından eksprese edilen glutamat reseptörlerine bağlanarak gösterebileceği düşünülmüştür.

Anahtar sözcükler: Rspo-1, Glutamat, Hipotalamus, İmmunohistokimya, Nöronal Aktivasyon Bu çalışma TÜBİTAK tarafından desteklenmiştir (123S881).

Sözlü Bildiri

GLIOBLASTOMA HÜCRELERINDE ILAÇ DIRENCININ AŞILMASI: CDK4/6 INHIBISYONUNUN ETKISI

YUSUF YILMAZ[1] | KAAN FURKAN HAMARAT[1] | HACER AĞAR[2]
GAMZE TANRIÖVER[3] | GAMZE GÜNEY ESKİLER[2]

[1]Sakarya Üniversitesi Tıp Fakültesi, Sakarya, Türkiye | [2]Sakarya Üniversitesi, Sağlık Bilimleri Enstitüsü, Tıbbi Biyoloji Abd, Sakarya, Türkiye | [3]Akdeniz Üniversitesi Tıp Fakültesi, Histoloji Ve Embriyoloji Abd, Antalya, Türkiye, Akdeniz Üniversitesi Tıp Fakültesi, Tıbbi Biyoteknoloji Abd, Antalya, Türkiye
yusuf.yilmaz16@ogr.sakarya.edu.tr

Özet

Giriş: Glioblastoma (GBM), en sık görülen primer malign beyin tümörü tipi olup, prognozu en kötü kanserler arasında yer almaktadır. GBM tedavisinde alkilleyici kemoterapötik ajan olarak Temozolomid (TMZ) uygulanmaktadır. Ancak TMZ'ye karşı gelişen ilaç direnci, kanser kök hücreleri ve tümör heterojenitesi hastalığın kötü prognozuna yol açmaktadır. Çoklu ilaç direnci gelişiminde ATP-bağlayan kaset proteinlerin (ABC) aşırı ekspresyonu kemoterapi ilaçlarının hücre içine girişini kısıtlamakta ve etkinliğini zayıflatmaktadır. Bu nedenle, ilaç direncine neden olan effluks pompalarının aktivitesinde değişime neden olabilecek yeni tedavi seçeneklerinin belirlenmesi gerekmektedir. Hücre siklusundaki değişimler kontrol noktalarında düzensizliğe yol açarak kanser hücrelerinde kontrolsüz hücre bölünmesine neden olmaktadır. Siklin bağımlı kinaz (CDK) 4/6 ve Siklin D kompleksinin hücre siklusunun G0/G1 fazından S fazına geçişinde temel rolü birçok kanser tipinin tedavisinde aşırı aktiviteye sahip olan CDK4/6 inhibisyonunun dikkat çekmesine neden olmaktadır.

Amaç: Bir CDK4/6 inhibitörü olarak abemasiklib (ABE)'nin iki farklı GBM hücre hattında çoklu ilaç direncinde rol alan MDR1, BCRP1 ve MRP1 effluks pompaları üzerindeki etkisinin moleküler düzeyde değerlendirilmesi amaçlanmaktadır.

Materyal-Metot: TMZ dirençli T98G ve duyarlı U87MG GBM hücre hatlarında ABE'nin (0.5-2 µM) etkin doz ve saati CCK-8 analizi ile belirlendikten sonra, MDR1, BCRP1 ve MRP1 genlerinin ekspresyon seviyeleri RT-PCR analizi ile belirlenmiştir. Ayrıca, ABE'nin effluks pompalarında etkisi immünofloresans boyama ile görüntülenmiştir.

Bulgular: ABE uygulanan GBM hücre hatlarının canlılık oranlarının doza bağlı bir şekilde anlamlı olarak azaldığı belirlenmiştir ($p<0.01$). Özellikle, 24 saat boyunca 2 µM ABE uygulanan T98G ve U87 hücrelerinde canlılık oranlarının sırasıyla %22.7 ve %28.3'e azaldığı analiz edilmiştir. Ayrıca, RT-PCR ve immünofloresans boyama analizlerinde ABE uygulanan GBM hücrelerinde effluks pompalarının inaktive olduğu ve T98G hücrelerinde TMZ direncinin aşılmasında ABE'nin terapötik potansiyeli ortaya konmuştur.

Sonuç: Özetle, ABE'nin ilk kez GBM hücrelerinde ilaç direncinin gelişmesinde rol alan effluks pompalarının inhibisyonunda etkisi moleküler düzeyde ortaya konmuştur. Ancak, CDK4/6 inhibitörlerinin GBM tedavisinde TMZ direncinin aşılmasında etkinliğinin in vivo düzeyde aydınlatılmasına yönelik ileri çalışmalara ihtiyaç bulunmaktadır.

Anahtar Kelimeler: Glioblastoma, CDK4/6, Abemasiklib, Çoklu İlaç Direnci

Bu çalışma "1919B012307120" numaralı proje olarak "2209-A-Üniversite Öğrencileri Araştırma Projeleri Destekleme Programı" tarafından desteklendiği için Türkiye Bilimsel ve Teknolojik Araştırma Kurumu (TÜBİTAK)'a teşekkür ederiz.

Sözlü Bildiri

KADMIYUM UYARILI TESTIS HASARINA KARŞI TIMOKINON'UN KORUYUCU ETKISI

TAYFUN CEYLAN[1] | EMİN KAYMAK[2] | ŞABAN VARİNLİ[2] | ALİ TUĞRUL AKİN[3]

[1]Kapadokya Üniversitesi, Diş Hekimliği Fakültesi, Temel Bilimler Bölümü, Nevşehir/Türkiye | [2]Bozok Üniversitesi, Tıp Fakültesi, Histoloji Ve Embriyoloji Anabilim Dalı, Yozgat/Türkiye |[3] İstinye Üniversitesi, Tıp Fakültesi, Tıbbi Biyoloji Anabilim Dalı, İstanbul/Türkiye
tyf.ceylan@gmail.com

Özet

Giriş: Metaller, günlük yaşamda mesleki olarak veya çevredeki doğal varlıklarıyla karşılaşılan önemli bir toksik element sınıfı olarak bilinmektedir (1). Toksik ağır metallerden biri olan kadmiyumun (Cd) artan üretimi ve yaygın kullanımı hem insanları hem de diğer canlıları onun toksik etkilerine maruz bırakmaktadır (2). Cd, testis dokusuna nüfuz ederek testis disfonksiyonuna ve ardından spermatogenezin bozulmasına neden olmaktadır. Cd maruziyeti ile hücrelerde HMGB1/TLR4/NF-κB yolağının aktivasyonu ile akut inflamatuar yanıt başlamaktadır (3). Cd aynı zamanda serbest oksijen radikallerinin salınmasına neden olmaktadır. Ayrıca testosteron seviyesini düşürmektedir (4). Sonuç olarak farklı mekanizmalar yoluyla testis toksisitesine neden olan Cd fertiliteyi azaltmaktadır. Nigella Sativa'nın (çörek otu) aktif bileşenlerinden olan timokinon (TK) anti-hiperglisemi, anti-inflamasyon, analjezi, anti-bakteriyel, anti-mutajenik, anti-konvülsiyon, anti-oksidan, anti-kanserojenik ve nöroprotektif etkilerinin yanı sıra testiküler hasar ve düşük sperm kalitesini iyileştirici etki göstermektedir (5, 6). Ancak Cd'nin oluşturduğu testiküler hasara karşı TK'nın koruyuculuğunu gösteren çok az sayıda çalışma olmakla birlikte bu koruyucu etkinin mekanizması yeterince aydınlatılmamıştır.

Amaç: Bu çalışmada Cd'nin sebep olduğu testis hasarına karşı TK'nın koruyucu etkisini araştırmayı amaçladık.

Materyal-Metot: 32 adet erkek Wistar albino sıçan aşağıdaki şekilde 4 gruba ayrıldı.
1. Kontrol grubuna (n=8) 14 gün boyunca intraperitoneal yolla serum fizyolojik uygulandı.
2. Cd grubuna (n=8) 14 gün boyunca intraperitoneal olarak 0.4 mg/kg dozda Cd uygulandı (3).
3. Cd+TK grubuna (n=8) 14 gün boyunca intraperitoneal olarak 0.4 mg/kg dozda Cd ve 10 mg/kg dozda TK uygulandı (7).
4. TK grubuna (n=8) 14 gün boyunca intraperitoneal olarak 10 mg/kg dozda TK uygulandı.
Deneyin 15. gününde sıçanlar ksilazin ve ketamin anestezisi altında dekapite edilerek testis dokusu örnekleri alındı. Fiksasyon ve doku takibi işlemlerinin ardından parafine gömülen testis dokularından 5µm kalınlığında kesitler alındı. Kesitler rutin hematoksilen-eozin boyaları ile boyanarak histolojik hasar belirlendi. Seminifer tübüllerdeki hasarlanmanın derecesinin değerlendirilmesinde Johnsen Testiküler Biyopsi Skoru (JTBS) kullanıldı. Ayrıca testis dokularında HMGB1, TLR4 ve NF-κB antikorları immünohistokimya yöntemi ile değerlendirildi. Veriler ortalama ± SD olarak ifade edildi. One-way ANOVA ve Tukey's post-hoc testleri ile analiz yapıldı. Analizlerde $p<0.05$ anlamlı olarak kabul edildi.

Bulgular: Deney sonunda testis kesitlerinde JTBS'ye göre Cd grubunda biyopsi skoru kontrol grubuna göre anlamlı şekilde azaldı. Cd+TK grubunda ise Cd grubuna göre anlamlı şekilde fazlaydı. Aynı zamanda Cd grubunda HMGB1, TLR4 ve NF-κB ekspresyonları kontrol grubuna göre anlamlı şekilde fazlaydı. Bu antikorlar Cd+TK grubunda ise Cd grubuna göre anlamlı şekilde azalma gösterdi.

Sonuç: Bizim sonuçlarımız Cd uygulaması ile oluşan testis hasarına karşı TK'nın, HMGB1/TLR4/NF-κB yolağı aracılığıyla oluşan akut inflamatuar yanıtı baskılayarak, koruyucu etki oluşturduğunu göstermektedir.

Sözlü Bildiri

GENETIK ABSANS EPILEPSILI SIÇANLARDA ARALIKLI AÇLIĞIN NÖROGENEZ ÜZERINE ETKILERININ INCELENMESI

DAMLA GÖKÇEOĞLU KAYALI | AYLİN TOPLU | ZARİFE NİGAR ÖZDEMİR KUMRAL | BETÜL ÇIKI | ÖZLEM TUĞÇE ÇİLİNGİR-KAYA

Marmara Üniversitesi Histoloji Ve Embriyoloji, damlagokceoglu@yandex.com

Özet

Giriş: Epilepsi, dünyada 70 milyondan fazla insanı etkileyen yaygın bir nörodejeneratif hastalıktır. GAERS suşu, genetik absans epilepsinin deneysel hayvan modelidir. Nörogenez, yeni nöronların beyne entegre olması süreci olup öğrenme, hafıza ve stres tepkilerini etkiler. Son araştırmalar, bağırsak mikrobiyotasının hipokampal nörogenezi modüle edebileceğini göstermektedir. Bağırsak mikrobiyatası, aralıklı açlık (AA) gibi etmenlerle düzenlenerek nörogenez ve epilepsi süreçleri, mikrobiyota-bağırsak-beyin ekseni yoluyla etkilenebilir ve nörogenezle ilişkili bozuklukların tedavisinde yeni yaklaşımlar sunulabilir.

Amaç: Çalışmamızda GAERS sıçanlarda, AA uygulamasının hipokampal nörogenez ve bağırsak-beyin ekseni ve epileptic nöbetler üzerindeki olası koruyucu etkilerini değerlendirmek amaçlanmıştır.

Materyal-Metod: 40 adet erkek hayvan, Wistar-Kontrol, Wistar-AA (24 saat gıda yoksunluğu/24 saat ad libitum beslenme), GAERS-Kontrol, GAERS-AA (24 saat gıda yoksunluğu/24 saat ad libitum beslenme) olarak 4 gruba ayrılmıştır. 30 günlük deney sonunda sıçanlardan EEG kaydı alınmış ve davranış testleri uygulanmıştır. Kardiyak perfüzyon sonrası elde edilen beyin ve kolon örneklerine, rutin histolojik takip işlemleri sonrasında hipokampal nörogenezi incelemek amacıyla doublecortin (DCX) ve kalbindin ekspresyonları immünohistokimya (İHK) ve western blot (WB) yöntemleri uygulanmıştır. Kolon örnekleri histopatolojik inceleme için H&E, goblet hücrelerindeki değişim için PAS reaksiyonu ile boyanmıştır. Kolon epitel hücrelerinin sıkı bağlantıları okludin İHK'sı ile analiz edilmiştir. Hem beyin hem de kolon dokularında MPO, MDA, SOD, GSH ve KAT düzeyleri ELISA yöntemiyle ölçülmüştür.

Bulgular: Pasif sakınma testinde geçiş gecikmesi, GAERS-Kontrol grubunda tüm deney gruplarına göre anlamlı bir düşüş sergilerken, GAERS-AA grubunda bu düşüş anlamlı olarak artmıştır. Açık alan testinde, Wistar-Kontrol grubuna göre Wistar-AA grubunda anlamlı derecede artan dolaşma mesafesi gözlenirken ($p<0,05$), GAERS sıçanlarda fark izlenmemiştir. GAERS sıçanların EEG analizinde, AA grubu sıçanların ortalama nöbet süresi, kontrol grubuna göre anlamlı olarak azalmıştır ($p<0,05$). İHK ve WB sonuçlarına göre, DCX ve kalbindin ekspresyonları, Wistar-Kontrol ve Wistar-AA arasında bir fark göstermezken; GAERS-AA grubunda, GAERS-Kontrol grubuna kıyasla anlamlı düzeyde artmıştır. Kolon histopatolojisinde GAERS-AA grubunda, GAERS-Kontrol grubuna göre artan skor ve goblet hücre sayısı ($p<0,01$) belirlendi. GAERS gruplarındaki azalmış okludin ekspresyonu, kontrol gruplarına kıyasla anlamlı derecede arttı ($p<0,05$). Beyin ve kolon örneklerinde MPO, MDA değerlerinde fark gözlenmezken, GSH, SOD ve KAT düzeyleri GAERS-AA gruplarında GAERS grubuna göre anlamlı şekilde yüksekti ($p<0,05$, $p<0,01$, $p<0,001$).

Sonuç: Çalışmamızın verileri, AA'nın epilepsi üzerindeki olası yararlı etkilerini nörogenez ve bağırsak-beyin ekseni üzerinden gösterdiğini düşündürmektedir. Bu ilişkinin daha net ortaya konabilmesi için detaylı mikrobiyota analizleri ile desteklenecek ileri çalışmalar gerekmektedir.

Anahtar Kelimeler: Aralıklı açlık, hipokampal nörogenez, GAERS, epilepsi, bağırsak bütünlüğü

Sözlü Bildiri

DENEYSEL OVER TORSIYONU MODELINDE ISKEMI-REPERFÜZYON HASARINA KARŞI MIRISETIN'IN OVER VE OOSIT ÜZERINE ETKILERI

SEVDA AYDIN | ELVAN ŞAHİN | BETÜL ÖZBEK | ÖZCAN BUDAK | MEHMET SÜHHA BOSTANCI

Sakarya Üniversitesi, sevdaaydin@sakarya.edu.tr

Özet

Giriş: Over torsiyonu, overin vasküler ekseni etrafında dönmesi sonucunda kan akımının bozulduğu jinekolojik acil bir durumdur. Kan akımı acilen yeniden sağlanmazsa overde iskemi kaynaklı hasar gelişir. Bu sebeple kadın üreme sağlığını korumak adına erken tanı ve tedavisi önem taşır. Günümüzdeki tedavi yöntemi, overin detorsiyone edilerek reperfüzyonun sağlanmasıdır. Ancak, reperfüzyon sonrası oluşan toksik ürünler dokuya hasar vermektedir. Literatürde iskemi-reperfüzyon hasarına karşı antioksidanların kullanıldığı görülmektedir.
Amaç: Flavonoid grubu antioksidanlardan olan Mirisetin'in over torsiyonu ve detorsiyonunu takiben iskemi-reperfüzyon hasarına karşı olası koruyucu etkilerini mikroskobik düzeyde araştırmak amaçlandı.

Gereç Ve Yöntem: 32 adet Wistar Albino genç erişkin dişi sıçan kullanıldı. Sıçanlar Kontrol, İskemi, İskemi-reperfüzyon ve Tedavi olmak üzere rastgele 4 gruba bölündü. Tüm gruplara anestezi altında abdominal insizyon yapıldıktan sonra, kontrol hariç diğer gruplarda over torsiyonu gerçekleştirildi; iskemi-reperfüzyon ve tedavi gruplarına 3 saatlik torsiyon sonrası detorsiyon işlemi uygulandı; tedavi grubuna detorsiyonu takiben 20 mg/kg i.p. Mirisetin verildi. İşlemler tamamlandığında tüm sıçanların abdomenleri sütürle kapatıldı. Denekler üç östrus siklusu boyunca takip edildikten sonra hormon enjeksiyonuyla oosit stimülasyonu uygulandı. Sıçanlar tüm kanları alınarak sakrifiye edildikten sonra çıkarılan sağ overlerden toplanan oositler invert mikroskopta incelendi. Sol overler histopatolojik değerlendirmeler için kullanıldı; ayrıca VEGF ve Caspase-3 immünperoksidaz boyamaları yapılarak ışık mikrograftları çekildi.

Bulgular: Hematoksilen-Eozin boyama ile over dokusunda histopatolojik hasar skorlandığında, vasküler dilatasyon ve hemoraji alanlarının en az kontrol grubunda, en fazla reperfüzyon grubunda olduğu görüldü ($p<0,001$). Oosit sayısı en fazla kontrol grubunda gözlenirken en az oosit sayısı iskemi grubunda saptandı ($p<0,001$). Mirisetin tedavisinin doku hasarını azaltmada ve oositler üzerinde etkili olduğu görüldü. VEGF ve Caspase-3 ekspresyonlarının en az kontrol grubunda olduğu, ekspresyon şiddetinin en fazla iskemi grubunda artarken, tedavi grubunda azaldığı görüldü ($p<0,001$).

Sonuç: Over torsiyonu tedavisinde overde oluşabilecek iskemi-reperfüzyon hasarında tedaviye Mirisetin eklenmesi kadın üreme sağlığını korumada faydalı olabilir.

Sözlü Bildiri

STREPTOZOTOSIN ILE INDÜKLENMIŞ DIYABETIK RAT MODELINDE HIDROKSITIROZOLÜN PANKREAS BETA HÜCRELERINDEKI PI3K/AKT YOLAĞI, INSÜLIN VE GLUT-2 EKSPRESYONU ÜZERINE ETKILERI

EMRAH ŞEFLEK | KAYIHAN KARAÇOR

Düzce Üniversitesi Tıp Fakültesi Histoloji Ve Embriyoloji Abd,Marmara Üniversitesi Tıp Fakültesi Histoloji Ve Embriyoloji Abd | Düzce Üniversitesi Tıp Fakültesi Histoloji Ve Embriyoloji Abd
emrah.seflek@yandex.com

Özet

Giriş: Diyabetes Mellitus (DM) yüksek kan glikozuyla seyreden ve tedavi edilmediğinde ciddi morbidite ve mortaliteye neden olan metabolik bir hastalıktır. STZ, Streptomyces achromogenes türünden izole edilen tek işlevli bir nitrosoüre türevidir. Geniş bir antibiyotik aktivitesine sahip olmasının yanı sıra antineoplastik özelliklere sahiptir ve genellikle pankreas β hücrelerine zarar vererek deney hayvanlarında DM oluşturmak için kullanılır. Diyabetin ve buna bağlı komplikasyonların tedavisi için birçok tedavi yöntemi denenmektedir. Hidroksitirosol (HT), zeytin yapraklarında ve zeytinyağında bulunabilen oleuropeinin ürünü, iyi bir biyoyararlanıma sahip, toksisitesinin olmamasıyla ön plana çıkan doğal, güçlü fenolik bir antioksidandır. Diyabet komplikasyonlarında antidiyabetik özellikleri ortaya konmuş hidroksitirozol, diyabetin tedavisinde de bir seçenek olarak düşünülebilir.

Amaç: Çalışmamızda Streptozotosin (STZ) ile indüklenmiş diyabetik rat modelinde HT'nin pankreas β hücrelerindeki Phosphoinositide 3-Kinase/ Protein Kinase B (PI3K/AKT) yolağı, insülin ve glucose transporter-2 (GLUT-2) ekspresyonu üzerine etkilerini araştırmayı amaçladık.

Materyal-Metot: Çalışmamızda 28 adet erkek Wistar cinsi rat kullanılmıştır. Hayvanlar; Kontrol, HT, STZ ve STZ+HT olmak üzere rastgele dört gruba ayrılmıştır. STZ ve STZ+HT gruplarında intraperitoneal (i.p.) tek doz (55 mg/kg) STZ ile diyabet indüklenmiştir. HT ve STZ+HT grubuna 1 ay boyunca i.p. olarak HT (10 mg/kg/gün) enjeksiyonu yapılmıştır.

Bulgular : STZ grubu hayvanlarda yüksek kan şekerine ek olarak vücut ağırlığı düşmüş, idrar yapma ve su içme davranışında artış gözlenmiştir. STZ+HT grubu ratlarda diyabet gelişse de kan glikoz düzeyleri istatistiksel anlam içermeyecek şekilde bir miktar azalmıştır. STZ grubuna kıyasla STZ+HT grubunda pankreas dokusu Langerhans adacıkları β hücrelerinde insülin, GLUT-2, PI3K ve AKT ekspresyonunda anlamlı bir artış olduğu görülmüştür.

Sonuç: Çalışmamızda HT'nin hiperglisemiyi pankreasta PI3K/AKT yolağı üzerinden GLUT-2 ve insülin ekspresyonunu arttırarak düzeltebileceği düşünülmektedir. Tip 1 DM ve buna bağlı komplikasyonların, HT'nin antihiperglisemik etkisinden yararlanarak DM'de mevcut tedavilere ek olarak kullanılabileceği; diyabete bağlı morbidite ve mortaliteye karşı koruyucu olabileceği öngörülmektedir.

Anahtar Kelimeler: Diyabetes Mellitus, Streptozotosin, Hidroksitirozol, İnsülin, PI3K, AKT, GLUT-2

Sözlü Bildiri

7. GÜN BLASTOSIST GELIŞIMI: RISK FAKTÖRLERININ ANALIZI VE GEÇ GELIŞIMIN PREDIKTE EDILMESI

CİHAN ÇAKIR[1] | SABİNA AGHAYEVA[1] | KİPER ASLAN[2] | IŞIL KASAPOĞLU[2]

Bursa Uludağ Üniversitesi, Tıp Fakültesi, Histoloji Ve Embriyoloji Anabilim Dalı | [2]Bursa Uludağ Üniversitesi, Tıp Fakültesi, Kadın Hastalıkları Ve Doğum Anabilim Dalı
sabinaagayeva52@gmail.com

Özet

Giriş:Tüp bebek ünitelerinde embriyoloji laboratuvarlarında gerçekleştirilen tedavilerde, embriyolar fertilizasyon sonrası 5 veya 6 gün boyunca, blastosist aşamasına kadar, kültüre edilmektedir. Ancak bazı embriyolar geç gelişim göstererek 7. günde blastosist aşamasına ulaşmaktadır. Literatürde, geç gelişen embriyoların öploid oranları, canlı doğum oranları ve perinatal sonuçlarının olumsuz etkilendiği bildirilmiştir. Ancak, yalnızca 6. veya 7. günde gelişimini tamamlayan embriyolardan elde edilen blastosistlerin bulunduğu siklusların etyolojisi ve klinik sonuçları hakkında literatürde yeterince bilgi bulunmamaktadır.

Amaç:Bu çalışmanın amacı, intrasitoplazmik sperm enjeksiyonu (ICSI) sikluslarında embriyoların yavaş gelişim göstermesi ile ilişkili parametreleri belirlemektir. Çalışmada, sadece 6. veya 7. gün blastosist gelişimi tespit edilen siklusların hasta demografisi, siklus özellikleri, semen parametreleri ve oosit kalitesi gibi çeşitli faktörler arasındaki ilişkiyi incelemeyi amaçladık. Ayrıca, gelecekteki vakalar için önleyici stratejiler geliştirebilmek amacıyla yavaş blastosist gelişimi riski taşıyan hasta popülasyonlarını tanımlamayı hedefledik.

Materyal ve Metot:Retrospektif olarak gerçekleştirilen çalışmamız kapsamında, 2018-2024 yılları arasında üniversitemizin Üremeye Yardımcı Tedavi (ÜYTE) Merkezi'nde gerçekleştirilen toplam 742 ICSI siklus çalışmaya dahil edilmiştir. Elde edilen blastosistlerin gelişim günlerine göre üç grub oluşturulmuştur: Grup 1 (n=527), tüm blastosistlerin 5. günde gelişimini tamamladığı siklusları; Grup 2 (n=161), tüm blastosistlerin 6. günde gelişimini tamamladığı siklusları; Grup 3 (n=54), tüm blastosistlerin 7. günde gelişimini tamamladığı siklusları içermektedir. Blastosist gelişim hızını etkileyen faktörleri belirlemek amacıyla hasta demografisi, hormonal parametreler, siklus özellikleri, oosit kalitesi ve semen parametreleri üç grup arasında karşılaştırılmıştır. Tüm gruplarda over yanıtı, Foliküler Çıkış Oranı (FORT) ve Folikül-Oosit İndeksi (FOI) kullanılarak değerlendirilmiştir. Ayrıca klinik sonuç olarak, klinik gebelik oranları analiz edilmiştir. Geç blastosist gelişimi ile anlamlı değişkenler arasındaki ilişkiyi incelemek için lojistik regresyon analizi uygulanmıştır.

Bulgular:Gruplar arasında demografik özellikler karşılaştırıldığında, kadın yaşı(p=0,327), erkek yaşı(p=0,451) ve kadın vücut kitle indeksi(p=0,124), parametrelerinin benzer olduğu, ancak infertilite süresi (p=0,017), ve infertilite etyolojisinin(p=0,002), istatistiksel olarak farklılık gösterdiği tespit edilmiştir. Bazal hormon parametreleri(p=0,361) gruplar arasında benzerlik göstermesine rağmen, AMH(p=0,004) seviyeleri ve antral folikül sayısının(p=0,001) istatistiksel olarak anlamlı farklılık gösterdiği belirlenmiştir. Semen

parametreleri açısından incelendiğinde, semen hacmi(p=0,361), sperm konsantrasyonu(p=0,172) ve morfolojisi(p=0,474) gruplar arasında benzer bulunmuş; ancak sperm motilitesi(p<0,001) Grup 3'te anlamlı olarak daha düşük tespit edilmiştir. Oosit kalitesi(p=0,191) üç grup arasında benzerlik göstermiştir. Grup 3'te, diğer gruplara kıyasla, ovaryan yanıt (FOI ve FORT) (p<0,001) ve klinik gebelik oranları (p<0,001) anlamlı derecede düşük bulunmuştur.

Sonuç:Bu çalışma, geç blastulasyonun olası etyolojik faktörlerini ortaya koymaktadır. İnfertilite etyolojisi, ovaryan yanıt ve sperm motilitesi, blastosist gelişim gününü önemli ölçüde etkilemektedir. Geç blastulasyon mekanizmalarının daha iyi anlaşılması ve bu duruma bağlı sikluslarda klinik başarı oranlarını artırmaya yönelik stratejilerin geliştirilmesi için ileri araştırmalara ihtiyaç duyulmaktadır.

Sözlü Bildiri

İMPLANTASYON VE DESIDUALIZASYON SÜREÇLERINDE KROMOZOMAL YOLCU KOMPLEKSININ YAŞLANMAYA BAĞLI OLASI DEĞIŞIKLIKLERININ ARAŞTIRILMASI

EZGİ GOLAL1, NURAY ACAR AYDEMİR1

1Akdeniz Üniversitesi, Tıp Fakültesi, Histoloji ve Embriyoloji Anabilim Dalı, Antalya, Türkiye

Özet

Giriş: Peri-implantif dönemde gerçekleşen embriyo gelişimi, uterus reseptivitesinin kazanılması, implantasyon ve desidualizasyon süreçleri gebeliğin sağlıklı ilerlemesi ve sonlanması için kritik öneme sahiptir. Yaşlanma ile gebelik oranlarının azalmasında ovaryum yaşlanmasının etkili olduğu düşünülmüş ancak son yapılan çalışmalarda yaşlanan uterusun da gebelik sürecini destekleyemediği gözlenmiştir. Kromozomal yolcu kompleksi üyeleri, mitoz bölünme sırasında sentromerlerden iğ ipliklerinin orta bölgesine hareket eden proteinlerdir. Kromozomal yolcu kompleksi, mitoz bölünme boyunca kromozom yoğunlaşması ve ayrılması ile mitozun sonunda sitokinezin tamamlanmasında işlev görür.

Amaç: Çalışmamızda kromozomal yolcu kompleksinde rol alan proteinlerden pIncenp, Aurora B, Survivin, Borealin ile proliferasyon belirteci Ki-67'nin ekspresyon değişimleri yaşlanma sürecindeki peri-implantif dönem fare implantasyon ve desidualizasyon bölgelerinde araştırılmıştır.

Materyal&Metod: Balb/C ırkı fareler (12, 20 ve 26-32 haftalık) bir erkek ve iki dişi olacak şekilde gece boyu aynı kafeste tutuldu, ertesi gün vajinal plak görülen dişi fareler gebeliğin birinci gününde kabul edildi. Gebeliğin 5, 6 ve 8. günlerinde farelerin implantasyon bölgeleri elde edildi. pIncenp, Aurora B, Survivin, Borealin ve Ki-67'nin lokalizasyonları immünohistokimya ile pIncenp, Aurora B, Survivin ve Borealin ekspresyonları Western blot yöntemleriyle belirlendi. Yaşlanma sürecinde ekspresyon değişimleri incelendi.

Bulgular: pIncenp, Aurora B, Survivin, Borealin ve Ki-67 gebeliğin farklı günlerinde implantasyon ve desidualizasyon bölgelerinde farklı yoğunluklarda ekspre edildi. İmmünohistokimya sonuçlarımıza göre Ki-67 gebeliğin 5. gününde lümen ve bez epitelinde yaşlanmayla beraber azaldı. pIncenp ve Survivin ekspresyonu gebeliğin 5. gününde, stroma bölgelerinde yaşlanan gebe grupta genç gebe gruba kıyasla arttı. Gebeliğin 6. gününde lümen epitelinde, immünohistokimya sonuçlarımıza göre genç gruplara kıyasla yaşlanan gruplarda, pIncenp, Borealin, Survivin ekspresyonları arttı. Gebeliğin 8. gününde yaşlı gruptaki Aurora B ekspresyonu genç gruplara kıyasla fazlaydı.

Sonuç: pIncenp, Aurora B, Survivin, Borealin ve Ki-67 gebeliğin farklı günlerinde yaşlanma sürecindeki farelerin implantasyon ve desidualizasyon bölgelerinde farklı düzeyde ekspre edilmektedir. Bulgularımız, farelerde implantasyon ve desidualizasyon süreçlerinde kromozomal yolcu kompleksinin önemli rollere sahip olabileceğini düşündürmüştür. Çalışmamız sonucu elde ettiğimiz bulguların, ileride implantasyon başarısızlığı ve tekrarlayan gebelik kayıplarında kromozomal yolcu kompleksinin araştırılacağı yeni çalışmalara ışık tutabileceğini öngörmekteyiz.

Not: Bu çalışma 222S872 numaralı TÜBİTAK 1002-A Hızlı destek projesi ile desteklenmiştir.

Poster Bildiri

MONOSODYUM GLUTAMAT İLE OLUŞTURULAN KARACİĞER HASARINDA FERULİK ASİTİN İYİLEŞTİRİCİ ETKİSİ

SEDA SEZER[1,2], ANIL CAN[1,2], MERVE ELMAS[1], MELTEM KOLGAZİ[3], SERAP ARBAK[1]

1 Histoloji ve Embriyoloji ABD, Tıp Fakültesi Acibadem Mehmet Ali Aydinlar Üniversitesi, arbaks@yahoo.com
2 Sağlık Bilimleri Enstitüsü, Histoloji ve Embriyoloji Yüksek Lisans Programı Mehmet Ali Aydinlar Üniversitesi;
3 Fizyoloji ABD, Tıp Fakültesi Acibadem Mehmet Ali Aydinlar Üniversitesi; İstanbul Türkiye

Özet

Giriş: Monosodyum glutamat (MSG) 'ın oksidatif stres yaratarak dokular üzerinde hasara yol açtığı bilinmektedir. Bu çalışmada MSG ile indüklenen deneysel karaciğer hasarında antioksidan özelliklere sahip olduğu bilinen ferulik asitin (FA) tedavi edici etkisi araştırılmıştır.

Gereç Ve Yöntem: Çalışmada Wistar albino erkek sıçanlardan oluşan 5 deney grubu (n: 8) oluşturuldu. Kontrol grubundaki sıçanlara 38 gün boyunca 1ml distile su, DMSO+FA grubundaki sıçanlara ise 28 gün boyunca 1ml DMSO ve deneyin son 10 gününde ise FA (25mg/kg) gavaj ile uygulandı. MSG grubundaki sıçanlara gavaj ile 28 gün boyunca 600 mg/kg MSG verildi. MSG+DMSO grubundaki sıçanlara ise, gavaj ile 28 gün boyunca 600mg/kg MSG ve deneyin son 10 günü 1 ml DMSO verildi. MSG+FA grubundaki sıçanlara 600 mg/kg MSG 28 gün boyunca gavaj yöntemi ile verilmiş olup, deneyin son 10 günü 25 mg/kg FA verildi. Deney sonunda alınan karaciğer doku örnekleri histokimya, immünhistokimya, geçirimli elektron mikroskobik ve biyokimyasal analizler) için hazırlandı. Doku örneklerine eNos immünhistokimyası uygulandı.

Bulgular:Kontrol ve DMSO+FA gruplarında histokimyasal, immünohistokimyasal, ultrastrüktürel ve biyokimyasal parametreler normal düzeyde izlendi. MSG ve MSG+DMSO grubunda hepatosit sitoplazmasında steatoz ve glikojen içeriğinde azalma, sinüzoidlerde dilatasyon, parankimada lökosit infiltrasyonu, bağ dokusu artışı ve eNOS ekspresyonunda azalma görüldü. MSG+FA grubunda normale yakın morfoloji ve eNOS expresyonu gözlemlendi. MSG ve MSG+DMSO gruplarında biyokimyasal parametrelerde bozulmalar izlenirken, MSG+FA grubunda ise tüm bu değerlerde iyileşme izlendi. ALT, AST ve TBLB seviyelerinde istatiksel olarak anlamlı bir fark gözlemlenmedi.

Sonuç:Bu çalışmada, karaciğer dokusunda MSG ile oluşturulan deneysel hasarda FA'in oksidatif hasarı engelleyerek iyileştirici etkisi olduğu sonucuna ulaşıldı.

Anahtar Sözcükler: Monosodyum Glutamat, Oksidatif Stres, Karaciğer, Ferulik Asit, Mikroskop

Poster Bildiri

SIÇANLARDA SIKLOFOSFAMID ILE OLUŞTURULAN BÖBREK VE MESANE HASARINA KARŞI KLOROJENIK ASIT'IN ETKILERI*

SEDANUR YILMAZ DOĞAN[1], DERYA ÖZTÜRK OKATAN[2], MUSTAFA MERT SAĞLAM[3], SELİM DEMİR[4], NİHAL TÜRKMEN ALEMDAR[5], YÜKSEL ALİYAZICIOĞLU[5], GÖKÇEN KERİMOĞLU[2]

1 Trabzon Kanuni Eğitim ve Araştırma Hastanesi, Trabzon, Türkiye
2 Karadeniz Teknik Üniversitesi Tıp Fakültesi, Histoloji ve Embriyoloji AD, Trabzon, Türkiye
3Karadeniz Teknik Üniversitesi Tıp Fakültesi, Aile Hekimliği AD, Trabzon, Türkiye
4 Karadeniz Teknik Üniversitesi Sağlık Bilimleri Fakültesi, Beslenme ve Diyetetik Bölümü, Trabzon, Türkiye
5 Karadeniz Teknik Üniversitesi Tıp Fakültesi, Tıbbi Biyokimya AD, Trabzon, Türkiye
derya_109@yahoo.com

Özet

Giriş: Otoimmün hastalıkların, malignitelerin tedavisinde kullanılan alkilleyici bir ajan olan siklofosfamid (CP), sağlıklı hücrelerde toksik etkilere sebep olabilir. Çeşitli sebze ve meyvelerde bulunan klorojenik asit (CGA) ise antioksidan, antiapopitotik, antiinflamatuvar etkilere sahiptir.

Amaç: Çalışmamızda; sıçanlarda CP ile oluşturulan böbrek ve mesane hasarında CGA'nın profilaktik etkileri histolojik ve biyokimyasal olarak araştırılmıştır.

Materyal-Metot: Sprague Dawley ırkı 18 sıçan rastgele 3 eşit gruba (Kontrol, CP ve CP+CGA) ayrıldı. Denekler; deneyin ilk ve son günü tartıldı. Kontrol grubuna; 7 gün oral 2cc/gün fosfat tamponlu salin (PBS) ve 7. gün tek doz intraperitoneal (i.p.) 2cc serum fizyolojik (SF) uygulandı. CP grubuna deneyin 7. gününde 2cc SF içinde 150mg/kg tek doz i.p. CP uygulandı. CP+CGA grubuna ise 7 gün oral 2cc PBS içinde 100mg/kg/gün CGA ve 7. günde 2cc SF içinde 150mg/kg tek doz i.p. CP uygulandı. Böbrek ve mesane dokuları; hematoksilen-eozin, periyodik asit-Schiff ve TUNEL ile boyandı. Böbrek dokuları; ödem-hemoraji, tübüler dejenerasyon ve glomerüler dejenerasyon için ayrı ayrı 0(normal) ile 3(şiddetli hasar) arasında skorlandı. Mesane dokuları ise; 1(normal), 2(hafif ödem-inflamasyon), 3(orta ödem-inflamasyon ve epitelde fokal ülserasyon-hafif hemoraji) ve 4(şiddetli ödem-inflamasyon ve epitelde yaygın ülserasyon-hemoraji) olarak skorlandı. Biyokimyasal olarak dokularda süperoksit dismutaz (SOD), katalaz (CAT), glutatyon (GSH), malondialdehit (MDA), miyeloperoksidaz (MPO), tümör nekroz faktör-alfa (TNF-α), total antioksidan durum (TAS), total oksidan durum (TOS), oksidatif stres indeksi (OSİ) ve serumda BUN, kreatinin seviyeleri belirlendi.

Bulgular: Deneyin son gününde CP+CGA grubunun böbrek, mesane ve vücut ağırlıkları diğer gruplardan düşüktü. CP grubu böbrek dokularında ödem, hemoraji, tübüler ve glomerüler dejenerasyon, Bowman kapsülü paryetal yaprağında kalınlaşma-ayrılma, tübül bazal membranlarında düzensizlik, proksimal tübülde fırçamsı kenar kayıpları izlendi. CP grubu mesanelerinde; mukozada ödem, hemoraji, ülserasyon, inflamatuvar hücre artışı, epitelde dökülme ve glikozaminoglikan tabakasında kayıplar mevcuttu. Böbrek ve mesaneye ait tüm bu patolojik bulgular CP+CGA grubunda CP grubuna göre düşüktü (Tablo1). Böbrek dokularında; CP grubunun MDA, TOS, OSİ, MPO, TNF-α değerleri kontrole göre yüksekken TAS, GSH, SOD değerleri düşüktü. CP+CGA grubunun MDA, TOS, OSİ, MPO değerleri

CP'ye göre düşükken GSH ise yüksekti. CP ve CP+CGA gruplarının serum BUN ve kreatinini kontrole göre yüksekti (Tablo2). Mesane dokularında CP grubunun MDA, OSİ, TNF-α, MPO değerlerinde kontrole göre artış mevcutken SOD'da düşüş gözlendi. CP+CGA grubunda ise MDA, OSİ, TNF-α, MPO seviyeleri CP grubuna göre düşükken SOD seviyesi yüksekti (Tablo3). Hem böbrek hem de mesane dokuları için CP ve CP+CGA gruplarının AI'leri kontrole göre yüksekken CP+CGA grubunun AI'i CP grubundan düşüktü (Tablo2 ve 3).

Sonuç: Profilaktik olarak oral uygulanan CGA, böbrek ve mesanede CP'nin indüklediği oksidatif stres, inflamasyon ve doku hasarını azaltabilir.
*Bu çalışma Karadeniz Teknik Üniversitesi Bilimsel Araştırma Projeleri Koordinasyon Birimi tarafından desteklenmiştir. Proje numarası: TU-2022-10159.

Poster Bildiri

POSTNATAL 21 – 49. GÜNLER ARASINDA UYGULANAN 900 MH Z ELEKTROMANYETIK ALANIN FARKLI GELIŞIM DÖNEMLERINDEKI ERKEK SIÇANLARIN TESTIS MORFOLOJISINE ETKISI

SEVAL KUVVET KURT[1], MUSTAFA KOLA[1], ALİ KULABER[1], ENGİN YENİLMEZ[1], SEMANUR IŞIK[1], TENZİLE BEYZA DURMUŞ[1], ELİF KOYUN ALVUROĞLU[1]

1 Karadeniz Teknik Üniversitesi, Tıp Fakültesi, Histoloji ve Embriyoloji Anabilim Dalı, Trabzon, Türkiye
dr.byzdrms@gmail.com

Özet

Giriş: Teknolojik ilerlemeler, gün geçtikçe teknolojik cihazların kullanım sıklığını artırmaktadır. Elektronik cihazlar genellikle çevrelerine elektromanyetik alan (EMA) yayarak çalışırlar, cep telefonları da bu duruma örnektir. Bu nedenle, özellikle cep telefonlarının çalışma frekans aralığı olan 900- 1800 MHz (Mega hertz) bandındaki elektromanyetik alanın canlı organizmalar üzerindeki etkileri büyük ilgi görmektedir (1-3). Bu alandaki araştırmaları incelediğinizde, çoğu değerlendirmenin elektromanyetik alan uygulamasından hemen sonra yapıldığını ve elektromanyetik alanın etkisinin uzun vadede nasıl olabileceğinin belirlenemediğini görebilirsiniz (4,5). Ulusal ve uluslararası önemli birçok kuruluşun yaptığı araştırmalarda 06-15 yaş gurubunun yaklaşık %24'ünden fazlasının cep telefonu kullandığı tespit edilmiştir (6). Bu istatistiklerden yola çıkarak, 15 yaş grubu çocuklardan yaklaşık bir milyar yedi yüz milyon tanesinin cep telefonunun oluşturduğu EMA' nın zararlı etkilerinin tehdidi altında olduğu söylenebilir. Bu iki önemli çıkış noktası göz önünde bulundurularak; postnatal (PN) 21-49 günleri arasında (adolesan dönemlerinin erken ve orta adolesan safhaları) 900 MHz EMA etkisine maruz bırakılan erkek sıçanların, farklı gelişim dönemlerindeki testislerinde meydana gelebilecek muhtemel değişikliklerin araştırılması hedeflendi.

Materyal & Metot: Çalışmaya Spraque Dawley cinsi 36 erkek sıçan dahil edildi. Temin edilen 36 hayvandan rastgele seçilerek, önce her biri 12'şer hayvandan oluşan 3 (Kontrol,Sham ve EMA) grup, daha sonra; oluşturulan bu 3 grup kendi aralarında 2 gruba (Kontrol 1, Kontrol 2; Sham 1, Sham 2; EMA 1, EMA 2) ayrılarak toplamda 6'şar hayvandan oluşan 6 grup oluşturulmuştur. Bu gruplardan Kontrol 1, Sham 1 ve EMA 1 grubu hayvanları, uygulanan deney prosedürünün hemen akabinde (Postnatal 50. gün); Kontrol 2, Sham 2 ve EMA 2 grubu hayvanlar ise, uygulanan deney prosedüründen 30 gün sonra (postnatal 79. gün) sakrifiye edilmişlerdir.Alınan testis doku kesitlerinde hematoksilen-eozin boyama yapılarak; STÇ (seminifer tübül çapı), GEK (germinal epitel kalınlığı), Ç/K (tübül çapının germinal epitel kalınlığına oranı) ve JS (Johnsen skorlama) parametreleri değerlendirildi. Veriler SPSS 23.0 ile analiz edildi. Mann-Whitney U testi normal dağılım göstermeyen verileri değerlendirirken, Kruskal-Wallis testi grupları karşılaştırdı. İstatistiksel anlamlılık $p<0,05$ olarak belirlendi.

Bulgular: İstatistiksel analize bakıldığında, Konrol 1 ve EMA 1 grupları arasında; JS, Kontrol 1 ve EMA 2 grupları arasında; STÇ, GEK ve Ç/K, Sham 1 ve EMA 1 grupları arasında; GEK ve JS, EMA 1 ve EMA 2 grupları arasında Ç/K ve JS, Kontrol 2 ve EMA 2 grupları arasında; Ç/K ve JS, Sham 2 ve EMA 2 grupları arasında da Ç/K ve JS, parametreleri anlamlılık göstermiştir.

Sonuç: Uygulanan 900 MHz manyetik alanın testiste oluşturduğu hasarın, uzun vadede kendiliğinden bir düzelme göstermediği ve oluşan hasarın etkilerinin organ üzerinde etkisini gösterdiği görülmüştür. İleri çalışmalarla sonuçların pekişmesini önermekteyiz.

Poster Bildiri

BISFENOL-S'NIN SIÇAN OVARYUM DOKUSU ÜZERINDEKI ETKILERININ ELEKTRON MIKROSKOBU ILE INCELENMESI

TUĞBA KOTİL

İstanbul Üniversitesi, İstanbul Tıp Fakültesi, Histoloji Ve Embriyoloji Anabilim Dalı
tkotil@istanbul.edu.tr

Özet

Çevresel kirleticilerin kullanımı günden güne artış göstermektedir. Kirleticiler, canlılarda başta endokrin sistemin işleyişini bozmakla beraber üreme sisteminin yapısı ve işleyişini de etkileyebilmektedir. En önemli endokrin bozuculardan biri olan Bisfenol A (BPA), zararlı etkilerinin ortaya çıkarılmasıyla kullanımına kısıtlamalar getirilmiş olmasına rağmen günlük yaşantımızda karşılaştığımız ürünlerin çoğunda halen Bisfenol türevleri bulunmaktadır. Günümüzde pek çok alanda BPA yerine Bisfenol S (BPS) kullanılmaya başlanmıştır. BPS kullanımının artmasıyla beraber akut ve kronik etkilerini incelemek için yapılan in vivo ve in vitro çalışmalar bulunmakla birlikte memelilerde toksisite çalışmaları sınırlı sayıdadır.

Amaç: BPS'nin sıçan ovaryum dokusu üzerindeki farklı dozlardaki etkilerinin elektron mikroskobu ile incelenmesi amaçlanmaktadır.

Materyal-Metod: Çalışmada, Wistar albino sıçanlar 4 gruba (n=7) (kontrol ve 3 deneysel (50 µg/kg/gün, 100 µg/kg/gün, 150 µg/kg/gün)) ayrıldı. BPS, 14 gün boyunca gavajla verildi. Ovaryumlar %2,5'lik gluteraldehit ve %1'lik osmiyum tetroksit ile tespit edildi. Rutin takip işlemlerinden sonra saf epon içeren kapsüllere gömüldü. İnce kesitler kontrastlandı, elektron mikroskopla (Jeol Jem 1011) incelendi.

Bulgular: Kontrol grubunda oolemma altında kortikal granüller, ooplazmada annulat lameller ve bol miktarda mitokondri mevcuttu (Şekil 1a). Poligonal şekilli granüloza hücrelerinde nuklear membran, nuklear porlar belirgindi ve ökromatik genetik materyal gözlendi. Sitoplazmada yaygın granüllü endoplazma retikulumu (GER) ve poliribozomlar vardı (Şekil 1b). Granüloza ve teka tabakaları arasındaki bazal lamina düzgün şekilliydi ve devamlılık gösteriyordu. Teka hücreleri intakt membran ve organel yapısına sahipti (Şekil 1c). 50µg grubunda ooplazmada annulat lamel birikimde kontrole göre artış vardı (Şekil 1d). Granuloza hücrelerinde mitokondride şişme, krista kaybı ve ER'da genişleme izlendi. Bazal lamina düzgündü (Şekil 1e, inset, 1f). 100µg grubunda granuloza hücrelerinde lipit birikimi, vakuolizasyon, mitokondride krista kaybı, şekil değişiklikleri ve miyelin benzeri yapı birikimleri mevcuttu (Şekil 1g,1h). Teka tabakasında intersellüler genişleme vardı. Bazal lamina kıvrımlı görünüm sergiliyordu (Şekil 1i). 150µg grubunda oositte fragmentasyon, ooplazmada, annulat lamel birikiminde yoğun artış, kortikal granüllerde azalma mevcuttu (Şekil 1j,1k). Granüloza hücrelerinde yassılaşma izlendi. Sitoplazmada lipid damlası birikimi, krista kaybına uğramış ve miyelin benzeri yapı içeren mitokondriyumlar vardı. İnterselüler alanda genişlemeler ve ödemli alanlar mevcuttu. (Şekil 1l,1m). Ayrıca nekrotik hücre grupları da izlendi (Şekil 1n). Bazal laminada düzensiz dalgalı görünüm vardı (Şekil 1m,1o). Teka hücrelerinin şekillerinde bozulma ve intersellüler alanda genişlemeler izlendi (Şekil 1o).

Sonuç: BPS maruziyeti sonucunda elde ettiğimiz bulgular, BPS'nin sıçan ovaryum dokusunda hücre düzeyinde doz artışına bağlı olarak ciddi ince yapısal değişikliklere yol açtığını göstermiştir. Kullanımının güvenli olduğunun kanıtlanması için daha kapsamlı çalışmalar gerekmektedir.

Teşekkür: Bu tez çalışması Sakarya Üniversitesi Bilimsel Araştırma Projeler Koordinatörlüğü (2022-7-24-155) ve TÜBİTAK (124Z036) tarafından desteklenmiştir.

Poster Bildiri

ABAMEKTIN MARUZIYETININ ZEBRA BALIĞI OVARYUM DOKUSU ÜZERINDEKI HISTOPATOLOJIK ETKISI: IŞIK MIKROSKOBI İNCELEMESI

SEVDA BAĞDATLI

Sakarya Üniversitesi Fen Fakültesi Biyoloji Bölümü, sevdabagdatli@sakarya.edu.tr

Özet

Giriş: Modern dünya düzeni her ne kadar insan yaşamında kolaylıklar oluşmasını sağlasa da; çevre sorunlarının da her geçen gün artmasına sebep olabilmektedir. Çeşitli kimyasallar ve pestisitler günlük hayatımıza tarımsal verimliliği ve üründe kalite artışını sağlamak amacı ile girmiştir. Fakat aynı zamanda çeşitli yollarla toprak ve suya karışıp, kirliliğe de sebep olmaktadırlar. Özellikle tarımda böceklerin verdiği zararı azaltmak için başvurulan insektisitler, kullanımı artan pestisitlerdendir.

Abamektin, bir insektisit ve altihelmintik ajan olarak tarımda kullanımına başvurulan kimyasallardandır. Ayrıca bu madde, Avermectin ailesinden en sık kullanılan bileşiklerdendir. Uygulandığı bölge dışında farklı yollarla sucul ortama da girip kirliliğe sebep olabilen Abamektin, akuatik organizmalar için de toksik etki gösterebilmektedir.

Model organizma olarak kullanılan hayvanlar canlılardaki biyolojik mekanizmaların nasıl çalıştığını anlamamıza yardımcı olmaktadır. Bu amaçla sıkça tercih edilen zebra balığı (*Danio rerio*) toksisite çalışmaları baz alınarak kimyasalların insanlar üzerindeki olası etkileri araştırılabilmektedir.

Amaç: Abamektin'in zebra balıkları ovaryum dokusu üzerindeki olası histopatolojik etkilerinin ışık mikroskobu ile incelenmesi.

Materyal Metod: Bu çalışmada, Abamektin'in zebra balığı ovaryum dokusu üzerindeki histopatolojik etkileri araştırılmıştır. Biri kontrol grubu olmak üzere dört adet deney grubu oluşturulmuştur ve her grupta 5 adet zebra balığı kullanılmıştır (n:5). Kontrol grubuna herhangi bir işlem yapılmazken, birinci deney grubu 0,75 µg L^{-1}, ikinci deney grubu 1,5 µg L^{-1} ve üçüncü deney grubu da 3 µg L^{-1} Abamektin'e maruz bırakılmıştır. 96 saatlik maruziyet sonucunda, balıklar yüksek dozda bir anestezik (MS-222, 300 mg/L) ile ötenaziye tabi tutulmuş ve ovaryum dokuları çıkarılarak rutin histolojik yöntemler uygulanmıştır. Hematoksilen-Eozin boyası kullanılarak hazırlanan ovaryum dokusu kesit örnekleri, ışık mikroskobu altında incelenmiş ve kontrol grubuyla karşılaştırılarak histolojik değişiklikler belirlenmiştir.

Bulgular: Abametktin uygulaması sonrasında zebra balığı ovaryum dokularında zona radiata ile ooplazma ve zona radiata ile foliküler epitel arasında açılma, zona radiatada distorsiyon, morfolojik bozulmalar ve kalınlaşma, atretik oosit oluşumunda artış, intertisyel alanda fibrosis, ooplazmada vakualizasyon ve dejenere olmuş folikül oluşumu, olgun ve vitellojenik oosit sayısında azalış ve hücrelerde nükleer alanda bozulmaların meydana geldiği görülmüştür. Ayrıca tüm bu görülen bulguların doz artışı ile paralel olarak artış gösterdiği belirlenmiştir.

Sonuç: Yaptığımız bu çalışma, Abamektin'in üreme üzerine olumsuz etkilerinin olduğunu göstermektedir. Elde edilen bulgular ışığında, Abamektin'in zebra balığı ovaryum dokusu üzerinde üreme potansiyelini engelleyici seviyede olduğu ve oogenez sürecine hasar verdiği söylenebilmektedir. Zebra balıklarında üreme toksisitesi oluşturduğu söylenebilen Abamektin'in potansiyel olarak insana da zarar verebileceği düşünülerek yapılan çalışmaların artması gerektiği yorumu yapılmaktadır.

Poster Bildiri

METCONAZOL'ÜN ERKEK BALB/C FARE KARACİĞER DOKUSUNDA TOKSIKOLOJIK ANALIZI

TARIK DİNÇ

Sakarya Üniversitesi Fen Fakültesi Biyoloji Bölümü, tdinc@sakarya.edu.tr

Özet

Giriş: Son yıllarda artan çevre kirliliği ve bu kirliliğin ekosistemler üzerindeki olumsuz etkileri, küresel bir sorun haline gelmiştir. Sanayileşme, tarımda kullanılan kimyasallar ve çeşitli ilaçlar, çevre kirliliğine önemli ölçüde katkıda bulunmaktadır. Tarımda zararlıları yok etmek amacıyla yaygın olarak kullanılan pestisitlerin tarım alanlarında yaygın kullanımı, bu kirliliğin başlıca kaynaklarından biridir. Bitkilerde mantar enfeksiyonlarının önlenmesi için pestisit türevi olan fungusitler kullanılmaktadır. Konazol türevi fungisitler, buğday hastalıklarından sarı pas ve yaprak lekesi kontrolünde özellikle etkili olmaları nedeniyle sıklıkla tercih edilmektedir. Ancak bu kimyasallar, hedeflenmeyen organizmalar üzerinde toksik etkiler yaratabilmektedir.

Amaç: Bu çalışmanın amacı, BALB/c erkek fareleri üzerinde konazol türevi bir fungusit olan Metconazole'ün karaciğer dokusundaki histolojik etkilerinin incelenmesi amaçlanmıştır.

Materyal ve Metot: Sakarya Üniversitesi Tıp Fakültesi Deney Hayvanları Merkezinden (SÜDETAM) temin edilmiş olan 8 haftalık BALB/c (17,7-30,2 gr) 23,8±2,5 g erkek fareleri model organizma olarak kullanılmıştır. Çalışmamız Sakarya Üniversitesi Hayvan Deneyleri Yerel Etik Kurulu'ndan 19/02/2024 tarihli ve 09 nolu kararla etik onay almıştır. Deneysel çalışmalarımız Sakarya Üniversitesi Tıp Fakültesi Deney Hayvanları Merkezi'nde (SÜDETAM) gerçekleştirilmiştir. Çalışmada, BALB/c erkek fareleri model organizma olarak kullanılmıştır. Fareler temin edildikten sonra rastgele her bir grupta 6 fare olacak şekilde 4 gruba ayrılmıştır. Deney grupları, oral gavaj kullanılarak 15 gün boyunca kontrol, 37,5, 75 ve 150 mg/kg/gün dozlarında Metconazole'e maruz bırakılmıştır. Fareler yüksek doz ketamin/ksilazin (300/30 mg/kg) kullanılarak sakrifiye edilmiştir. Karaciğer dokuları 5 mm büyüklüğünde alınarak doku takibi yapılmıştır. Parafin bloklara alındıktan sonra 5 µm kalınlığında kesitlere hematoksilin-eozin boyama yöntemi uygulanmıştır. Leica DM500 mikroskop ve Leica MC170 görüntüleme sistemleri ile doku örnekleri analiz edilmiştir.

Bulgular: Metconazole'e maruz kalan farelerin karaciğer dokusunda belirgin hiperemi, piknotik hücre ve vakualizasyon gözlenmiştir. Yüksek dozda Metconazole uygulanan gruplarda, bu bulguların yanı sıra karaciğer dokusunda dejenere endotel yapısı belirlenmiştir.

Tartışma: Elde edilen bulgular, Metconazole'ün BALB-C erkek farelerinin karaciğer dokusu üzerinde belirgin toksik etkiler yarattığını göstermektedir. Bu sonuçlar, konazol türevi pestisitlerin kullanımı sırasında çevresel ve biyolojik risklerin dikkate alınması gerektiğini vurgulamaktadır.

Poster Bildiri

YÜKSEK YAĞLI DIYET İLE OLUŞTURULMUŞ KARACIĞER YAĞLANMASI MODELINDE PYRROLOQUINOLINE QUINONE UYGULAMASININ HISTOLOJIK DEĞERLENDIRMESI

ÇİSEM YEŞİL KAYABAŞI | ZEYNEP YIĞMAN | SUNA ÖMEROĞLU | BURAK KAYABAŞI | AYŞE MELTEM SEVGİLİ | SİBEL DİNÇER

Gazi Üniversitesi Tıp Fakültesi, Histoloji Ve Embriyoloji Anabilim Dalı, Ankara, Türkiye
drcisemyesil@hotmail.com

Özet

Giriş: Non-Alkolik Yağlı Karaciğer Hastalığı (NAYKH) obezite, dislipidemi, insülin direnciyle ilişkili olan, prevelansı giderek artan, küresel bir sorundur. NAYKH'ın patogenezinde oksidatif ve inflamatuar süreçler, mitokondriyal disfonksiyon rol oynamaktadır. Pyrroloquinoline quinone (PQQ), mitokondriyal biyogenezde rol oynayan, antiinflamatuar, antioksidan özellikleri olan kinon kofaktör grubundan bir moleküldür.

Amaç: Yüksek yağlı diyet (YYD) ile sıçanlarda oluşturulmuş yağlı karaciğer hastalığı modelinde antioksidan, antiinflamatuar, mitokondriyi uyarıcı özellikleri nedeniyle NAYKH'da yararlı olabileceğini düşündüğümüz PQQ'nun etkinliğini değerlendirmeyi amaçladık.

Materyal-Metod: Çalışmamızda 200-250 gram ağırlığındaki 29 adet erkek Wistar Albino sıçan; Kontrol (n:7), YYD (n:8), YYD+PQQ10 (n:7) ve YYD+PQQ20 (n:7) olmak üzere 4 gruba ayrıldı. YYD grupları çalışma süresince (9 hafta) yüksek yağlı diyet ile beslendi. Çalışmanın son üç haftasında ise YYD+PQQ10 grubuna 10 mg/kg/gün PQQ ve YYD+PQQ20 grubuna 20 mg/kg/gün PQQ uygulamaları oral gavaj ile yapıldı. 9. haftanın sonunda sıçanlar sakrifiye edildi. Sıçanların alınan karaciğer dokuları rutin doku takibinden sonra parafin bloklar haline getirildi. Elde edilen kesitler Hematoksilen Eozin ile boyandı. İstatistiksel analizde Kruskal-Wallis analizi yapıldı, sonucun anlamlı bulunması halinde post-hoc analiz olarak Dunn testi kullanıldı ve $p<0,05$ değeri istatistiksel olarak anlamlı kabul edildi. Çalışma G.Ü.ET-23.047 kod numarasıyla etik kurul onayı almıştır ve Gazi Üniversitesi-BAP birimi tarafından TTU-2023-8802 koduyla desteklenmektedir.

Bulgular: Steatoz, hepatoselüler balonlaşma ve lobüler inflamasyon skorlamalarından oluşan NAYKH Aktivite Skoru (NAS) ile birlikte gruplar arası farklılıklar değerlendirildi. YYD grubunda karaciğer steatoz oranı %66'nın üzerinde ve NAS skoru ise 5'in üzerinde bulundu. YYD grubunda steatoz, kontrol grubuna göre anlamlı olarak yüksek bulundu ($p<0,0001$), PQQ tedavisi alan YYD gruplarında ise kontrol grubuna göre anlamlı farklılık görülmedi (Kontrol-YYD+PQQ10,$p=0,283$; Kontrol-YYD+PQQ20,$p=0,937$). YYD+PQQ20 grubunda steatoz, YYD grubuna göre anlamlı olarak düşük bulundu ($p=0,008$). YYD grubunda balonlaşma, kontrol grubuna göre anlamlı olarak yüksek bulunmakla ($p<0,0001$) birlikte PQQ tedavisi alan YYD gruplarında kontrol grubuna göre anlamlı farklılık görülmedi (Kontrol-YYD+PQQ10,$p=0,08$; Kontrol-YYD+PQQ20,$p=0,08$). İnflamatuar hücre infiltrasyonu değerlendirmesinde ise YYD ve YYD+PQQ10 gruplarında, kontrol grubuna göre anlamlı yükseklik mevcuttu (Kontrol-YYD,$p=0,0027$; Kontrol-YYD+PQQ10,$p=0,0499$). İnflamatuar

hücre infiltrasyonu açısından YYD+PQQ20 grubu ile kontrol grubu değerlendirildiğinde anlamlı farklılık görülmedi (p=0,07). Toplam NAS Skoru YYD grubunda, kontrol grubuna göre anlamlı olarak yüksek bulundu (p<0,0001). PQQ uygulanan YYD gruplarının NAS Skoru ile kontrol grubu arasında anlamlı farklılık görülmedi (Kontrol-YYD+PQQ10,p=0,068; Kontrol-YYD+PQQ20,p=0,190). Ayrıca YYD+PQQ20 grubunun NAS Skoru, YYD grubuna göre anlamlı olarak düşük bulundu (p=0,038). YYD grubunun NAS Skoru 5'in üzerinde iken, PQQ tedavisi alan YYD gruplarının NAS Skoru 5'in altındaydı.

Sonuç: Karaciğer yağlanması üzerine olumlu histolojik değişikliklerini göstermiş olduğumuz PQQ uygulaması farklı çalışmalarla da desteklendiği takdirde yağlı karaciğer hastalığında destek tedavi protokollerinde yer alabilir.

Poster Bildiri

GLIOBLASTOMA TEDAVISI İÇIN NANO-MIKRO GÖZENEKLI SPIRULINA YÜKLÜ İLAÇ TAŞIYICI BIYOMATERYALIN GELIŞTIRILMESI

BÜŞRA ÖNCEL DUMAN[1] | BÜŞRA HASEKİ[2] | İBRAHİM ÖZBEK[2] | MUHAMMED ENES KAYA[2] | YUSUFHAN YAZIR[3]

[1]Kocaeli Sağlık Ve Teknoloji Üniversitesi, Avrupa Myo, Tıbbi Laboratuvar Teknikleri Programı | [2]Kocaeli Sağlık Ve Teknoloji Üniversitesi, Eczacılık Fakültesi | [3]Kocaeli Üniversitesi, Sağlık Bilimleri Enstitüsü, Kök Hücre Ad., Kocaeli Üniversitesi, Tıp Fakültesi Histoloji Ve Embriyoloji Ad.
220601050@kocaelisaglik.edu.tr

Özet

Giriş: Primer beyin tümörlerinin yaklaşık %20-30 unu oluşturmakta olan glioblastoma (GBM) en hızlı seyirli ve ölümcül bir tümördür. GBM in medikal tedavisinde kullanılan yöntemler glioblastomanın çıkarılması için cerrahi, kemoterapi, radyoterapi, elektrik alan tedavisi ve hedeflenmiş ilaç tedavisidir. Hastalığın tedavisi için kullanılan ilaçlar, anjiogenezin en yoğun olduğu tümörlerden biri olan bu hastalıkta ve VEGF reseptörü üzerinden yeni damar oluşumunu baskılamayı hedeflemiştir. Nitrozüre sınıfı sentetik DNA alkilleyici madde olan lomustin, avastin, TMZ (Temozolomid) gibi ajanlar tekrarlayan glioblastomlu hastalarda faz 2 ve 3 klinik araştırmalarda yaygın olarak kullanılmıştır. Bu ajanların etkinliklerine rağmen belirgin kemik iliği baskılanması yan etkileri genel kullanıma girmelerini kısıtlamıştır. Dolayısıyla GBM hücrelerine sitotoksik olabilecek başka bir moleküle ihtiyaç duyulmaktadır. Spirulina; antiviral, antikanser, hipokolesterolemik, anti-diyabetik, antioksidan, anti-inflamatuar ve anti-metastaz aktivitelerine sahip, yüksek amino asit içeriğine (%62) sahip, doğanın en zengin B12 vitamini kaynağı olarak kabul edilir. Bu özellikler Spirulina'yı biyomedikal uygulamalar için potansiyel bir farmasötik yapmaktadır. Son yıllarda farmasötik araştırmalarda, sistemik ilaçların kontrollü salımı büyük ilgi uyandırmaktadır. Bu çalışmamızda yeni bir yöntem olarak geliştireceğimiz nano/mikro gözenekli makrosünger sistem teknolojisi de bu ihtiyaca cevap veren, gözenekli, polimerik makroküre sistemleridir. Amaç: GBM tedavisinde yeni bir ilaç taşıyıcı sistem geliştirerek içine spirulina etken maddesi yüklenmesidir.Materyal-Metot: Nano/mikro gözenekli aljinat makrosüngerler, agaroz jelden kuyucuklu kalıp elde edildikten sonra bu kalıbın üzerindeki kuyucuklara su ile %2 ve %4 low viskoz Aljinat konsantrasyonunda hazırlanan sodyum aljinat çözeltisi eklenerek hazırlandı. Nano/mikro gözenekli aljinat makrosüngere şişme kapasitesi, SEM, FTIR ve reometre analizleri ile karakterizasyon testleri gerçekleştirildi. Yüklenen spirulinanın proteinin salım profilinin ve yükleme verimliliğinin belirlenmesi için mikro BCA testi uygulandı. Bulgular: Makrosüngerlerin şişme özellikleri, kapsüllerin 14 gün boyunca kültür besiyerinin içinde sıvı tutma kapasitesi ve buna bağlı olarak hacminde oluşan değişiklik ile belirlendi. Kapsüllerin yapılan inceleme sonucu taşıdıkları por çapının farklı boyutlarda olduğu tespit edildi. Malzemede artan shear strese bağlı olarak viskozitede azalma görüldü. Mikro BCA testi sonrası spirulina proteinin başarılı bir şekilde makrokapsül içerisine yüklendiği tespit edildi.Sonuç: Çalışmamızda GBM hastalığında tedavi amacıyla kullanılabilecek makrosünger aracılı ilaç salınım sistemi geliştirilmiştir. Bir sonraki basamak olarak çalışmamızda spirulina içeren alginat süngerlerin T98G hücreleri üzerindeki etkileri ve anti-metaztaz ve antianjiyojenik potansiyelleri in-vitro ortamda test edilecektir. Olumlu sonuçlar alındığında geliştirilmiş olan spirulina içeren ilaç salınım sisteminin iyileştirici etkileri gelecek çalışmalarda in-vivo olarak gözlemlenmesi planlanmaktadır. Hastaların maddi açıdan daha

kolay ulaşabileceği etken madde içeren non-farmakolojik ajan ile tedavi edilebilmesinde kullanılabilecek makrosünger aracılı ilaç salım sistemleri konusunda derinlemesine bir bilgi elde edilmiş olacaktır.

FULL TEXT BOOK

DOKSORUBISIN KAYNAKLI KARDIYOTOKSISITEDE ÜZÜM (VITIS VINIFERA L.) ÇEKIRDEĞI EKSTRAKTININ KORUYUCU ETKISININ ARAŞTIRILMASI

EMİNE SARMAN[1]*, İBRAHİM AYDIN CANDAN[2], JALE AKGÖL[3], İREM NAZIROĞLU[1]

*[*1] Afyonkarahisar Sağlık Bilimleri Üniversitesi, Tıp Fakültesi, Histoloji ve Embriyoloji A.D., Afyonkarahisar, Türkiye, emine.sarman@afsu.edu.tr*

[2] Alanya Alaaddin Keykubat Üniversitesi, Tıp Fakültesi, Histoloji ve Embriyoloji A.D., Alanya, Türkiye, ibrahim.candan@alanya.edu.tr

[3] Afyonkarahisar Sağlık Bilimleri Üniversitesi, Tıp Fakültesi, Tıbbi Farmakoloji A.D., Afyonkarahisar, Türkiye, jale.akgol@afsu.edu.tr

ÖZET

Kanser, dünyada morbidite ve mortalitenin önde gelen nedenlerinden biridir. Doksorubisin (DXR), geniş spektrumlu antrasiklin türevi antibiyotiklerden biri olarak kanser tedavisinde kullanılmaktadır. Vitis vinifera L. (VIT)'nin güçlü bir antioksidan özelliğinin olduğu ve serbest radikalleri temizleme kapasitesinin yüksek olduğu bildirilmiştir. Bu çalışmada, ratlarda DXR kaynaklı kalp hasarına karşı VIT etkisinin araştırılması amaçlanmıştır.

30 adet erkek rat, rasgele her grupta 6 hayvan olacak şekilde 5 gruba ayrılmıştır: Kontrol grubu: Ad libitum su ve yemle beslenen grup. Sham grubu: 14 gün gavajla distile su verilen sıçanlara, deneyin 5. gününde intraperitoneal (i.p.) serum fizyolojik uygulaması yapılan grup. DXR Grubu: Deneyin 5. Günü 15 mg/kg tek doz i.p. DXR uygulanan grup. DXR+VIT: 14 gün boyunca gavajla 120 mg/kg VIT uygulanan sıçanlara deneyin 5. Günü 15 mg/kg tek doz i.p. DXR uygulanan grup. VIT: 14 gün boyunca gavajla 120 mg/kg VIT uygulanan grup. Son ilaç uygulamasından 24 saat sonra deney hayvanları anestezisi altında sakrifiye edilerek kan ve kalp dokuları alınarak incelenmiştir.

DXR grubunda kas liflerinde düzensizleşme, ayrılma ve bozulma, kas lifleri arasında kollajenöz madde birikimi, damarlarda konjesyon görülmüştür. İmmunohistokimyasal incelemelerde DXR grubunda kaspaz-3, NF-κB-p65 (Nükleer Faktör-kappa B-p65), TNF-α (Tümör Nekroz Faktörü-α) yoğun bir boyanma görülürken, DXR+VIT grubunda boyanmanın şiddeti önemli derecede azalmıştır. TOS (Total Oksidan Seviye) ve TNF-α düzeyleri DXR grubunda anlamlı artarken, DXR+VIT grubunda ise azalmıştır. TAS (Total Antioksidan Seviye) düzeyi ise VIT ve DXR+VIT gruplarında anlamlı olarak artmıştır.

DXR'nin apoptotik süreci hızlandırdığı, oksidatif stresi ve inflamasyonu arttırdığı görülmüştür. VIT'in ise kardiyak yeniden yapılanmayı hızlandırdığı ve DXR kaynaklı kalp hasarına karşı koruyucu bir etkisinin olduğu görülmüştür.

Anahtar Kelimeler: Doksorubisin, Vitis vinifera L., Kaspaz-3, NF-κB-p65, TNF-α

GİRİŞ

Doksorubisin (DXR), özellikle meme kanseri ve çeşitli lösemiler olmak üzere çeşitli malignite tiplerini tedavi etmek için kullanılan bir antrasiklin kemoterapötik ajandır (1). DXR, kemoterapi gören hastalarda önemli mortalite ve morbiditeye yol açabilen ciddi kardiyotoksisiteye neden olur (1).

DXR'nin antitümör ve antimikrobiyal aktivite açısından çok etkili olduğu gösterilmiş olsa da, giderek artan sayıda çalışma doksorubisinin neden olduğu potansiyel kardiyotoksisiteyi ortaya koymaktadır (2). DXR kaynaklı kardiyotoksisitenin mekanizması tam olarak anlaşılmamıştır, ancak birkaç çalışma bazı ipuçları sağlamıştır. Bunlar arasında oksidatif stres, inflamatuar yanıt, endoplazmik retikulum stresi, apoptozis, iyon kanallarının disfonksiyonu ve otofaji, doksorubisin kaynaklı kardiyotoksisite sürecinde yer aldığı bulunmuştur (3). Mitokondri, enerji üretimini değiştirerek, reaktif oksijen türleri (ROS) üreterek ve hücre ölüm yollarını aktive ederek DXR kaynaklı kardiyotoksisitede önemli bir rol oynar (4).

DXR kaynaklı kardiyotoksisitede, toksisiteyi hafifletmek için antioksidanların kullanımını araştırmak için çok sayıda araştırma yapılmış ve tartışmalı sonuçlar elde edilmiştir. Hayvan deneyleri genellikle antioksidanların ve/veya ROS temizleyicilerinin DXR ile birlikte uygulanmasını içermiş ve genel olarak olumlu sonuçlar vermiştir. C, E gibi vitaminlerin kardiyomiyositlerde veya kardiyak hücre hatlarında oksidatif stresi bastırdığı gösterilmiştir (5). Antioksidanların birlikte uygulanmasının ayrıca DXR kaynaklı kardiyomiyopatinin in vivo kemirgen modellerinde kardiyak disfonksiyonu hafiflettiği gösterilmiştir (6). *Vitis vinifera*, dünya çapında yetiştirilir ve terapötik uygulamaya sahip olduğunu gösteren çalışmalar bulunmaktadır. Kanıtlanmış anti-inflamatuar, antioksidan, antimikrobiyal ve yara iyileştirici özellikleri vardır (7). Biz de araştırmamızda bu nedenle üzüm (*Vitis vinifera* L.) (VIT) ile ilgili bir çalışma yapmayı tercih ettik. Çalışmamızın amacı, ratlarda DXR kaynaklı kalp hasarına karşı VIT çekirdeği ekstraktı etkisinin araştırmaktır.

MATERYAL-METOT

Afyon Kocatepe Üniversitesi Hayvan Deneyleri Yerel Etik Kurulundan 08.11.2023 tarihli 49533702 sayılı 116 numaralı karar ile etik kurul onayı alınmıştır.

Ratlar 21-22 derece arasında, 12 saat aydınlık 12 saat karanlık ortamda bakılmış ve ad libutium beslenme rejimi uygulanmıştır. 30 adet erkek rat, rasgele her grupta 6 hayvan olacak şekilde 5 gruba ayrılmıştır: Kontrol grubu: Ad libitum su ve yemle beslenen grup. Sham grubu: 14 gün gavajla distile su verilen sıçanlara, deneyin 5. gününde intraperitoneal (i.p.) SF uygulaması yapılan grup. DXR Grubu: Deneyin 5. Günü 15 mg/kg tek doz i.p. DXR uygulanan sıçanlardan oluşan grup. DXR+VIT: 14 gün boyunca gavajla 120 mg/kg *Vitis vinifera* L. (VIT) çekirdeği ekstraktı uygulanan sıçanlara deneyin 5. Günü 15 mg/kg tek doz i.p. DXR uygulanan sıçanlardan oluşan grup. VIT: 14 gün boyunca gavajla 120 mg/kg VIT çekirdeği ekstraktı uygulanacak sıçanlardan oluşan grup.

Son ilaç uygulamasından 24 saat sonra deney hayvanları Ketamin (90 mg/kg) / Xylazin (8-10 mg/kg) anestezisi altında sakrifiye edilerek kalp dokuları alınmıştır. Dokular histopatolojik incelemeler için %10 nötral tamponlu formaldehit solüsyonu içine alınmıştır. 72 saat formaldehit içinde kaldıktan sonra bir gece akarsu altında yıkanmıştır. Rutin histolojik takip işlemlerinden geçirildikten sonra dokular parafin bloklara gömülmüştür. Parafin kesitlerden 5µ kalınlığında kesitler alınmıştır. Histolojik incelemeler için kesitler histokimyasal ve immunohistokimyasal olarak boyanarak ışık mikroskobunda değerlendirilmiştir.

Hematoksilen-Eozin (HE)

Hematoksilen-Eozin boyama için alınan kesitler 1 gece 60^0C'lik etüvde bekletilip deparafinizasyon işlemi yapıldıktan sonra 15 dakika ksilole alınmıştır. Daha sonra sırasıyla 10'ar dakika %100- %96- %90-%80- %70 alkolden geçirilerek distile su ile yıkanmıştır. Harris Hematoksilen'de 2 dakika boyanmıştır. %1 asit-alkol karışımına batırılıp tekrar 2 dakika akar suda yıkanmıştır. 2 dakika Eozinde bekletilip %70, %80, %96, %100 alkolden geçirilerek 5 dakika ksilole alınmıştır. Son olarak entellan ile kapatılarak incelemeye hazır hale getirilmiştir. Hazırlanan preparatlar Eclipse E-600 Nikon, Japan fotomikroskopta ve görüntü analiz sistemi (NIS Elements Nikon, Japan) ile incelenerek değerlendirilmiş ve fotoğraflanmıştır. Değişikliğin derecesine ve yaygınlığına bağlı olarak semi-kantitatif olarak skorlandı. Hazırlanan preparatlardaki alanlarda görülen kas liflerinde düzensizleşme, ayrılma ve bozulma, kas lifleri arasında kollajenöz madde birikimi, damarlarda konjesyon 0'dan 3'e kadar derecelendirilmiştir.

İmmunohistokimyasal Analiz

Parafin bloklardan 5µ kalınlığında kesitler alındıktan sonra deparafinize edildi. H_2O_2 ve UV blok solüsyonu ile muamele edildikten sonra Kaspaz-3, NF-κB-p65, TNF-α ile 60 dk. inkübe edildi. Sekonder antikor ve Strepavidin HRP ile 30 dk oda ısısında inkübe edildi. DAB (3,3'-diaminobenzidine) solüsyonu damlatılarak görüntü sinyali alındıktan sonra Mayer's hematoksilen ile zıt boyaması yapılan dokular entellan ile kapatıldı. Tüm preparatlar Eclipse E-600 Nikon, Japan fotomikroskopta ve görüntü analiz sistemi (NIS Elements Nikon, Japan) ile incelenerek değerlendirildi ve fotoğraflandı. İmmün boyanmanın şiddeti (0, -) negatif boyanma, (1, +) fokal ve zayıf boyanma, (2, ++) yaygın ve normal boyanma ve (3, +++) yoğun ve güçlü boyanma olacak şekilde semi-kantitatif olarak skorlandı (8).

Biyokimyasal Analiz

Sıçan kan örnekleri katkı maddesi içermeyen biyokimya tüplerine yerleştirildi ve 10 dakika boyunca 3500 rpm'de santrifüj edildi. TNF-α, Serum Toplam Oksidan Durumu (TOS) ve Toplam Antioksidan Durumu (TAS) ölçümleri Rel Assay Diagnostics TOS ve TAS ölçüm kitleri (Mega Tıp San ve Tic Ltd Şti, Şahinbey/Gaziantep/Türkiye) kullanılarak gerçekleştirildi. Absorbans okumaları ELISA okuyucusu kullanılarak alındı.

İstatistiksel Analiz

Kalp dokusunda görülen histopatolojik sonuçlar gruplar arasında karşılaştırıldı. Dağılımların normalliğini belirlemek için Shapiro-Wilk W testi ve Kruskal-Wallis H testi kullanıldı. Normal dağılım gösteren değişkenler için Tukey testi, normal dağılım göstermeyen değişkenler için Mann Whitney-U testi kullanıldı. Tüm veriler SPSS v. 24 (SPSS Inc., Chicago, IL, ABD) istatistik programı kullanılarak analiz edildi ve $p < 0.05$ istatistiksel olarak anlamlı kabul edildi.

BULGULAR

Histopatolojik Analiz Sonuçları

Hematoksilen-Eozin (HE) ile boyanmış kontrol, Sham ve VIT gruplarında kalp dokusunun normal histolojisi görülmektedir (a, b, h). Doksorubisin (DXR) grubunda, kas liflerinin dejenerasyonu (yeşil ok) (c), kas lifleri arasında tek veya grup halinde vakuol benzeri yapılar (siyah ok) (d), damarlarda konjesyon (kırmızı ok) (e, f) dikkat çeken bulgular olmuştur. DXR+VIT grubunda normale yakın kalp histolojisi görülmektedir (g) (Resim 1, Şekil 1).

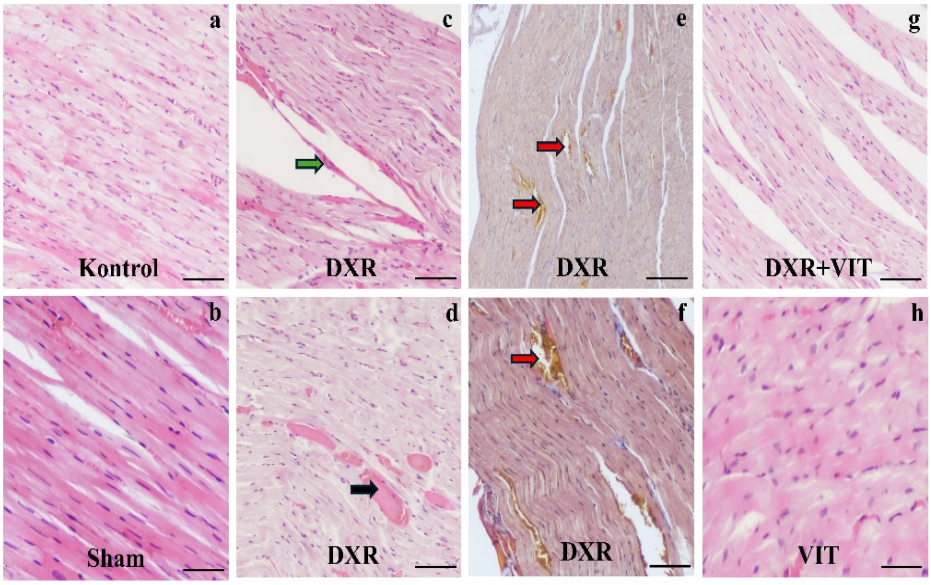

Resim 1. Boyanma sonrası Kontrol, Sham, DXR, DXR+VIT, VIT gruplarında kalp dokusunun histopatolojik sonuçları. a, c, e, f, g ölçek çubuğu = 100 µm, x 200. b, d, h ölçek çubuğu = 50 µm, x 400. Hematoksilen-Eozin (HE): a, b, c, d, g, h. Martius Scarlet Blue (MSB): e, f.

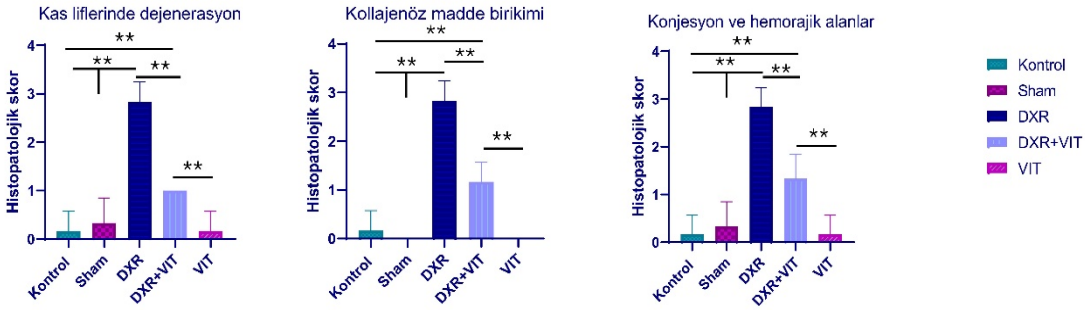

Şekil 1. Kalp dokusunda gruplar arasındaki histopatolojik bulguların skor sonuçları. **p<0.001. DXR: Doksorubisin, VIT: *Vitis vinifera* L.

İmmunohistokimyasal Analiz Sonuçları

İmmunohistokimyasal inceleme sonrasında kontrol (A, B, C), Sham (D, E, F), VIT (M, N, O) gruplarında Kaspaz-3, NF-κB-p65, TNF-α immunreaktivitesi görülmemiştir. DXR grubunda ise Kaspaz-3, NF-κB-p65, TNF-α yoğun boyanma (+++) dikkat çekmektedir (G, H, I). Tedavi grubu olan DXR+VIT grubunda ise, DXR grubuna göre karşılaştırıldığında daha az boyanma (++, +) görülmüştür (J, K, L) (Resim 2, Şekil 2).

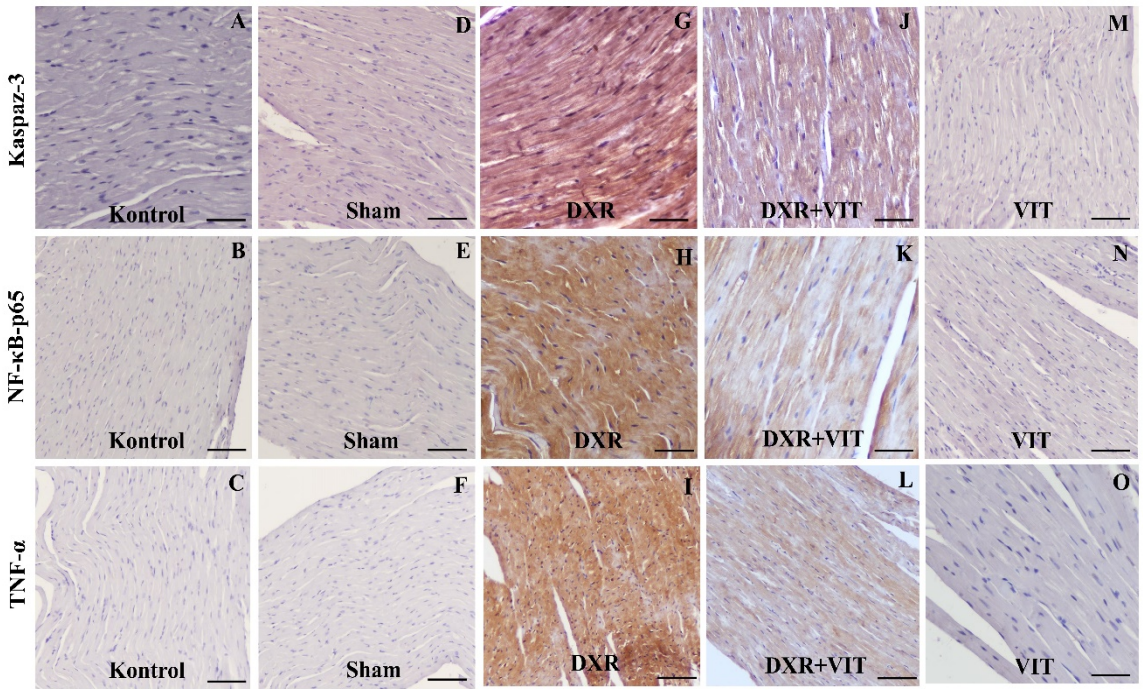

Resim 2. Kontrol, Sham, DXR, DXR+VIT, VIT gruplarında kalp dokusunun Kaspaz-3, p65 Nükleer Faktör-kappa B (NF-κB-p65), Tümör Nekroz Faktörü- alfa (TNF-α) immunreaktivitesi. A, B, C, D, E, F, M, N, O ölçek çubuğu = 100 µm, x 200. G, H, I, J, K, L ölçek çubuğu = 50 µm, x 400.

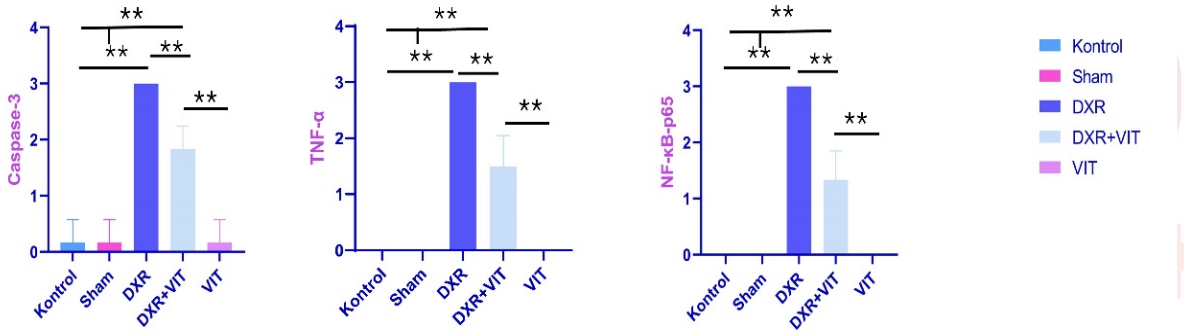

Şekil 2. Kontrol, Sham, DXR, DXR+VIT, VIT gruplarında Kaspaz-3, TNF-α, NF-κB-p65 skor sonuçları. **p<0.001. DXR: Doksorubisin, VIT: *Vitis vinifera* L.

Biyokimyasal Analiz Sonuçları

Serumda Tümör Nekroz Faktörü α (TNF-α), Toplam Oksidan Durum (TOS) ve Toplam Antioksidan Durum (TAS) serum düzeyleri incelendi ve değerlendirildi. Kontrol grubu ile DXR grubu arasında TNF-α düzeyleri karşılaştırıldığında anlamlı bir fark gözlendi (p <0,001). Ayrıca, DXR ile kontrol, sham ve DXR + VIT arasında anlamlı bir fark bulundu (p <0,001). TOS düzeyleri DXR grubunda daha yüksekti, ancak DXR+VIT grubunda anlamlı şekilde azaldı (p <0,001). TAS düzeyleri VIT grubunda en yüksekti (p <0,001). Ayrıca, DXR+VIT grubu TAS düzeylerinde DXR grubuna kıyasla anlamlı bir artış gösterdi (p <0,001) (Şekil 3).

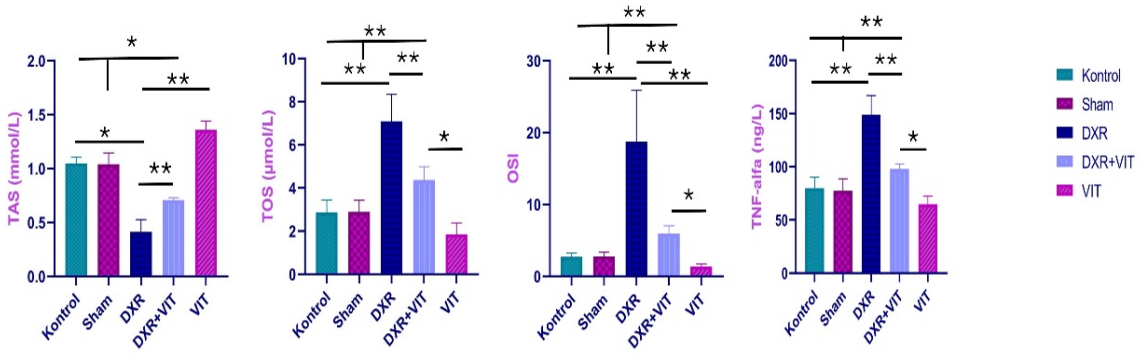

Şekil 3. Kontrol, Sham, DXR, DXR+VIT, VIT gruplarında serumda TAS, TOS, OSI ve Tümör Nekroz Faktörü α (TNF- α) düzeyleri. *p<0.05, **p<0.001. DXR: Doksorubisin, VIT: *Vitis vinifera* L.

TARTIŞMA

Antrasiklin ilaçlarından biri olan doksorubisin (DXR), kanser tedavisinde yaygın olarak kullanılmaktadır (9). Bununla birlikte, antrasiklin kaynaklı kardiyotoksisite genel morbidite ve mortalite nedeniyle klinik uygulamasını büyük ölçüde sınırlamıştır (10).

Çalışmamızda DXR'nin kas liflerinin dejenerasyonuna neden olduğu görülmüştür. Yanı sıra kas lifleri arasında vakuol benzeri yapılar görülmüştür. Yapılan bir çalışmada DXR tedavisinin doza bağlı toksik kardiyomiyopatiye neden olduğu Taramalı Elektron Mikroskobu ile gösterilmiştir. Hasarlı mitokondri ve miyofibriler düzensizlik fotoğraflanmıştır (11). Araştırma bulgularımız yapılan çalışmalarla uyumludur. Yetişkin kalp dokusundaki kardiyomiyositler rejenerasyon yeteneğini kaybettiğinden, kardiyomiyosit kaybı DXR kaynaklı kalp yetmezliğine neden olabilmektedir (12).

Birçok bitkide bulunan ve üzerinde en çok çalışılan sekonder metabolitler arasında yer alan fenolik bileşiklerdir. *Vitis vinifera* çekirdeğinin, antioksidan ve anti-inflamatuar özelliklere sahip proantosiyanidinler ve flavonoidlerin varlığı nedeniyle birçok çalışmada kullanılmıştır (13). Özellikle *Vitis vinifera*'da bulunan flavonoidler (kuersetin, mirisetin, kateşin ve epikateşin) antiinflamatuar, antimikrobiyal, nöroprotektan ve hepatoprotektan özelliklere sahiptir(14). *Vitis vinifera'*da bulunan resveratrolün, ülseratif kolit patogenezinde önemli bir rolü olan TNF-α, IL-6, IL-8 ve COX-2 gibi inflamatuar sitokinleri azalttığı ve antiinflamatuar etkiye sahip olduğu bildirilmiştir (15). Sıçanlarda DXR kaynaklı miyokardiyal hasar üzerinde Ghrelin'in etkisinin araştırıldığı bir çalışmada, DXR'nin oksidatif hasarı ve inflamasyonu arttırdığı gösterilmiştir (16). Kelidonik asitin DXR kaynaklı kardiyak toksisite üzerindeki etkisinin değerlendirildiği çalışmada, dört hafta boyunca Kelidonik asit uygulanan sıçanlarda kreatin kinaz-miyokardiyal bant (CK-MB), laktat dehidrogenaz (LDH), aspartat aminotransferaz (AST) ve kardiyak troponin-T gibi kardiyak belirteçlerin seviyesinin düştüğü, miyokardiyal hasarın azaldığı ve kardiyak disfonksiyonun iyileştiği gösterilmiştir (17). Tsarouchi ve ark.'nın Parkinson hastalığı üzerinde yaptıkları araştırmada *Vitis vinifera'nın* olası nöroprotektif etkisi olduğu gösterilmiştir (18). Yaptığımız çalışmada da VIT'in, DXR kaynaklı kalp hasarını azalttığı görülmüştür. Özellikle DXR+VIT grubunda da görülmüştür ki VIT içerdiği fenolik bileşikler ve flavonoidlerden dolayı, DXR'nin olası etkilerini azaltmıştır. *Vitis vinifera* çekirdeklerinin anti-inflamatuar ve antioksidan etkisi, IL6, TNFα ve NF-κB gibi inflamatuar medyatörlerde azalmaya bağlı olarak farklı çalışmalarda kanıtlanmıştır (19). Çalışmamızda da immunohistokimyasal olarak incelediğimiz Kaspaz-3, NF-κB-p65 ve TNF-α immunreaktiviteleri DXR grubunda artmıştır. Bu sonuç DXR'nin apoptotik süreci hızlandırdığı ve inflamatuar sitokinleri arttırdığını doğrulamıştır. Tedavi

grubu olan DXR+VIT grubunda ise, VIT'in antiapoptotik ve antiinflamatuar etkisini göstererek kardiyoprotektif özellikte olduğu görülmüştür.

Vitis vinifera antosiyanidinlerinden biri olan malvidin, artritli sıçanlarda insan makrofajından kaynaklanan inflamasyonu inhibe etmiştir (20). Flavonoidler, resveratrol ve antosiyanidinler gibi fenolik bileşikler, kolit remisyonu üzerinde yararlı etkilere sahip olabilecek siyah üzüm çekirdeği özütlerinin en olası bileşenleridir (21). Fermente edilmiş asma yaprağı özlerinin (*Vitis vinifera* L.), özellikle katı ortamda yapılan fermantasyonlarda, biyoaktif bileşiklerini ve antioksidan aktivitesini artırdığı gösterilmiştir. Ek olarak, fermente edilmiş asma yapraklarıyla yapılan yoğurtlar, laktik asit bakterilerinin çoğalmasını engellemeden mikrobiyal büyümeyi engelleme potansiyeline sahiptir (22). Araştırmamızın biyokimyasal sonuçları da daha önce yapılan çalışmaları doğrulamıştır. TAS seviyesi VIT grubunda yüksektir. İçerdiği fenolik bileşiklerden kaynaklı olarak DXR kaynaklı inflamasyonu azaltmıştır.

Sonuç olarak, *Vitis vinifera* L., DXR kaynaklı kalp hasarına karşı koruyucu bir etki göstermiştir. DXR kaynaklı kalp hasarında *Vitis vinifera* L.'nin etkisnin gösterildiği bir çalışmaya rastlanmamıştır. Bu nedenle araştırmamız özgün olmasının yanı sıra daha sonra yapılacak çalışmalar için ortaya koyduğu histokimyasal, immunohistokimyasal ve biyokimyasal sonuçlarla yardımcı olacaktır.

KAYNAKÇA

1. Palvia A, Damera A, Nandi A, Magar S, Patidar S, Kasarla S, vd. Cardio-Oncology's modern approaches to prevent doxorubicin-induced cardiotoxicity: A systematic review. Cureus. 2024;16(8):e66215.
2. Kalyanaraman B. Teaching the basics of the mechanism of doxorubicin-induced cardiotoxicity: have we been barking up the wrong tree? Redox Biol. 2020;29:101394.
3. Rawat PS, Jaiswal A, Khurana A. Doxorubicin-induced cardiotoxicity: an update on the molecular mechanism and novel therapeutic strategies for effective management. Biomed Pharmacother. 2021;139:111708.
4. Wu B, Leung K, Poon E. Mitochondrial-targeted therapy for doxorubicin-induced cardiotoxicity. Int J Mol Sci. 2022;23:1912.
5. Yamanaka S, Tatsumi T, Shiraishi J, Mano A, Keira N, Matoba S, vd. Amlodipine inhibits doxorubicin-induced apoptosis in neonatal rat cardiac myocytes. J Am Coll Cardiol. 2003;41:870–878.
6. Tesoriere L, Ciaccio M, Valenza M, Bongiorno A, Maresi E, Albiero R, vd. Effect of vitamin A administration on resistance of rat heart against doxorubicin-induced cardiotoxicity and lethality. J Pharmacol Exp Ther. 1994;269:430.
7. Niknami E, Sajjadi S, Talebi A, Minaiyan M. Protective effect of vitis vinifera (black grape) seed extract and oil on acetic acid-induced colitis in rats. Int J Prev Med. 2020;11:102.
8. Sarman E. Effect of Cucumis Melo Var. agrestis Naudin on doxorubicin-induced cardiotoxicity in rats. Cukurova Med J. 2024;49(2):353–62.
9. Seara F, Kasai-Brunswick T, Nascimento J, Campos-de-Carvalho A. Anthracycline-induced cardiotoxicity and cell senescence: new therapeutic option? Cell Mol Life Sci. 2022;79(11):568.
10. Ibanez B, Moreno-Arciniegas A. The quest for an early marker of anthracycline-induced cardiotoxicity. JACC Basic Transl Sci. 2022;7(1):11–3.

11. Borlak J, Ciribilli Y, Bisio A, Selvaraj S, Inga A, Oh J, vd. The Abl1 tyrosine kinase is a key player in doxorubicin-induced cardiomyopathy and its p53/p73 cell death mediated signaling differs in atrial and ventricular cardiomyocytes. J Transl Med. 2024;22(1):845.

12. Liao H, Ding W, Zhang N, Zhou Z, Ling Z, Li W, vd. Activation of AMPKα2 attenuated doxorubicin-induced cardiotoxicity via inhibiting lipid peroxidation associated ferroptosis. Free Radic Biol Med. 2023;205:275–90.

13. Hemmati A, Foroozan M, Houshmand G, Moosavi Z, Bahadoram M, Maram N. The topical effect of grape seed extract 2% cream on surgery wound healing. Glob J Heal Sci. 2014;7:52–8.

14. Nassiri-Asl M, Hosseinzadeh H. Review of the pharmacological effects of Vitis Vinifera (Grape) and its bioactive constituents: An update. Phythoter Res. 2016;30:1392–403.

15. Bereswill S, Muñoz M, Fischer A, Plickert R, Haag L, Otto B. Anti-inflammatory effects of resveratrol, curcumin and simvastatin in acute small intestinal inflammation. PLoS One. 2010;3(5):e15099.

16. Peng Y, Zhang P, Zou P, Zhou Y, Shao L. The protective effect of Ghrelin peptide on doxorubicin hydrochloride induced heart failure in rats. J Cardiothorac Surg. 19(1):508.

17. Khairnar S, Kulkarni Y, Singh K. Cardioprotective effect of chelidonic acid against doxorubicin-induced cardiac toxicity in rats. Rev Port Cardiol. 2024;S0870(24):264–6.

18. Tsarouchi M, Fanarioti E, Karathanos V, Dermon C. Protective effects of currants (Vitis vinifera) on corticolimbic serotoninergic alterations and anxiety-like comorbidity in a rat model of parkinson's disease. Int J Mol Sci. 2022;24(1):462.

19. Ismail A, Salem A, Eassawy M. Hepatoprotective effect of grape seed oil against carbon tetrachloride induced oxidative stress in liver of gamma-irradiated rat. J Photochem Photobiol. 2016;160:1–10.

20. Decendit A, Mamani-Matsuda, M Aumont V, Waffo-Teguo P, Moynet D, Boniface K. Malvidin-3-O-beta glucoside, major grape anthocyanin, inhibits human macrophage-derived inflammatory mediators and decreases clinical scores in arthritic rats. Biochem Pharmacol. 2013;86:1461–7.

21. Kőrösi L, Molnár S, Teszlák P, Dörnyei Á, Maul E, Töpfer R, vd. Comparative study on grape berry anthocyanins of various teinturier varieties. Foods. 2022;11:3668.

22. Freitas L, Sousa-Dias M, Paula V, Dias L, Estevinho L. Fermented grapevine leaves: Potential preserving agent in yogurt. Foods. 2024;13(13):2053.

EVALUATION OF MICROSATELLITE INSTABILITY (MLH-1, PMS-2) IN GRANULOSA CELLS OF PATIENTS UNDERGOING IN VITRO FERTILIZATION TREATMENT

FİLİZ YİLMAZ, ASSİSTANT PROFESSOR, M.D [1,2]

1 Hitit University Erol Olcok Research and Training Hospital, IVF Center, Corum, Turkey, drfilizyilmaz@gmail.com

2 Hitit University, Faculty of Medicine, Department of Histology and Embryology, Corum, Turkey, drfilizyilmaz@gmail.com

ABSTRACT

Objective: The objective of this study was to immunohistochemically evaluate the expression of MLH-1 and PMS-2 in granulosa cells of infertile patients undergoing IVF treatment for microsatellite instability indicating DNA repair damage.
Material and Method: This prospective study was conducted using granulosa cell samples obtained from patients undergoing egg retrieval during ICSI/ET cycles at Hitit University IVF Centre. 50 patients were divided into five groups according to aetiology: male factor (n = 10), decreased ovarian reserve (n = 10), polycystic ovary syndrome (n = 10), tubal factor (n = 10), and unexplained infertility (n = 10). The MLH-1 and PMS-2 immunostaining procedures had been completed. A correlation analysis was conducted to examine the relationship between MLH-1 and PMS-2 expression levels.
Results: The statistical analysis revealed that age, AMH, FSH, AFC, number of collected oocytes, number of pronuclei, MLH-1, and PMS-2 expression level were statistically significant ($p < 0.05$). The lowest MLH-1 and PMS-2 immune scores were observed in the group with poor ovarian reserve. Pearson correlation analysis demonstrated a positive correlation between MLH-1, PMS-2 levels and AMH, AFC, the number of oocytes collected.
Conclusion: The reduced expression of MLH-1 and PMS-2 observed in the group with diminished ovarian reserve may be attributable to microsatellite instability. Furthermore, a correlation was identified between MLH-1 and PMS-2 levels, and ovarian reserve indicator tests through correlation analysis. In conclusion, our findings indicate that microsatellite instability in granulosa cells may contribute to the development of decreased ovarian reserve.

Keywords: Granulosa cell; infertility; MLH-1; PMS-2.

INTRODUCTION

Infertility is a complex condition that affects approximately 15% of women during their reproductive years. Infertility is defined as the inability to conceive despite regular sexual intercourse without the use of contraceptive methods within 12 months (1). Approximately 25% of infertility cases are attributed to the male partner, 30% to the female partner, 30% to both partners and in 15% of cases, pregnancy cannot be achieved even in the absence of a diagnosed pathology in either partner. Recently, a number of options have been recommended to couples experiencing infertility, a problem that is increasing in prevalence in our country on a daily basis, depending on the specific type of infertility. The most commonly utilized of these options is the assisted reproductive technique known as "in vitro fertilization (IVF)."
Granulosa cells represent the somatic cells of the ovarian follicle. As oocytes mature and develop within the follicle, they engage in a highly interactive process with the granulosa cells. The bidirectional interaction between the oocyte, follicular fluid, and granulosa cells

surrounding the ovarian follicle is essential for the development of the oocyte and is believed to be linked to fertilization and embryo development (2).
Microsatellites are highly polymorphic, comprising 1-6 base-pair DNA repeats that are abundant in the eukaryote genome. It is important to note that DNA replication is not an exact process. A number of errors can occur during the base pairing stage of replication, depending on a number of factors, including the type of organism, age, the activity of the DNA polymerase in that organism, and local environmental factors. These errors occur with greater frequency in microsatellite regions, which makes it challenging for DNA polymerase to encode with precision and has a high probability of sequence drift. In the absence of repair mechanisms, these errors will accumulate with each replication cycle, leading to alterations in the length of the gene locus containing microsatellites (3-5).
The best-known function of the mismatch repair system (MMR), one of the DNA repair mechanisms, is to maintain genomic stability by correcting single base mismatches and insertions/deletions during replication. The human MMR gene products are the MMR proteins MSH, MLH, and PMS. These genes are involved in ensuring correct DNA synthesis throughout replication, thereby stabilizing the genome. Microsatellite Instability (MSI) is observed in the absence of efficient MMR gene activity (3-5).
Mutations in MMR can lead to microsatellite instability and cause Lynch Syndrome and sporadic tumors of the uterus, ovary, cervix, breast, stomach, urinary tract, and skin. Animal models and studies with patients with spermatogenic disorders suggest that MMR genes may play a role in male infertility (6-9). However, microsatellite instability in the pathogenesis of female infertility has not been investigated by MMR.
The definition of the pathogenesis of any disease is a guide both in the development of a treatment method and in the development of a diagnostic method. Therefore, we evaluated the expression of microsatellite instability genes MLH-1 PMS-2 in granulosa cells of patients undergoing IVF treatment for different reasons by immunohistochemical analysis.

MATERIALS AND METHODS

This prospective randomized study was performed with granulosa cells obtained from patients who underwent OPU during the ICSI/ET cycle at Hitit University Erol Olçok Training and Research Hospital IVF Center in 2023. The study was started after the approval of the University Ethics Committee (2023-63). Written and verbal informed consent was obtained from all patients participating in the study before the procedure.

Fifty patients with primary or secondary infertility, aged 22-44 years, who underwent ICSI/ET for different reasons of infertility were included in the study. Patients were divided into five groups according to etiology: male factor (n:10), decreased ovarian reserve (n:10), polycystic ovary syndrome (n:10), tubal factor (n:10), and unexplained infertility (n:10). **Group 1: Male factor infertility:** patients whose spermiogram results could not be classified as normozoospermic based on WHO criteria. **Group 2: Decreased ovarian reserve (DOR) group:** Based on the Bologna Criteria, at least two of three characteristics must be present: a) Advanced female age (≥ 40) or a risk factor for FFS), b) A previous FFS (≤ 3 oocytes with conventional stimulation protocol), c) Any abnormal ovarian reserve test (e.g., AFC < 5-7 or AMH < 0.5-1.1 ng/ml). **Group 3: PCOS Group:** Patients diagnosed with PCOS based on ESHRE Rotterdam 2003 criteria with two of three criteria: a. Oligo-anovulation, b. Clinical and/or biochemical signs of hyperandrogenism, c. Polycystic ovaries on ultrasonography. **Group 4: Tubal factor group:** Patients were included in this group if there was no other cause of infertility in the examinations and tests performed in the infertility clinic, but the

cause of infertility was due to tuba uterina. **Group 5: Unexplained Infertility:** Female patients in whom no anomaly was detected in infertility tests and male partners whose spermiogram results were normozoospermic based on WHO criteria were included in the unexplained infertility group. **Exclusion criteria:** Patients with a Body Mass Index (BMI) >30 kg/m^2, metabolic endocrine disorders such as hypothyroidism/hyperthyroidism, a history of previous ovarian surgery, and baseline FSH level >15 mIU/ml were excluded. Demographic and clinical characteristics of all patients were recorded (age, basal hormone levels, FSH, LH, E2, AMH), basal antral follicle count, number of oocytes collected, number of PNs.)

In the study, follitropin alfa (recombinant FSH) or human menopausal gonadotropin (Menopur) was started for controlled ovarian stimulation from the second day of menstruation at a dose of 150-300 units/day/SC, taking into account the patient's age, antral follicle count and body mass index. Cetrorelix 0.25 mg/day/SC (Cetrotide) was started from the sixth day of menstruation in patients who were to receive GnRH antagonist protocol. Follicular growth was regularly monitored with ultrasound measurements during induction. When at least three follicles were 18 mm or more in diameter, 250 mcg/SC choriogonadotropin alpha (recombinant hCG) was administered. After 36 hours, OPU was performed.

In the OPU procedure, follicular fluids from the patients are obtained by aspirating the follicles 15-20 mm in size and closest to the probe with 16 G needles at a vacuum pressure of 125 mmHg. The patient's egg collection process is completed using standard methods. Each aspirated follicle fluid is placed separately in 60x15 mm polystyrene teeth. The follicle fluid and the sandulus oocyte complex are extracted.

The cumulus-oocyte complex can be mechanically removed to shorten the denudation process. The separated cumulus cells and follicular fluid are disposed of as medical waste. We use the cells of the cumulus that will be discarded. The cells were removed from the periphery of the oocyte using a bent insulin syringe. The material of the cumulus cells to be used in the study will not affect the treatment of the patients. In addition, no clinical interventional procedures were performed in addition to the routine (10). The separated cumulus cells were spread on polylysine slides under a stereo-microscope. The specimens were allowed to dry at room temperature for 30 minutes. After drying, the cells were fixed with formalin. All collected specimens were stored at +4°C in a dry place without light for simultaneous examination (11).

Immunohistochemistry

Granulosa cell smear preparations were analyzed in Hitit University. Immunohistochemically, MLH-1 (CLONE: ES05, Novocastra, 1/100 dilution, catalog number: MLH1-L-CE-S) and PMS-2 (Clone M0R4G, 1/100 dilution, catalog number: PMS2-L-CE-S) primary antibodies were used. At least five high-power fields were evaluated for each granulosa, and the staining rate of granulosa cells was calculated. The mean percentage of stained granulosa cells was determined and classified into three categories as follows: negative, < 1%; 1st group, 1-50%; 2nd group, 51-100% positive cells (12). Photographs of the preparations were taken with an Olympus BX 15 Microscope in the research laboratory of Hitit University Faculty of Medicine.

Statistical Analysis

The IBM SPSS 25.0 package program (IBM Corp., Armonk, NY, USA) was used for analysis. The Kolmogorov-Smirnov test was used to assess the adherence to normal distribution. Differences between groups were determined by the Student t-test for normally distributed variables and the Mann-Whitney U test for non-normally distributed variables. In the study, the comparison of MLH-1 PMS-2 levels with age, AMH, LH, FSH, E2, AFC, oocyte number, and PN number was evaluated by Pearson correlation analysis. The statistical significance level was accepted as $p<0.05$.

RESULTS

A total of 50 patients, including ten females in each group, participated in the study. The clinical and biochemical characteristics of the patients are shown in Table 1. All the data are given as mean + standard deviation. Firstly, when we compared the data of the five groups, a statistical difference was observed between AMH, FSH, number of antral follicles (AFC), and number of oocytes retrieved ($p< 0.05$). There was no statistical difference between groups for age, LH, E2, and PN count. In DOR group comparisons, low AMH, low AFC, and low oocyte count in DOR group showed statistical significance compared to the other groups. In PCOS group, high AFC and high oocyte count showed statistical significance.

The data obtained demonstrated statistical significance in the DOR and PCOS groups, which are characteristic findings of patients with poor ovarian reserve and PCOS. This demonstrates that the groups in our study were successfully designed.

Data on MLH-1 and PMS-2 immunostaining scores are shown in figure 1-2. When the five groups in the study were compared, MLH-1 and PMS-2 immunostaining scores showed statistical significance ($p<0.05$). In DOR group, MLH-1 and PMS-2 immunostaining positivity was not observed. Except for DOR Group, no statistical difference was observed between the other groups. This shows us that there is a loss of MLH-1 and PMS-2 expression in the decreased ovarian reserve group.
Table-2 shows us the results of correlation analysis. AMH has negatively correlation with FSH. AMH has positively correlation with AFC, collected oocyte number, PN number, MLH-1 and PMS-2. MLH-1and PMS-2 have positively correlation with AMH, AFC and collected oocyte number.

DISCUSSION

Infertility may result from a variety of factors, including genetic, epigenetic, endocrine, or environmental changes. A number of studies with infertile patients or animal models have indicated that genes involved in DNA repair mechanisms and epigenetic factors may play a role in the etiology of infertility. The objective of this study was to investigate the expression of the MLH-1 and PMS-2 genes, which are among those involved in MMD (one of the DNA repair mechanisms), in granulosa cells of female patients undergoing IVF treatment.
The study revealed statistically significant differences between the groups with regard to age, AMH, FSH, AFC, the number of oocytes collected, and the number of PNs. No statistically significant differences were observed between the groups with regard to LH, E2, and embryo counts. The definition of poor ovarian reserve already includes advanced age, low AMH, high

FSH, and low AFC. Accordingly, the statistical disparity between the groups demonstrates the efficacy of our group design.

Karahan and et. showed that loss of MLH-2 and MLH-6 expressions was correlated with the right colon localisation, poor and mucinous differentiation. They arouse suspicion colorectal cancer develop through microsatellite instability(12). The absence of MLH-1 and PMS-2 immunostaining in the DOR group showed us that these markers may play a role in the pathogenesis of decreased ovarian reserve. In addition, the positive correlation between MLH-1, PMS-2 and AMH, AFC, and collected oocytes number, which we observed in the correlation analysis results, also supports our findings.

It was reported that male mice deficient in PMS-2, a key protein for DNA mismatch repair, had reduced spermatozoa and reduced fertility (13). Another study reported MSI within testicular cancer complimented with reduced MLH-1 and MLH-2 expression (14). Varyant MLH-1 females had fewer follicles, thus, suggesting chromosomal crossover events during meiosis were reduced (15). Previous work suggests mice that do not have a MLH1 functional gene, have MSI and show increases in morbidity, lenfoma development and different gastrointestinal related tumors(16). So, we showed that MLH-1 and PMS-2 were absent in DOR group. We commented that MSI reduced ovarian reserve and caused infertility.

Limitations: We need larger group designs (with more patients) to be able to defend our results more strongly. We could not include the levels of MLH-1 and PMS-2 in the tissue and blood in the study. In our next study, we will add tests that measure the genetic and molecular expression level, such as ELISA or PCR.

CONCLUSION

The reduced expression of MLH-1 and PMS-2 observed in the group with diminished ovarian reserve may be attributable to microsatellite instability. Furthermore, a correlation was identified between MLH-1 and PMS-2 levels, and ovarian reserve indicator tests through correlation analysis. In conclusion, our findings indicate that microsatellite instability in granulosa cells may contribute to the development of decreased ovarian reserve. The data obtained thus far suggest that further research into the pathogenesis of infertility may yield new insights and, consequently, new diagnostic or therapeutic methods for molecules associated with microsatellite instability.

TABLES AND FIGURES

Table-1: The clinical and biochemical characteristics of the patients. All the data are given as mean +/- standard deviation.

		Age	AMH	LH	FSH	E2	AFC	OOCYST	PN
MALE FACTOR	Mean	28,5000	3,6850	5,7700	5,9500	38,6600	14,5000	8,3000	4,3000
	N	10	10	10	10	10	10	10	10
	Std. Deviation	3,77859	1,58635	1,89388	1,27911	11,74518	1,71594	2,54078	2,90784
DOR	Mean	34,4000 *	,7010 *	7,5700	9,1700 *	36,4600	5,5000 *	4,1000 *	1,6000 *
	N	10	10	10	10	10	10	10	10
	Std. Deviation	6,32807	,30307	6,36380	5,70030	18,03547	1,50923	2,46982	1,64655
PCOS	Mean	31,0000	4,2880	8,3310	6,5000	42,2100	26,1000 *	12,7000*	5,4000
	N	10	10	10	10	10	10	10	10
	Std. Deviation	3,74166	2,52546	2,93739	1,57621	10,80858	3,69534	4,59589	3,83551
TUBAL FACTOR	Mean	30,6000	3,7640	5,4300	5,2100	63,2200	13,6000	8,8000	3,7000
	N	10	10	10	10	10	10	10	10
	Std. Deviation	4,71876	2,45285	1,62279	1,53872	44,98854	2,41293	4,58984	2,40601
UNEXPLAİNED	Mean	30,7000	4,7350	4,7940	5,3000	38,1600	14,8000	8,5000	4,9000
	N	10	10	10	10	10	10	10	10
	Std. Deviation	2,86938	2,07753	3,05989	2,63565	22,45149	3,52136	4,90465	4,25441

Table-2: The results of correlation analysis.

		AGE	AMH	LH	FSH	E2	AFC	OOCYTE	PN	MLH-1	PMS-2
AGE	Pearson Correlation	1	-,220	,282*	,143	-,096	-,176	-,348*	-,338*	-,335*	-,335*
	Sig. (2-tailed)		,124	,047	,320	,506	,222	,013	,016	,017	,017
	N	50	50	50	50	50	50	50	50	50	50
AMH	Pearson Correlation	-,220	1	,023	-,386**	,295*	,534**	,453**	,341*	,473**	,473**
	Sig. (2-tailed)	,124		,876	,006	,038	,000	,001	,015	,001	,001
	N	50	50	50	50	50	50	50	50	50	50
LH	Pearson Correlation	,282*	,023	1	,358*	,212	,118	,132	,085	-,248	-,248
	Sig. (2-tailed)	,047	,876		,011	,140	,413	,360	,558	,082	,082
	N	50	50	50	50	50	50	50	50	50	50
FSH	Pearson Correlation	,143	-,386**	,358*	1	-,114	-,256	-,216	-,148	-,344*	-,344*
	Sig. (2-tailed)	,320	,006	,011		,429	,072	,132	,305	,014	,014
	N	50	50	50	50	50	50	50	50	50	50
E2	Pearson Correlation	-,096	,295*	,212	-,114	1	,105	,155	,042	,172	,172
	Sig. (2-tailed)	,506	,038	,140	,429		,467	,283	,771	,232	,232
	N	50	50	50	50	50	50	50	50	50	50
AFC	Pearson Correlation	-,176	,534**	,118	-,256	,105	1	,613**	,385**	,488**	,488**
	Sig. (2-tailed)	,222	,000	,413	,072	,467		,000	,006	,000	,000
	N	50	50	50	50	50	50	50	50	50	50
COLLECTED OOCYTES	Pearson Correlation	-,348*	,453**	,132	-,216	,155	,613**	1	,727**	,407**	,407**
	Sig. (2-tailed)	,013	,001	,360	,132	,283	,000		,000	,003	,003
	N	50	50	50	50	50	50	50	50	50	50
PN	Pearson Correlation	-,338*	,341*	,085	-,148	,042	,385**	,727**	1	,292*	,292*
	Sig. (2-tailed)	,016	,015	,558	,305	,771	,006	,000		,040	,040
	N	50	50	50	50	50	50	50	50	50	50
MLH-1	Pearson Correlation	-,335*	,473**	-,248	-,344*	,172	,488**	,407**	,292*	1	1,000**
	Sig. (2-tailed)	,017	,001	,082	,014	,232	,000	,003	,040		,000
	N	50	50	50	50	50	50	50	50	50	50
PMS-2	Pearson Correlation	-,335*	,473**	-,248	-,344*	,172	,488**	,407**	,292*	1,000**	1
	Sig. (2-tailed)	,017	,001	,082	,014	,232	,000	,003	,040	,000	
	N	50	50	50	50	50	50	50	50	50	50

Figure-1: The photos of MLH-1 immunohistochemical stain in five groups.

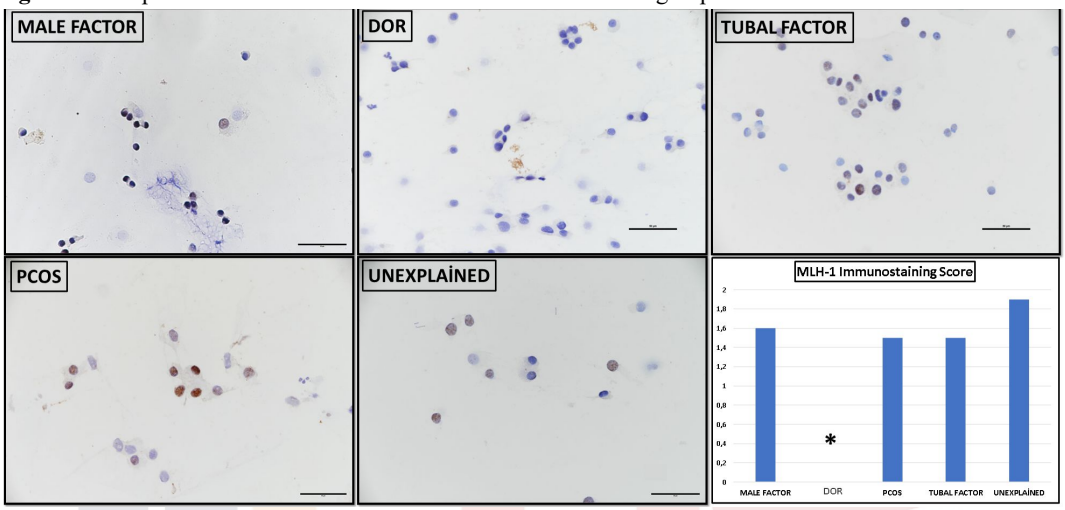

Figure-2: The photos of PMS-2 immunohistochemical stain in five groups.

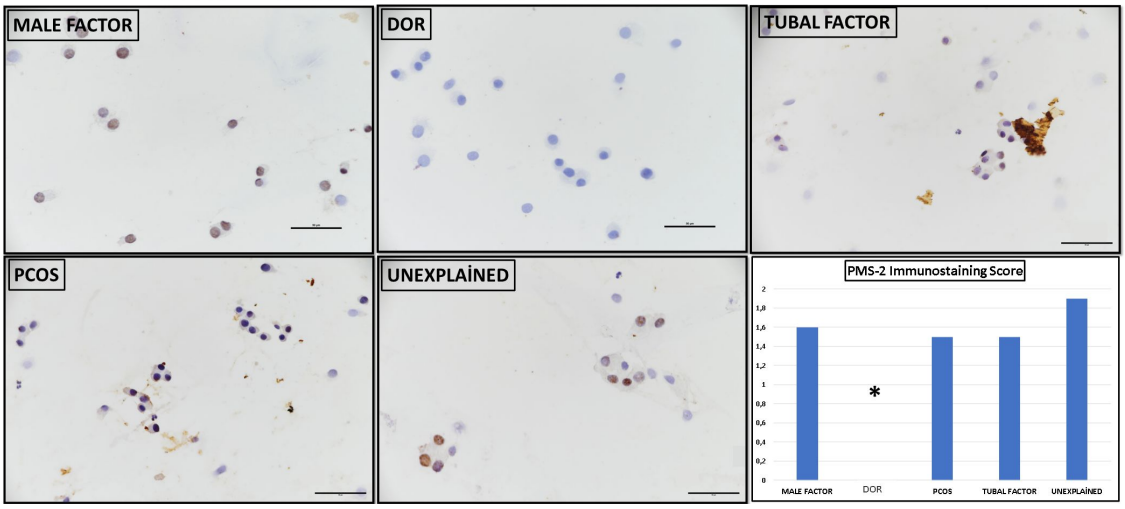

References

1. Zhang, Y., McLain, A. C., Davis, B., & McDermott, S. (2019). Fecundity and Infertility Among Women with Disabilities in the United States. *Journal of women's health (2002)*, *28*(7), 934–940.

2. Kim, Y. J., Ku, S. Y., Kim, Y. Y., Liu, H. C., Chi, S. W., Kim, S. H., Choi, Y. M., Kim, J. G., & Moon, S. Y. (2013). MicroRNAs transfected into granulosa cells may regulate oocyte meiotic competence during in vitro maturation of mouse follicles. *Human reproduction (Oxford, England)*, *28*(11), 3050–3061.

3. Richard, G. F., Kerrest, A., & Dujon, B. (2008). Comparative genomics and molecular dynamics of DNA repeats in eukaryotes. *Microbiology and molecular biology reviews : MMBR*, *72*(4), 686–727.

4. Koreth, J., O'Leary, J. J., & O'D McGee, J. (1996). Microsatellites and PCR genomic analysis. *The Journal of pathology*, *178*(3), 239–248.

5. Hirst, G. L., & Illand, M. (2001). Automated fluorescent detection of microsatellite instability. *Molecular biotechnology*, *17*(3), 239–247.

6. Wieland, J., Buchan, S., Sen Gupta, S., & Mantzouratou, A. (2022). Genomic instability and the link to infertility: A focus on microsatellites and genomic instability syndromes. *European journal of obstetrics, gynecology, and reproductive biology*, *274*, 229–237.

7. Manhart, C. M., & Alani, E. (2016). Roles for mismatch repair family proteins in promoting meiotic crossing over. *DNA repair*, *38*, 84–93.

8. Paul, C., Povey, J. E., Lawrence, N. J., Selfridge, J., Melton, D. W., & Saunders, P. T. (2007). Deletion of genes implicated in protecting the integrity of male germ cells has differential effects on the incidence of DNA breaks and germ cell loss. *PloS one*, *2*(10), e989.

9. Shrestha, K. S., Tuominen, M. M., & Kauppi, L. (2021). Mlh1 heterozygosity and promoter methylation associates with microsatellite instability in mouse sperm. *Mutagenesis*, *36*(3), 237–244.

10. Lin, X., Dai, Y., Tong, X., Xu, W., Huang, Q., Jin, X., Li, C., Zhou, F., Zhou, H., Lin, X., Huang, D., & Zhang, S. (2020). Excessive oxidative stress in cumulus granulosa cells induced cell senescence contributes to endometriosis-associated infertility. *Redox biology*, *30*, 101431.

11. Lin, D., Ran, J., Zhu, S., Quan, S., Ye, B., Yu, A., Kang, Y., & Lin, Y. (2017). Effect of GOLPH3 on cumulus granulosa cell apoptosis and ICSI pregnancy outcomes. *Scientific reports*, *7*(1), 7863.

12. Karahan, B., Argon, A., Yıldırım, M., & Vardar, E. (2015). Relationship between MLH-1, MSH-2, PMS-2,MSH-6 expression and clinicopathological features in colorectal cancer. *International journal of clinical and experimental pathology*, *8*(4), 4044–4053.

13. Velasco, A., Corvalan, A., Wistuba, I. I., Riquelme, E., Chuaqui, R., Majerson, A., & Leach, F. S. (2008). Mismatch repair expression in testicular cancer predicts recurrence and survival. *International journal of cancer*, *122*(8), 1774–1777.

14. Baker, S. M., Bronner, C. E., Zhang, L., Plug, A. W., Robatzek, M., Warren, G., Elliott, E. A., Yu, J., Ashley, T., Arnheim, N., Flavell, R. A., & Liskay, R. M. (1995). Male mice defective in the DNA mismatch repair gene PMS2 exhibit abnormal chromosome synapsis in meiosis. *Cell*, *82*(2), 309–319.

15. Singh, P., Fragoza, R., Blengini, C. S., Tran, T. N., Pannafino, G., Al-Sweel, N., Schimenti, K. J., Schindler, K., Alani, E. A., Yu, H., & Schimenti, J. C. (2021). Human MLH1/3 variants causing aneuploidy, pregnancy loss, and premature reproductive aging. *Nature communications*, *12*(1), 5005.

16. Edelmann, W., Yang, K., Kuraguchi, M., Heyer, J., Lia, M., Kneitz, B., Fan, K., Brown, A. M., Lipkin, M., & Kucherlapati, R. (1999). Tumorigenesis in Mlh1 and Mlh1/Apc1638N mutant mice. *Cancer research*, *59*(6), 1301–1307.

PREEKLAMPSININ GÖBEK KORDONU MEZENKIMAL STROMA HÜCRELERININ VEGFR-2 İFADESI ÜZERINE ETKISI

İBRAHİM ALPTEKİN [1],BİLGE SERDAROĞLU [1], EZEL ERKAN[1], DERYA UYAN HENDEM[3], FERDA TOPAL ÇELİKKAN [1], DİLEK ŞAHİN[2], ALP CAN [1]

1 Ankara Üniversitesi Tıp Fakültesi, Histoloji ve Embriyoloji Anabilim Dalı, Üreme Biyolojisi ve Kök Hücre Laboratuvarı, Sıhhiye, Ankara, Türkiye, ibrahimalptekin4221@gmail.com, bilgeserdaroglu7@gmail.com, ezelerkan@gmail.com, ferdatopal@gmail.com, alpcan2007@gmail.com

2Ankara Şehir Hastanesi, Kadın Hastalıkları ve Doğum Anabilim Dalı, Perinatoloji Bilim Dalı, Çankaya, Ankara,Türkiye, dilekuygur@gmail.com

3 Şanlıurfa Eğitim ve Araştırma Hastanesi, Kadın Hastalıkları ve Doğum Anabilim Dalı, Perinatoloji Bilim Dalı, Yenice, Şanlıurfa, drderyauyan@gmail.com

ÖZET

Giriş: Embriyon dışı mezoderm erken dönemde kan damarlarının oluştuğu bölgedir, bölge vaskülogenezde etkili VEGR-2 (Flk1+) hücreleri içerir, göbek kordonunun gelişiminde etkindir. Göbek kordonu stroması; subamniyotik stroma (SA); intervasküler stroma (IVC), perivasküler stroma (PVC) içerir. Her bölgede multipotent stroma hücreleri bulunur (iGK-MSH). Bu hücreler üzerinde yapılan çalışmalar, hücrelerin bölgesel farklılıklara (proliferasyon, farklanma, immün düzenleme) sahip olduğunu göstermektedir ve bu farkın anjiyogenez potansiyeline de yansıması olasıdır. Preeklampsi gebeliğin 24. haftasından sonra oluşan, plasenta odaklı bir gelişme anomalisidir, koryon villuslarındaki "kusurlu anjiyogenez" sonucunda ortaya çıktığı kabul edilir. Bu nedenle iGK-MSH'ın farklanma potansiyelini etkileyebilir. Bu konuda yapılmış çalışmalar endotel hücreleri ve damara ilişkin yapılarla kısıtlıdır. Bugüne kadar bu sürecin nicel karşılaştırmasını yapan bir çalışma literatürde bulunmamaktadır.

Amaç: Çalışmamızda erken ve geç dönem preeklampsi olgularının göbek kordonu stromasının farklı bölgelerinde (SA, IVC, PVC) VEGFR-2 dağılımı ve yoğunluğunun nicel karşılaştırmasını yapmayı amaçladık.

Gereç-Yöntem: Paraformaldehitle (%3,5) fikse edilen üç ayrı gruptan 11´er göbek kordonunun 10µm'lik kriyokesitleri VEGFR-2 antikoruyla işaretlendi, 5.75µm kalınlığında görüntülendi, üç boyutlu olarak kaydedildi. Yapılan integrasyon analizleriyle elde edilen sinyal yoğunlukları SPSS 23.0 programında analiz edildi. P<0,05 anlamlı kabul edildi.
Bulgular: Tüm gruplarda SA; IVC(p=0,003, p=0,031, p=0,000) ve PVC'ye (p=0,008, 0,02, p=0,001 göre daha düşük sinyal yoğunluğu gösterdi. Gruplar arası fark istatistiksel açıdan anlamlı bulundu. SA, IVC ve PVC gruplarına ait sinyal yoğunluğu ortalamalarında olgu türüne bağlı olarak (her alan ayrı ayrı olgu türüne bağlı karşılaştırıldı) meydana gelen farklar istatistiksel olarak anlamlı bulunmadı (p=0,431; 0,355; 0,395).

Sonuç: Göbek kordonu stroması VEGFR-2 pozitiftir. Stromanın farklı bölgeleri VEGFR-2 ifadesi bakımından farklıdır. Preeklampsinin başlangıç süresi sinyal yoğunluğunu etkilememektedir.
Anahtar kelimeler: Preeklampsi, Anjiyogenez, VEGFR-2, Göbek Kordonu, Embriyon Dışı Mezoderm

1. GİRİŞ

Embriyon dışı mezoderm, gebeliğin erken döneminde embriyon ile plasenta arasında bağlantı sağlayan mezenkimal bağ dokusudur ve bağlantı sapı olarak bilinen yapıya kaynaklık eder. Bu yapı daha sonra göbek kordonuna dönüşür (1-3). Aynı zamanda embriyon döneminde koryon villuslarının oluşumunda ve devamlılığının sağlanmasında görevlidir. Tüm bunlara ek olarak vaskülogenezde (de novo damar gelişimi) Flk-1 pozitif hemanjiyoblastların bulunduğu ve salgıladığı moleküllerle uyarıcı etkisi bulunur (4).
Göbek kordonu fetüs ile anneyi birbirine bağlayan yaşamsal bir yapıdır. Sıradışı bir epitel (UCE) ile çevrili; 2 arter, 1 ven ve bu damarların çevresinde embriyon dışı mezodermden köken alan özel bir stromaya sahiptir (5, 6). Yapılan çalışmalarda göbek kordonu stromasında yer alan, subamniyotik stroma (SA), intervasküler stroma (IVC) ve perivasküler stroma (PVC) olmak üzere birbirinden farklı özelliklere sahip 3 farklı anatomik bölge tanımlanmıştır. Bu bölgelerde özel orijinli mezenkimal stroma hücreleri bulunur (5) ve bu bu hücrelerin anjiyogenik potansiyeli gösterilmiştir (7). Tüm bu nedenlerle bu hücreler endotel farklanma potansiyeli gösteriyor olabilirler ve anjiyogenetik potansiyel taşıyan hücrelerin göbek kordonundaki dağılımı bölgesel çeşitlilik taşıyor olabilir.
İn-utero dönemde vaskülogenez sürecinde etkin olan molekül VEGF'dir. Vaskülogenez süreci embriyon dışı mezodermde yüzeylerinde VEGFR-2 (Flk-1) içeren hücrelerin uyarılması ile gerçekleşir (8, 9). Dolayısıyla bu molekül hücrelerin endotel farklanma potansiyelini göstermek için oldukça gerekli bir işaretleyicidir.
Preeklampsi gebelikte 20. Haftadan sonra meydana gelen yüksek sistolik ve diastolik kan basıncı ve proteinüri ile karakterize ciddi bir sendromdur (10). Hastalığın patogenezine yönelik yapılan çalışmalarda anjiyogenez dengesinin bozulmasının önemli bir yeri bulunmaktadır, erken dönemde plasenta ve eklerini özellikle koryon villuslarını etkilemektedir (11). Hastalık başlangıç süresine göre erken ve geç preeklampsi (EPE ve GPE) olarak sınıflandırılır. Erken dönemde daha belirgin şiddetli semptomlar olması erken ve geç dönem sınıflandırmasını da patofizyolojik açıdan önemli bir noktaya taşımaktadır (12). Hem anjiyogenezi bozması hem de koryon villuslarını etkileyen bir entite olması, göbek kordonu stromasının da etkilenebileceğini düşündürmektedir.
Çalışmamızda, göbek kordonu stromasında bulunan hücrelerin endotel farklanma potansiyelinin varlığını ve stromanın farklı bölgelerinde bu potansiyelin farklılık içerip içermediğini, erken ve geç dönem preeklampsinin bu farklanma potansiyeli üzerindeki etkisini VEGFR-2 ifade düzeyleri üzerinden karşılaştırarak literatüre katkı yapmayı hedefledik.

2. GEREÇ VE YÖNTEM

2.1. Grupların belirlenmesi, Olguların Temini ve Doku Takibi

Ankara Bilkent Şehir Hastanesi Kadın Hastalıkları ve Doğum Anabilim Dalı'ndan 33 örnek (Etik kurul no: İ04-226-22, aydınlatılmış onamları alınarak) temin edildi. Örnekler 3 ayrı gruba ayrıldı. 1.grup/kontrol: Herhangi bir sağlık sorunu olmayan gebelerden sezaryen ile doğan sağlıklı yenidoğanlardan alınan göbek kordonları, 2. Grup/EPE: (Erken Başlangıçlı Preeklampsi): 24-34 hafta arası doğmuş olan yenidoğanlardan alınan göbek kordonları, 3. Grup/GPE (Geç Başlangıçlı Preeklampsi): >34. Hafta sonrası doğan yenidoğanlardan alınan göbek kordonları. Alınan örnekler; nekrotik, ödemli, pıhtı içeren alanlar temizlenerek laminar akışlı kabin altında 1 cm^3'lük parçalara bölündü. %3,5 paraformaldehit (PFA) içerisine atıldı ve 72 saat süreyle takip edildi. Fikse olan dokular sükroz içerisinde bekletilerek çökmeleri sağlandı. Dokular, kriyomatriks (Epredia, 12542716, İngiltere) ile bloklanaraklar oluşturuldu. Bloklardan 10 µm´lik kesitler alınarak immunfloresan boyama işlemleri için -20ºC'ye kaldırıldı.

2.2.İmmunofloresan Boyama

Her grup için seçilen örnekler grup halinde (1 kontrol, 1 EPE, 1 GPE) boyandı, boyama işlemi öncesinde +4°C´de 1 saat süreyle bloklama işlemi uygulandı. 1 saat sonunda primer antikor (VEGFR-2-ThermoFisher Scientific, PA5-16487, İngiltere) 1/50 seyreltme oranı ile uygulandı. Kontrol grubuna fosfat tamponlu salin (PBS, Thermo Scientific Oxoid®, BR0014G, İngiltere) eklendi. İlk antikor uygulaması sonrası 16 saat +4°C´de nemli ortamda bekletildi. Süre sonunda 3 kez fosfat tamponlu salin PBS ile yıkandıktan sonra, sekonder antikor ugulaması yapıldı (FITC-conjugated anti-rabbit Goat, Abcam Ab6717, İngiltere). 2 saat 37°C´de karanlıkta bekletildi. Süre sonunda PBS ile tekrar yıkandı. İşlem sonunda 15-20 µl Hoechst içeren kapatma mediumu (Molecular Probes, 33258, İngiltere) kullanılarak lamel ile kapatıldı ve +4°C´ye kaldırıldı.

2.3.Örneklerin Görüntülenmesi ve Değerlendirilmesi

VEGFR-2 antikoru ile boyanmış olan 3 farklı gruba ait 11 farklı olgu (Toplam 33 adet), konfokal süper çözünürlük mikroskobunda (Zeiss,LSM 880, lazer gücü: 0,3%;488 nm, 6 %; 405 nm pinhole: 34 µm,32 µm; master gain: 650,800) standart ve sabit ayarlar kullanıldı. Göbek kordonuna ait 3 farklı alandan (SA, IVC, PVC) toplamda 5,75 µm kalınlıkta 15 ardışık görüntü alındı. Alınan görüntüler maksimum image projection (MIP) olarak kaydedildi. Kaydedilen görüntülerden 2048*2048 $piksel^2$'lik alanlar seçildi. Her bir olgu Zen Black görüntüleme programında değerlendirilerek ölçümler gerçekleştirildi. Toplam 33 adet olgu (11 kontrol, 11 EPE, 11 GPE) ayrı ayrı ölçülerek mean intensity ve total integrasyon değerleri elde edildi. Hesaplanan değerler Excel 2016 programına kaydedildi ve SPSS V22.0´da istatistiksel analiz için değerlendirildi. Her bir bölge için ayrı ayrı ölçüm değerlerinde gruplar arası farklarının anlaşılması için One Way Anova testi gerçekleştirildi. Aynı grup içerisinde bölge içi farkların anlaşılması için repeated measures of Anova testleri gerçekleştirildi. Farklı çıkan ölçümlerde gruplar arası farkı gösterebilmek için Tukey ve Benferroni posthoc testleri uygulandı. Her bir ölçüm için p değeri <0,05 istatistiksel olarak anlamlı kabul edildi.



Şekil 1: Doku takibi, immünfloresan boyama, görüntüleme, analiz işlemleri; A) Olguların temini ve taşınması, B) Olguların parçalanması ve takip süreci C) Olgulardan kriyobloklama ve kriyokesitleme işlemleri D) Olguların immunfloresan olarak boyanması E) Olguların konfokal süperçözünürlük mikroskobunda görüntülenmesi E) Olguların Zenn Black/Pro uygulamasında analizi

3. BULGULAR

Göbek kordonundan alınan örneklerde alınan sinyal yoğunluğu değerlerigrafik 1'de verilmiştir. SA değerleri; IVC (p=0,003, p=0,031, p=0,000) ve PVC (p=0,008, 0,02, p=0,001) gruplarından anlamlı şekilde düşük bulundu (Şekil 1). Yapılan ölçümlerde IVC ve PVC arasında sinyal yoğunluğu açısından oluşan farklılık istatistiksel olarak anlamlı bulunmadı (p=0,293; p=0,189; p=0,106) . SA, IVC ve PVC gruplarına ait sinyal yoğunluğu ortalamalarında olgu türüne bağlı olarak (kontrol, EPE, GPE) meydana gelen farklar istatistiksel olarak anlamlı bulunmadı. (p=0,431; 0,355; 0,395). Şekil 2 gruplarda yapılan görüntüleri bölgeleri ve bölgere ait grafikleri birlikte göstermektedir.

Tablo 1: Olgu türü ve bölgelerde ölçülen sinyal yoğunlukları

OLGULAR	SA	IVC	PVC
Kontrol	13,74±1,11*	16,67±1,71	18,00±2,04
EPE	13,63±1,66*	15,75±,07	17,30±2,12
GPE	16,01±1,36*	19,86±2,33	21,78±3,06

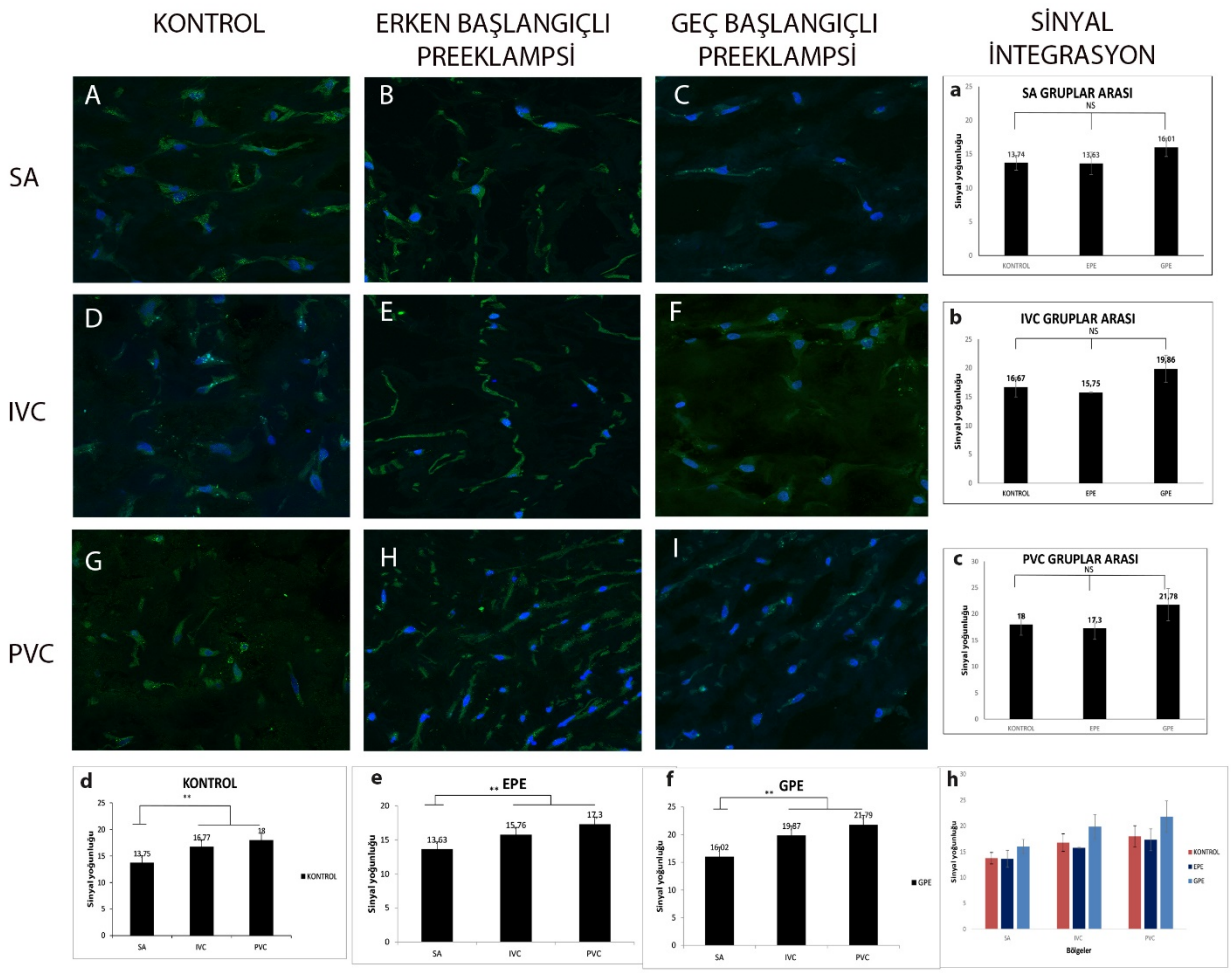

Şekil 2: Sinyal Yoğunluğu Ve Ölçümleri Toplu (A,E,G) kontrol olgularında yapılan VEGFR-2 immunfloresan boyamaları; (B,E,H) erken başlangıçlı preeklampsi olgularında yapılan yapılan VEGFR-2 immunfloresan boyamaları; (C,F,I) geç başlangıçlı preeklampsi olgularında yapılan VEGFR-2 immunfloresan boyamaları; (a) SA gruplar arası sinyal yoğunluğunu gösteren grafik, (b) IVC gruplar arası sinyal yoğunluğunu gösteren grafik, (c) PVC gruplar arası sinyal yoğunluğunu gösteren grafik, (d) Kontrol olgulara bölgeler arası sinyal yoğunluğunu gösteren grafik, (e) Erken başlangıçlı preeklampsi bölgeler arası sinyal yoğunluğunu gösteren grafik (f) Geç başlangıçlı preeklampsi bölgeler arası sinyal yoğunluğunu gösteren grafik.

4. TARTIŞMA

Yapılan ölçümlerde göbek kordonu stromasında VEGFR-2 pozitif bulunmuştur. Bu bulgu, bu bölgelerdeki hücrelerin endotel farklanma potansiyelinin halen devam ediyor olabileceğini gösteriyor olabilir. Ölçümlerde ayrı ayrı değerlendirilen SA, IVC ve PVC bölgelerinde ölçülen sinyal yoğunluklarında da farklılık izlenmiştir. SA oldukça zayıf sinyaller alınması ek olarak PVC bölgesindeki sinyal yoğunluğunun yüksek olması hem hücrelerin kordonun tüm stroma bölgelerinde yerleşim gösterdiğini hem de endotel farklanma potansiyeli açısından hücrelerin anatomik farklılık içerdiğini bize gösterdi, fakat IVC ve PVC arasında farklılık istatistiksel açıdan farklı değildi. Farkın çıkmaması bu iki bölgenin hücre yoğunluğu açısından benzer olabiliceğini düşündürmektedir. Öte yandan yine de PVC de ölçülen sinyalin daha yüksek olması bize PVC ile IVC arasındaki farkı karşılaştırmak için kullanılan yöntemi güçlendirebilecek ek olarak farklı bir metodoloji kullanımını işaret etmektedir. Kontrol ve GPE olguları benzer sinyal yoğunluğu gösterdi. EPE olgularında, sinyal yoğunluğu zayıf

izlendi. Fakat oluşan fark istatistiksel olarak anlamlılık göstermedi, bu durum hücrelerin farklanma aktivitelerinde dönemsellikten kaynaklanıyor olabilir ve vaskülogenez sürecindeki dönemsellik bunu etkilemiş olabilir. Hücrelerin farklanma potansiyelleri zayıflamış olabilir. Ölçüm yapılan olguların sayısını veya farklı bölgelerden alınan 3 boyutlu görüntü sayısını artırmak farklı sonuçlar verebilir. Ek olarak bu değerlendirme literatürde VEGFR-2 ifadesinin immunofloresan boyamayla nicel olarak değerlendirildiği bir yöntemdir; bu açıdan immunohistokimyasal tekniklere üstünlük sağlamaktadır.

5. SONUÇ

VEGFR-2 göbek kordonu stromasındaki hücrelerde ifade edilmektedir. Hücrelerin endotel farklanma potansiyelleri farklılık içermektedir. Preeklampsinin başlangıç zamanı hücrelerin endotel farklanma potansiyelleri üzerinde etkili değildir. Preeklampsi göbek kordonu stromasını etkileyen bir kliniktir.

6. TEŞEKKÜR

Bu çalışma Ankara Üniversitesi BAP tarafından TTU-2022-2303 ve TSG-2545 numaralı projelerle ve TÜBİTAK 121S821 numaralı proje ile desteklenmiştir.

KAYNAKÇA

1. Moore KL, Persaud TVN, Torchia MG. The developing human : clinically oriented embryology. Eleventh edition ed. Edinburgh: Elsevier Edinburgh; 2020.
2. Sadler TW, Sadler-Redmond SL, Tosney K, Byrne J, Imseis H. Langman's Medical Embryology. Fourteenth edition ed. Philadelphia: Wolters Kluwer Philadelphia; 2019.
3. Pham TXA, Panda A, Kagawa H, To SK, Ertekin C, Georgolopoulos G, et al. Modeling human extraembryonic mesoderm cells using naive pluripotent stem cells. Cell Stem Cell. 2022;29(9):1346-65.e10.
4. Farkas K, Ferretti E. Derivation of Human Extraembryonic Mesoderm-like Cells from Primitive Endoderm. Int J Mol Sci. 2023;24(14).
5. Karahuseyinoglu S, Cinar O, Kilic E, Kara F, Akay GG, Demiralp DO, et al. Biology of stem cells in human umbilical cord stroma: in situ and in vitro surveys. Stem Cells. 2007;25(2):319-31.
6. Ovalle WK NP. Netter FH. Netter's essential histology with correlated histopathology. 3th ed. Amsterdam: Elsevier; 2020.
7. Divband S, Tasharrofi N, Abroun S, Soufi Zomorrod M. Human Umbilical Cord Mesenchymal Stem Cells-Derived Small Extracellular Vesicles Can Be Considered as Cell-Free Therapeutics for Angiogenesis Promotion. Cell J. 2022;24(11):689-96.
8. Guo X, Yi H, Li TC, Wang Y, Wang H, Chen X. Role of Vascular Endothelial Growth Factor (VEGF) in Human Embryo Implantation: Clinical Implications. Biomolecules. 2021;11(2).
9. Pietro L, Daher S, Rudge MVC, Calderon IMP, Damasceno DC, Sinzato YK, et al. Vascular endothelial growth factor (VEGF) and VEGF-receptor expression in placenta of hyperglycemic pregnant women. Placenta. 2010;31(9):770-80.
10. Bisson C, Dautel S, Patel E, Suresh S, Dauer P, Rana S. Preeclampsia pathophysiology and adverse outcomes during pregnancy and postpartum. Front Med (Lausanne). 2023;10:1144170.

11. Burton GJ, Redman CW, Roberts JM, Moffett A. Pre-eclampsia: pathophysiology and clinical implications. BMJ. 2019;366:l2381.

12. Wojtowicz A, Zembala-Szczerba M, Babczyk D, Kolodziejczyk-Pietruszka M, Lewaczynska O, Huras H. Early- and Late-Onset Preeclampsia: A Comprehensive Cohort Study of Laboratory and Clinical Findings according to the New ISHHP Criteria. Int J Hypertens. 2019;2019:4108271.

İNSAN GÖBEK KORDONU MULTIPOTENT STROMA HÜCRELERI KAYNAKLI EKZOZOMLARIN İN-VITRO HIPOKSIK VE NORMOKSIK KOŞULLARDA ENDOTEL HÜCRELERI ÜZERINDE ANJIYOGENEZ ETKINLIĞININ SINANMASI VE KARŞILAŞTIRILMASI

BİLGE SERDAROĞLU[1], İBRAHİM ALPTEKİN[1], EZEL ERKAN[1], MOHAMMADREZA DASTOURI[2], ŞERİFE ESRA ÇETİNKAYA[3], MESUT AKYOL[4], ALP CAN[1], FERDA TOPAL ÇELİKKAN[1]

[1]Ankara Üniversitesi Tıp Fakültesi, Histoloji ve Embriyoloji Anabilim Dalı, Üreme Biyolojisi ve Kök Hücre Laboratuvarı, Sıhhiye, Ankara, Türkiye, bilgeserdaroglu7@gmail.com ibrahimalptekin4221@gmail.com, alpcan2007@gmail.com, ezelerkan@gmail.com, ferdatopal@gmail.com

[2]Ankara Medipol Üniversitesi Tıp Fakültesi, Tıbbi Biyoloji Anabilim Dalı, Altındağ, Ankara, Türkiye, rezastemcell@gmail.com

[3]Ankara Üniversitesi Tıp Fakültesi Kadın Hastalıkları ve Doğum Anabilim Dalı, Mamak, Ankara, Türkiye, ecetinkaya@ankara.edu.tr

[4] Ankara Yıldırım Beyazıt Üniversitesi Tıp Fakültesi, Biyoistatistik ve Tıbbi Bilişim Anabilim Dalı, Etlik, Ankara, Türkiye, mesutakyol@gmail.com

ÖZET

Giriş: Multipotent stroma hücreleri (MSH), insan göbek kordonu (iGK) dahil birçok dokudan izole edilirler. MSH etkilerini hücre-hücre etkileşimlerinin yanı sıra ekzozomlar aracılığıyla parakrin olarak da gösterir. Hipoksik ön koşullandırmaya tabi tutulan MSH'den elde edilen ekzozomların anjiyogenik kapasiteyi artırma etkileri olduğuna dair çalışmalar bulunmaktadır.

Amaç: Normoksi (%21 O_2) ve hipoksi (%1 O_2) koşullarındaki iGK-MSH'den elde edilen ekzozomların 50 µg/mL ve 200 µg/mL konsantrasyonlarda insan umbilikal ven endotel hücreleri (HUVEC) üzerinde in-vitro tüp formasyonu oluşturma etkinliğini karşılaştırmayı amaçlıyoruz.

Gereç ve Yöntem: iGK-MSH normoksik ve hipoksik ortama maruz bırakılarak ekzozomları ayrıştırıldı ve karakterize edildi. HUVEC, Matrigel® kaplı ortama ekilerek 50 µg/mL ve 200 µg/mL konsantrasyonlarda ekzozom içeren endotel bazal medium (EBM) ile kültüre edildi. Negatif kontrol olarak EBM, pozitif kontrol olarak ekzozom içermeyen, büyüme faktörleri içeren EBM kullanıldı. 12. saat görüntülerinden, toplam uzunluk, düğüm sayısı ve ağ sayısı değerleri ImageJ Angiogenesis Analyzer eklentisiyle ölçüldü. Veriler SPSS 22.0 ile analiz edildi. $p<0.05$ istatistiksel olarak anlamlı kabul edildi.

Bulgular: Normokside 1.983,82 µg/mL, hipokside 945,88 µg/mL ekzozom proteini elde edildi. Ölçülen parametrelerde normoksik ve hipoksik grupların kendi içinde iki ekzozom konsantrasyonu arasında anjiyogenik kapasitesiteyi gösteren değişkenler açısından istatistiksel olarak anlamlı fark belirlenmedi. Hipoksi grubundaki 50 µg/mL konsantrasyonunun anjiyogenik kapasitesinin, normokside elde edilen 50 ve 200 µg/mL gruplarından daha düşük olduğu bulundu.

Sonuç: iGK-MSH'ın, normoksi koşullarında hipoksi koşullarına göre daha fazla miktarda ekzozom ürettiği; normoksi koşullarında elde edilen ekzozomların, hipoksi koşullarında elde edilen ekzozomlara göre tüp oluşumunu arttırdığı sonuçları ortaya çıktı. Ayrıca ekzozomların

O_2 düzeyinden bağımsız olarak 50-200 µg/mL konsantrasyonlarının anjiyogenez oluşturma etkinlikleri benzer bulundu.

Anahtar sözcükler: iGK-MSH, ekzozom, hipoksi, anjiyogenez, in-vitro tüp oluşumu

1. GİRİŞ

Multipotent stroma hücreleri (MSH) kemik, kıkırdak ve adipoz doku dahil olmak üzere pek çok farklı hücreye farklılaşma yeteneğine sahip hücrelerdir (1, 2) ve göbek kordonu, plasenta, kemik iliği, kordon kanı, yağ dokusu gibi pek çok dokudan izole edilebilirler (3, 4). İnsan göbek kordonu multipotent stroma hücreleri (iGK-MSH) etik kaygıları ortadan kaldırmasının yanı sıra bol miktarda bulunma ve non-invaziv yöntemlerle kolay elde edilme özellikleriyle çalışmalarda sıklıkla tercih edilir (5, 6). MSH anjiyogenezin gelişmesi ve doku iyileşmesini hızlandırma yetenekleri sayesinde pek çok terapötik yaklaşımda umut verici potansiyeldedir (7). MSH etkilerini sadece doğrudan hücre-hücre etkileşimleri yoluyla değil, aynı zamanda ekzozomlar aracılığıyla parakrin olarak da gösterir (8). Ekzozomlar, hücrede endositik yoldan oluşan, 30-200 nm çapında lipid çift zarla kaplı hücre dışı veziküllerdir (9). Proteinler, lipitler ve nükleik asitller de dahil çeşitli biyomolekülleri içerirler; içerikleri hücre tipi ve dış çevre koşulları tarafından düzenlenir (10, 11).

Hipoksi, hücrelere yetersiz oksijen teminini tanımlar (12), endotel ve intramural hücrelerde bir dizi molekülün sentezini etkileyerek anjiyogeneze neden olur (13-15). Güncel araştırmalar, hipoksik ön koşullandırmaya tabi tutulan MSH'den elde edilen ekzozomların anjiyogenik özellikler sergilediğini göstermiştir (16-21).

Aşağıdaki soruları cevaplamak için bir çalışma tasarladık; birincisi, iGK-MSH'den elde edilen ekzozomlar, insan göbek kordonu endotel hücre hatlarının (HUVEC) in vitro tüp oluşumunda etkili midir?; ikincisi, normoksik (%21 O_2) ve hipoksik (%1 O_2) koşullarda elde edilen ekzozomların anjiyojenik potansiyel açısından farkı var mıdır?; üçüncüsü normoksi ve hipoksi gruplarında kullanılan toplam ekzozom protein miktarı anjiyojenik potansiyeli etkiler mi? Sonuçlarımız, normoksik ekzozomların, potansiyel olarak daha yüksek bir ekzozom protein içeriğine sahip olduğunu ve in vitro tüp oluşumu üzerinde hipoksik ekzozomlardan önemli ölçüde daha etkili olduğunu göstermiştir.

2. GEREÇ VE YÖNTEM

2.1. iGK-MSH izolasyonu ve karakterizasyonu

Ankara Üniversitesi Tıp Fakültesi Kadın hastalıkları ve Doğum anabilim Dalı'nda sezaryenle doğan 5 bebeğin göbek kordonları (Etik kurul karar no: İ9-584-21) alındıktan sonra steril şartlarda işlemlerden geçirildi. Mekanik olarak 1-2 mm^3'lük parçalara ayrılarak %10 fetal sığır serumu (FBS) içeren DMEM/F-12 mediyumu içerisinde eksplant hücre kültürü yapıldı. Üçüncü pasajda (P_3) kaldırılan hücrelerin akım sitometri analiziyle, CD73, CD90 ve CD105 MSH belirteçlerini pozitif, CD34, CD11b, CD19, CD45 ve anti-HLA-DR'yi ise negatif ifade ettikleri gösterildi.

2.2. Ekzozom izolasyonu ve karakterizasyonu

Ekzozomlar ultrasantrifüj yöntemiyle izole edildi. P_{4-5}'teki iGK-MSH, 48 saat boyunca %10 ekzozom içermeyen FBS (ekzo- içermeyen FBS) içeren DMEM/F-12'de normoksi (%21 O_2) veya hipoksi (%1 O_2) koşullarında kültüre edildi. Hücre kültürü süpernatantları toplandı ve 4 °C'de sırasıyla 2.000*g* ve 10.000*g*'de 30'ar dk çevrildi; süpernatantlar toplandı ve 4°C'de iki kez 120.000*g*'de 90 dk ultrasantrifüj edildi. Elde edilen ekzozom pelletleri Dulbecco PBS'de (dPBS) resüspande edildi ve deneylere kadar %10 dimetil sülfoksit (DMSO) ile -80°C'de saklandı. Ayrı bir ekzozom pelleti de Western blot analizi için PMSF proteaz inhibitörü içeren RIPA lizis tamponunda -80°C'de saklandı.

Ekzozom sayı ve boyutunun belirlenmesi için ayarlanabilir dirençli darbe algılama sistemi (qNano®) kullanıldı. SEM için rutin takip gerçekleştirildi ve ZEISS Merlin® FE taramalı elektron mikroskobunda incelendi. Toplam protein içeriği Mikro-BCA protein analiziyle ölçüldü. Ekzozom yüzey belirteçleri CD9 ve CD63 Western blot ile tespit edidi.

2.3. İGK-MSH'nin HIF1α ile işaretlenmesi

iGK-MSH'nin hipoksi tepkisi, Hipoksiyle İndüklenebilir Faktör-1α (HIF-1α) ile immünofloresan boyama yapılarak doğrulandı. Cam lamellerde büyütülen %3,5 paraformaldehit (PFA) ile fikse edilmiş İGK-MSH, anti-HIF-1α ile inkübe edildi (1:100, 37°C'de 2 saat). Florescein-5-izotiyosiyanat konjuge keçi-anti-tavşan ikincil antikor olarak kullanıldı (1:200, 37°C'de 2 saat). Hücre çekirdekleri, Hoechst 33258 (1 µg/mL) ile işaretlendi. Sadece ikincil antikor kullanılarak boyanan grup negatif kontrol olarak kullanıldı.

2.4. HUVEC propagasyonu

HUVEC hattı S.B.Ü. Sağlık Bilimleri Enstitüsü Kök Hücre Laboratuvarı'ından temin edildi. Hücreler %10 FBS içeren DMEM/F-12 ile ekildi ve çoğaltıldı. %10 DMSO ile dondurularak deneylere kadar -196°C'de saklandı.

2.5. Deney gruplarının oluşturulması ve in-vitro tüp oluşum deneyi

Normoksik/hipoksik koşullar ve farklı ekzozom konsantrasyonları temelinde altı grup tasarlandı;

1. **EBM**: Sadece Endotel Hücresi Bazal Ortamı (EBM)
2. **EGM**: Sadece Endotel Hücresi Büyüme Ortamı (EGM)
3. **50-Ekzo$_{21}$**: Endotel Hücresi Bazal Ortamı + **%21 O_2 50 µg/mL** Ekzozom
4. **200-Ekzo$_{21}$**: Endotel Hücresi Bazal Ortamı + **%21 O_2 200 µg/mL** Ekzozom
5. **50-Ekzo$_1$**: Endotel Hücresi Bazal Ortamı + **%1 O_2 50 µg/mL** Ekzozom
6. **200-Ekzo$_1$**: Endotel Hücresi Bazal Ortamı + **%1 O_2 200 µg/mL** Ekzozom

EBM grubunda negatif kontrol oluşturmak amacıyla, yalnızca Endotel Hücresi Bazal Ortamı kullanıldı. **EGM** grubu pozitif kontrol olarak tasarlandı, endotel hücrelerinin çoğalması ve farklılaşması için gerekli büyüme faktörlerini içeren Endotel Hücresi Büyüme Ortamı kullanıldı (Endotel Hücresi Büyüme Ortamı: Endotel Hücresi Bazal Ortamı + VEGF, b-FGF, EGF, R3-IGF, Heparin, Askorbik Asit, Hidrokortizon İçeren Destekleyici Kit). Ekzo$_{21}$ ve Ekzo$_1$ gruplarında kullanılan 50 µg/mL ve 200 µg/mL ekzozomlar Endotel Hücresi Bazal Ortamı içinde çözülerek HUVEC üzerine tüp oluşturma kapasitesini sınamak amacıyla uygulandı ve bu gruplarda büyüme faktörü kullanılmadı.

Dondurulmuş HUVEC 37°C'de çözüldü ve %10 FBS içeren DMEM/F-12 ile kültüre edildi. Hücreler %60-70 yoğunluğa ulaştığında, kültür ortamı anjiyogenez deneylerinin başlamasından önce 24-36 saatlik bir süre boyunca FBS içermeyen DMEM/F12 ile değiştirildi ve hücrelere aç bırakma prosedürü uygulandı (22). 24 kuyucuklu petri kapları 100 µL Matrigel® (3 mg/mL) ile kaplandı ve oda sıcaklığında 90 dakika inkübe edildi.

Kordon örnekleriyle ilgili varyasyonları ortadan kaldırmak için, -80°C'de PBS+ %10 DMSO'da saklanan ekzozomlar bir araya getirilerek havuz yapıldı; ardından DMSO'yu uzaklaştırmak için 120.000*g*'de 90 dakika boyunca ultrasantrifüjlendi. Ekzozom pelletleri, anjiyogenez deneylerini gerçekleştirmek için EBM'de resüspande edildi. Her deney için Matrigel® kaplı kuyucuklara toplam 20.000 HUVEC/cm^2 ekildi. EGM gruplarına üreticinin

önerdiği miktarda büyüme faktörleri; deney gruplarına %21 ve %1 O_2 altında elde edilen, 50 veya 200 µg/mL ekzozomlar eklendi. Deneyler %21 O_2+%5 CO_2 ortamında gerçekleştirildi. Hoffman modülasyonlu invert mikroskop kullanılarak her kuyucuktan 12. saatte en az beş görüntü 4× objektif büyütmesinde alındı ve kaydedildi. Hücreler 18. saate kadar takip edilmesinin ardından %3,5 PFA ile 20 dakika fikse edilerek deney sonlandırıldı. Phalloidin633 ile immünofloresan işaretleme yapıldı ve Hoechst 33258 ile çekirdek boyaması yapılarak hücrelerin görselleştirilmesi sağlandı. Zeiss LSM880 Süperçözünürlük konfokal mikroskobunda görüntüler alındı.

2.6. İn-vitro tüp oluşumunun kantitatif analizi

Anjiyogenez süreci sırasında yakalanan canlı görüntülerin niceliksel analizi ImageJ Angiogenesis Analyzer eklentisi (23) kullanılarak gerçekleştirildi. Toplam uzunluk, düğüm sayısı ve ağ sayısı parametreleri ölçüldü **(Şekil 1)**.

Parametre	Tanımlama
Toplam uzunluk	Segment + ayrı yapılar + dalların uzunluklarının toplamı.
Düğüm sayısı	En az üç komşusu olan piksel
Ağ sayısı	Etrafı segmentlerle çevrili kapalı alan
Segment	İki kavşak ile bağlantılı ikili çizgi
Ayrı yapılar	Bir bağlantı noktasına ve uzantıya çok yakın, bağlanmış ikili hat



Şekil 1. İn vitro anjiyogenik parametrelerin tanımları (32) ve 200-Exo_{21} grubundan bir örnek görüntü. Analizler Image J Angiogenesis Analyzer yazılımı kullanılarak gerçekleştirildi (34). Ağlar (mavi), segmentler (sarı), dallar (yeşil), düğümler (kırmızı) ve ayrı yapılar (mavi) gösterilmektedir. Ölçek çubuğu: 100 µm.

2.7. İstatistiksel analizler

Anjiyogenez parametreleri ortalama±standart sapma (SD) olarak ifade edildi. Analizden önce normal dağılım için Shapiro-Wilk testi kullanıldı. Deney grupları arasındaki değişkenleri karşılaştırmak için normal dağılım gösteren değişkenlere tek yönlü varyans analizi (ANOVA) uygulandı. Farklı grupları belirlemek için post-hoc çiftler arası karşılaştırmalarda Bonferroni ve Scheffe yöntemleri kullanıldı. Normal dağılıma uymayan değişkenler için Kruskal-Wallis parametrik olmayan varyans analizi kullanıldı. Farklı grupları belirlemek için çiftler arası karşılaştırmalarda Bonferroni düzeltmeli Mann-Whitney post-hoc testleri kullanıldı. Değişkenleri oksijen seviyesine (normoksi-hipoksi) ve verilen ekzozom proteini miktarına (50

µg/mL-200 µg/mL) göre karşılaştırmak için normal dağılım koşulunu karşılayan değişkenler için Student'ın T-testi, normal dağılım göstermeyen değişkenler için ise Mann-Whitney testi kullanıldı. Veri analizi için SPSS 22.0 kullanıldı. $p<0,05$ değeri istatistiksel olarak anlamlı bir farkın göstergesi olarak kabul edildi.

3. BULGULAR

3.1. iGK-MSH izolasyonu ve karakterizasyonu

Eksplantlardan iğ şeklindeki iGK-MSH'ın ortaya çıkışı ve çoğalması 8-10. günlerde mikroskop altında gözlendi. Hücreler ortalama 21. günde P_0'dan P_1'e geçti **(Şekil 2A ve 2B)**. Hücreler P3'e ulaştığında kaldırıldı ve %95'ten fazla seviyede pozitif (CD73, CD90 ve CD105) ve negatif MSH belirteçleri (anti-CD34, anti-CD11b, anti-CD19, anti-CD45 ve anti-HLA-DR antikorları) ifade ettikleri gösterildi **(Şekil 2C)**.

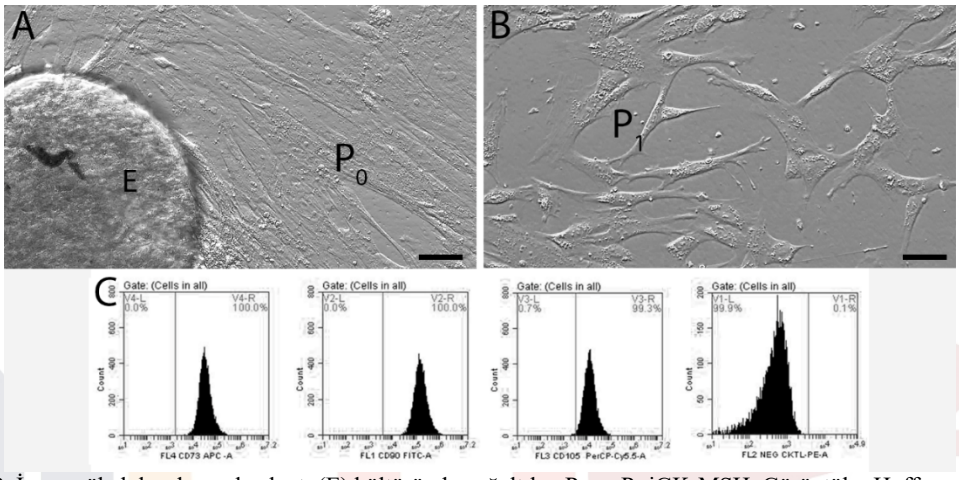

Şekil 2. A., B. İnsan göbek kordonu eksplantı (E) kültüründe çoğaltılan P_0 ve P_1 iGK-MSH. Görüntüler Hoffman modülasyon kontrast mikroskobunda elde edildi. Ölçek çubuğu: 50 µm. **C.** P_3 iGK-MSH akım sitometride MSH yüzey belirteçleri CD73, CD90, CD105'i yüksek oranda (>%95) ve CD34, CD45'i negatif olarak (<%1) ifade etti.

3.2. İGK-MSH'da HIF1α ifadesinin gösterilmesi

Hipoksi gruplarında HIF1α'nın çekirdekte noktasal paternde yerleştiği gözlemlendi. Normoksi ve negatif kontrol (yalnızca seconder antikor kullanılan) gruplarında boyanma gözlenmedi **(Şekil 3)**.

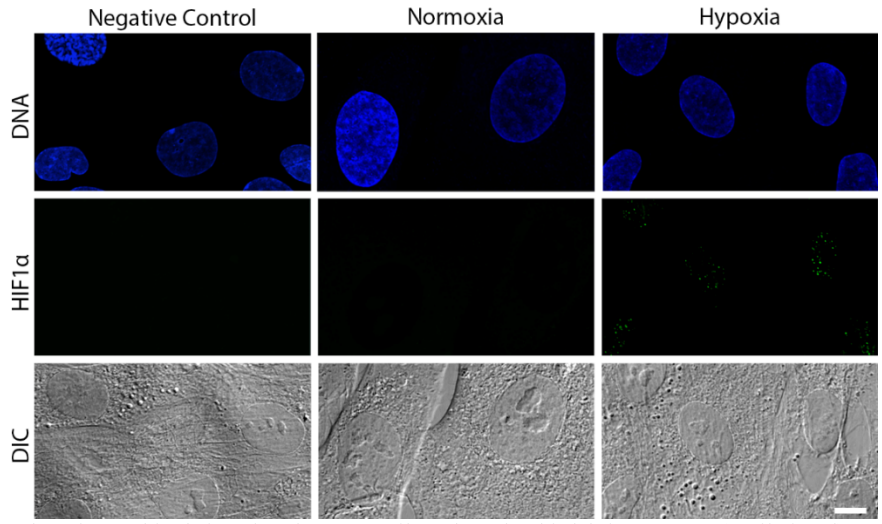

Şekil 3. iGK-MSH'da yalnızca hipoksi grubunda HIF-1α ile noktasal çekirdek boyanması (yeşil sinyal) gözlendi, normoksi ve negatif kontrol gruplarında ise boyanma gözlenmedi. Ölçek çubuğu: 10 µm.

3.3. Ekzozom Karakterizasyonu

P_3 iGK-MSH kültür ortamından ortalama $20{,}4\times10^6$ hücreden elde edilen ekzozomların ortalama sayısı $6{,}28\times10^9$ ve ortalama boyutları 158,6 nm olarak bulundu. Bu sonuçlar, literatürde bildirilen boyut aralığıyla tutarlıdır **(Şekil 4A, B)**. Ekzozom zarında ifade edilen CD9 ve CD63 sırasıyla 53 ve 25 kDa bantlar olarak gözlendi **(Şekil 4C)**. Ekzozomlar SEM'de yuvarlak bir morfolojide gözlendi **(Şekil 4D)** ve yer yer agregatlar oluşturuyordu **(Şekil 4E)**.

A

Örnek No	Toplam Hücre Sayısı	Elde edilen toplam ekzozom sayısı	Ekzozom boyutu (nm)
1	$21{,}6\times10^6$	$14{,}12\times10^9$	179
2	$26{,}0\times10^6$	$3{,}48\times10^9$	122
3	$13{,}9\times10^6$	$1{,}24\times10^9$	175
Ortalama	$20{,}5\times10^6$	$6{,}28\times10^9$	159

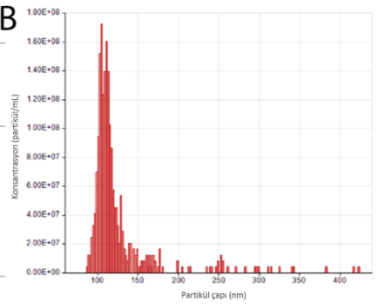



Şekil 4. A. P_3 kültürlerinden toplanan ekzozomların sayısı ve boyutu. **B.** qNano® ile ölçülen ekzozom konsantrasyonu ve partikül çapı grafiği. **C.** Western blot ile ekzozomların CD63 ve CD9 protein ifadesi. **D., E.** Ekzozom morfolojisinin SEM ile görüntülenmesi. Ok uçları 210-350 nm arasında ölçülen ekzozom agregatlarını göstermektedir. Ölçek çubukları: 200 nm.

Mikro-BCA sonuçlarına göre, normoksik ortamda toplam 112,22×10^6 hücreden 1983,82 µg/mL ekzozom proteini izole edildi ve hipoksik ortamda toplam 93,3×10^6 hücreden 945,88 µg/mL ekzozom proteini elde edildi.

3.4. İn-vitro tüp oluşumu

$Ekzo_{21}$ grupları en uzun ortalama toplam uzunlukları sergilerken, 50-$Ekzo_1$ grubu en kısa ortalama toplam uzunluğu gösterdi. EBM grubu, 50-$Ekzo_{21}$ ve 200-$Ekzo_{21}$ gruplarından daha kısa toplam uzunluklar sergiledi (sırasıyla p=0,037, p=0,043). Her iki 50-200 $Ekzo_{21}$ grubu da ortalama toplam uzunlukta 50-$Ekzo_1$ grubundan fazla olsa da (her ikisi de p=0,001), $Ekzo_{21}$ grupları (50'ye karşı 200) arasında istatistiksel olarak anlamlı fark bulunmadı (p>0,05) **(Şekil 5A)**.

En yüksek düğüm sayısı $Ekzo_{21}$ grubunda gözlenirken, en düşük sayı 50-$Ekzo_1$ grubunda kaydedildi (her ikisi için de p=0,001). Düğüm sayısının EBM ve $Ekzo_1$ gruplarında $Ekzo_{21}$ gruplarına kıyasla önemli ölçüde daha düşük olduğu bulundu (p<0,05). EBM ile 50-$Ekzo_{21}$ (p=0,038) arasında önemli bir fark ve EBM ile 200-$Ekzo_{21}$ (p=0,050) arasında sınırda önemli bir fark vardı. $Ekzo_{21}$ (50'ye karşı 200) (p=1,000) ve $Ekzo_1$ (50'ye karşı 200) (p=0,153) grupları arasında istatistiksel olarak önemli bir fark gözlenmedi **(Şekil 5B)**.

En yüksek ağ sayısı $Ekzo_{21}$ grubunda, en düşük ise 50-$Ekzo_1$ grubunda gözlendi. 50-$Ekzo_1$ grubunda 50-$Ekzo_{21}$ (p=0.002) ve 200-$Ekzo_{21}$ (p=0.001) gruplarından çok daha az ağ sayısına ulaşıldığı belirlendi **(Şekil 5C)**.

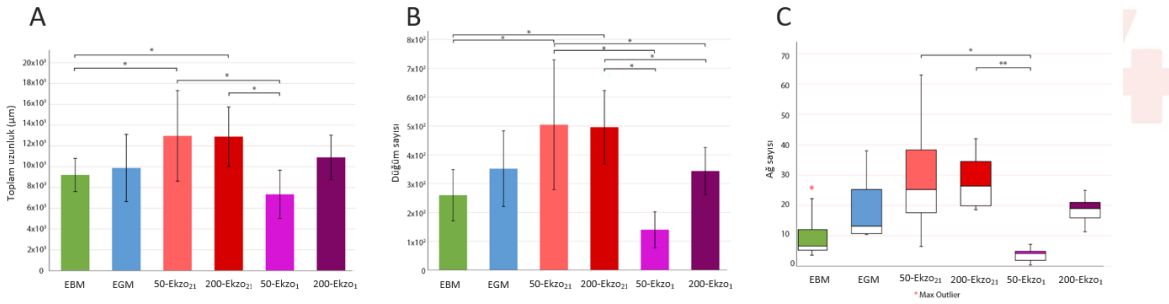

Şekil 5. Analizlere tabi tutulan parametreler, hücre uzantılarının toplam uzunluğu, düğüm sayısı ve ağ sayısıydı. Toplam uzunluk **(A)** $Ekzo_{21}$ gruplarında, EBM ve 50-$Ekzo_1$ gruplarına göre fazlaydı. Düğüm sayısı **(B)** $Ekzo_{21}$ gruplarında, EBM ve 50-$Ekzo_1$ gruplarına göre fazla bulundu. Ağ sayısı açısından **(C)** $Ekzo_{21}$ grupları, 50-$Ekzo_1$ gruplarından yüksekti. O_2 düzeyinden bağımsız olarak $Ekzo_{21}$ ve $Ekzo_1$ gruplarında 50 ve 200 µg/mL ekzozom konsantrasyonları arasında anlamlı bir fark yoktu.

HUVEC'in in-vitro anjiyogenez sırasında oluşturduğu hücre uzantıları ve hücresel temaslarını göstermek için bir hücre iskeleti bileşeni olan F-aktin, Phalloidin633 ile işaretlendi **(Şekil 6)**. EBM ve EGM grupları, kapalı ağların oluşumunu başlattı. $Ekzo_{21}$ grupları, $Ekzo_1$ gruplarına göre daha organize bir ağ yapısı sergiledi. **(Şekil 6)**.

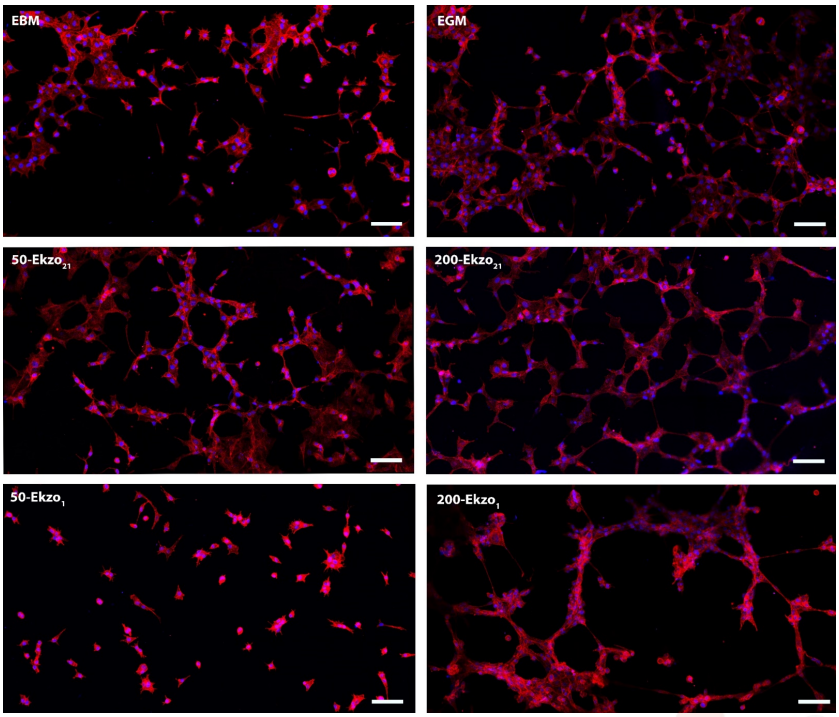

Şekil 6. İn-vitro tüp oluşumu sonrasında Phalloidin633 (kırmızı sinyal) ile işaretlenen HUVEC. Hoechst 33258 (mavi sinyal) ile çekirdek boyaması yapılmıştır. Ölçek çubuğu: 100 µm

4. TARTIŞMA VE SONUÇ

Çalışmamızda, normoksik ve hipoksik koşullar altında farklı dozlarda elde edilen MSH ekzozomlarının in-vitro tüp oluşturma potansiyelini test ettik ve karşılaştırdık. iGK-MSH ekzozomları, Zhang ve Huynh'un çalışmalarında olduğu gibi endotel hücrelerinin in vitro tüp oluşumunu artırdı (24, 25). Elde edilen ekzozom protein miktarı normokside hipoksiye göre daha fazlaydı. Literatürde bu bulguyla çelişkili sonuçlar (26-28) bulunmaktadır. Ancak bu çalışmalarda ve çalışmamızda farklı kaynak hücrelerin, farklı pasajlarda (P_3-P_6) kullanılmış, farklı sürelerde (40-72 saat) ve farklı kültür ortamlarında (FBS içermeyen ve ekzo içermeyen FBS içeren) kültüre edilmiş olması elde edilen ekzozom protein miktarını değiştiriyor olabilir.

Hipoksik ortam oluşturulması, iskemik bir ortamın taklit edildiği proanjiyojenik potansiyeli ortaya çıkarmak için yaygın bir yaklaşımdır. Dokulara ulaşan O_2 konsantrasyonu açısından vücudun anatomik bölgeleri arasında önemli farklılıklar gözlemlenir. Normoksi, hücre kültüründeki %21 O_2'yi tanımlamak için kullanılır. Normoksinin yaygın kullanımı, periferik doku oksijenasyonu için doğru bir tanım olmaktan uzaktır (29). Aslında, çoğu MSH vücutta %2-8 O_2 ortamında bulunur; bu O_2 düzeyi fizyoksi olarak tanımlanabilir (20, 30). Çalışmamızda hipoksik ortam oluşturmak amacıyla %1 O_2 düzeyini kullandık. O_2 düzeyine göre tüp oluşturma potansiyeli normokside (%21 O_2) hipoksiye göre (%1 O_2) daha fazlaydı. Hipoksik (1% O_2) MSH'den elde edilen ekzozomların anjiyojenik etkileri arttırdığının ortaya konduğu çalışmalar bulunmaktadır (31, 32); ancak hipoksi etkisi göz önüne alındığında,%5

O_2'de kültür yapılması Dougherty ve ark. çalışmasında (33) olduğu gibi fizyoksi ortamı sağlayarak hücrelerin metabolik özelliklerini iyileştirerek daha fazla anjiyogenik potansiyel ortaya çıkarabilir. Ayrıca MSH hipoksiye dayanıklı olduğu için yeterince anjiyogenik yanıt ortaya çıkarmadığı sonucuna varılabilir.

Önceki çalışmalarda kullanılan konsantrasyon aralığıyla tutarlı olan 50 ve 200 µg/mL'yi belirledik ve kullandık. O_2 düzeyinden bağımsız olarak konsantrasyona göre tüp oluşturma etkinlikleri 50 ve 200 µg/mL arasında benzerdi. Kullanılan ekzozom konsantrasyonunun anjiyogenik etkiyle doğru (34) ve ters orantılı (35) olduğunu gösteren çalışmalar mevcuttur. Tüp oluşumu üzerindeki etki için ekzozom konsantrasyonunun tanımlanmış bir aralığı yoktur. . Ayrıca hücrelerin belirli bir doygunluğa ulaştıktan sonra ekzozom alımı ve kullanımı sınırlandığı düşünülebilir. Farklı konsantrasyon ve O_2 düzeyleri kullanılarak çalışma genişletilebilir.

5. TEŞEKKÜR

Bu çalışma Ankara Üniversitesi BAP tarafından TTU-2022-2303 ve TSG-2545 numaralı projelerle ve TÜBİTAK 121S821 numaralı proje ile desteklenmiştir.

6. KAYNAKÇA

1. Elshaer SL, Bahram SH, Rajashekar P, Gangaraju R, El-Remessy AB. Modulation of Mesenchymal Stem Cells for Enhanced Therapeutic Utility in Ischemic Vascular Diseases. International Journal of Molecular Sciences. 2021;23(1):249.
2. Pittenger MF, Discher DE, Péault BM, Phinney DG, Hare JM, Caplan AI. Mesenchymal stem cell perspective: cell biology to clinical progress. npj Regenerative Medicine. 2019;4(1).
3. Li J, Zhang Q, Wang W, Lin F, Wang S, Zhao J. Mesenchymal stem cell therapy for ischemic stroke: A look into treatment mechanism and therapeutic potential. Journal of Neurology. 2021;268(11):4095-107.
4. Watt SM, Gullo F, van der Garde M, Markeson D, Camicia R, Khoo CP, et al. The angiogenic properties of mesenchymal stem/stromal cells and their therapeutic potential. Br Med Bull. 2013;108(1):25-53.
5. Kalaszczynska I, Ferdyn K. Wharton's Jelly Derived Mesenchymal Stem Cells: Future of Regenerative Medicine? Recent Findings and Clinical Significance. BioMed Research International. 2015;2015:1-11.
6. Kim D-W, Staples M, Shinozuka K, Pantcheva P, Kang S-D, Borlongan C. Wharton's Jelly-Derived Mesenchymal Stem Cells: Phenotypic Characterization and Optimizing Their Therapeutic Potential for Clinical Applications. International Journal of Molecular Sciences. 2013;14(6):11692-712.
7. Maacha S, Sidahmed H, Jacob S, Gentilcore G, Calzone R, Grivel JC, et al. Paracrine Mechanisms of Mesenchymal Stromal Cells in Angiogenesis. Stem Cells Int. 2020;2020:4356359.
8. Janockova J, Slovinska L, Harvanova D, Spakova T, Rosocha J. New therapeutic approaches of mesenchymal stem cells-derived exosomes. J Biomed Sci. 2021;28(1):39.
9. Pegtel DM, Gould SJ. Exosomes. Annu Rev Biochem. 2019;88:487-514.

10. Didamoony MA, Soubh AA, Atwa AM, Ahmed LA. Innovative preconditioning strategies for improving the therapeutic efficacy of extracellular vesicles derived from mesenchymal stem cells in gastrointestinal diseases. Inflammopharmacology. 2023;31(6):2973-93.
11. Kalluri R, LeBleu VS. The biology, function, and biomedical applications of exosomes. Science. 2020;367(6478).
12. Kaur B, Miglioranza Scavuzzi B, F Abcouwer S, N Zacks D. A simplified protocol to induce hypoxia in a standard incubator: A focus on retinal cells. Experimental Eye Research. 2023;236:109653.
13. Moreira-Soares M, Coimbra R, Rebelo L, Carvalho J, D. M. Travasso R. Angiogenic Factors produced by Hypoxic Cells are a leading driver of Anastomoses in Sprouting Angiogenesis–a computational study. Scientific Reports. 2018;8(1):8726.
14. Pichiule P, Chavez JC, LaManna JC. Hypoxic regulation of angiopoietin-2 expression in endothelial cells. J Biol Chem. 2004;279(13):12171-80.
15. Schultz K, Fanburg BL, Beasley D. Hypoxia and hypoxia-inducible factor-1alpha promote growth factor-induced proliferation of human vascular smooth muscle cells. Am J Physiol Heart Circ Physiol. 2006;290(6):H2528-34.
16. Ge L, Xun C, Li W, Jin S, Liu Z, Zhuo Y, et al. Extracellular vesicles derived from hypoxia-preconditioned olfactory mucosa mesenchymal stem cells enhance angiogenesis via miR-612. J Nanobiotechnology. 2021;19(1):380.
17. Han Y, Ren J, Bai Y, Pei X, Han Y. Exosomes from hypoxia-treated human adipose-derived mesenchymal stem cells enhance angiogenesis through VEGF/VEGF-R. The International Journal of Biochemistry & Cell Biology. 2019;109:59-68.
18. Liu J, Yan Z, Yang F, Huang Y, Yu Y, Zhou L, et al. Exosomes Derived from Human Umbilical Cord Mesenchymal Stem Cells Accelerate Cutaneous Wound Healing by Enhancing Angiogenesis through Delivering Angiopoietin-2. Stem Cell Rev Rep. 2021;17(2):305-17.
19. Long R, Wang S. Exosomes from preconditioned mesenchymal stem cells: Tissue repair and regeneration. Regenerative Therapy. 2024;25:355-66.
20. Phelps J, Hart DA, Mitha AP, Duncan NA, Sen A. Physiological oxygen conditions enhance the angiogenic properties of extracellular vesicles from human mesenchymal stem cells. Stem Cell Res Ther. 2023;14(1):218.
21. Yuan N, Ge Z, Ji W, Li J. Exosomes Secreted from Hypoxia-Preconditioned Mesenchymal Stem Cells Prevent Steroid-Induced Osteonecrosis of the Femoral Head by Promoting Angiogenesis in Rats. Biomed Res Int. 2021;2021:6655225.
22. DeCicco-Skinner KL, Henry GH, Cataisson C, Tabib T, Gwilliam JC, Watson NJ, et al. Endothelial cell tube formation assay for the in vitro study of angiogenesis. J Vis Exp. 2014(91):e51312.
23. Carpentier G, Berndt S, Ferratge S, Rasband W, Cuendet M, Uzan G, et al. Angiogenesis Analyzer for ImageJ - A comparative morphometric analysis of "Endothelial Tube Formation Assay" and "Fibrin Bead Assay". Sci Rep. 2020;10(1):11568.
24. Huynh PD, Van Pham P, Vu NB. Exosomes Derived from Human Umbilical Cord Mesenchymal Stem Cells Enhance Angiogenesis Through Upregulation of the VWF and Flk1 Genes in Endothelial Cells. Adv Exp Med Biol. 2023.

25. Zhang B, Wu X, Zhang X, Sun Y, Yan Y, Shi H, et al. Human umbilical cord mesenchymal stem cell exosomes enhance angiogenesis through the Wnt4/beta-catenin pathway. Stem Cells Transl Med. 2015;4(5):513-22.

26. Anderson JD, Johansson HJ, Graham CS, Vesterlund M, Pham MT, Bramlett CS, et al. Comprehensive Proteomic Analysis of Mesenchymal Stem Cell Exosomes Reveals Modulation of Angiogenesis via Nuclear Factor-KappaB Signaling. Stem Cells. 2016;34(3):601-13.

27. Bian S, Zhang L, Duan L, Wang X, Min Y, Yu H. Extracellular vesicles derived from human bone marrow mesenchymal stem cells promote angiogenesis in a rat myocardial infarction model. Journal of Molecular Medicine. 2014;92(4):387-97.

28. Zhang HC, Liu XB, Huang S, Bi XY, Wang HX, Xie LX, et al. Microvesicles derived from human umbilical cord mesenchymal stem cells stimulated by hypoxia promote angiogenesis both in vitro and in vivo. Stem Cells Dev. 2012;21(18):3289-97.

29. McKeown SR. Defining normoxia, physoxia and hypoxia in tumours-implications for treatment response. Br J Radiol. 2014;87(1035):20130676.

30. Dong L, Wang Y, Zheng T, Pu Y, Ma Y, Qi X, et al. Hypoxic hUCMSC-derived extracellular vesicles attenuate allergic airway inflammation and airway remodeling in chronic asthma mice. Stem Cell Res Ther. 2021;12(1):4.

31. Xue C, Shen Y, Li X, Li B, Zhao S, Gu J, et al. Exosomes Derived from Hypoxia-Treated Human Adipose Mesenchymal Stem Cells Enhance Angiogenesis Through the PKA Signaling Pathway. Stem Cells Dev. 2018;27(7):456-65.

32. Zhang XF, Wang T, Wang ZX, Huang KP, Zhang YW, Wang GL, et al. Hypoxic ucMSC-secreted exosomal miR-125b promotes endothelial cell survival and migration during wound healing by targeting TP53INP1. Mol Ther Nucleic Acids. 2021;26:347-59.

33. Dougherty JA, Patel N, Kumar N, Rao SG, Angelos MG, Singh H, et al. Human Cardiac Progenitor Cells Enhance Exosome Release and Promote Angiogenesis Under Physoxia. Front Cell Dev Biol. 2020;8:130.

34. Sun X, Mao Y, Liu B, Gu K, Liu H, Du W, et al. Mesenchymal Stem Cell-Derived Exosomes Enhance 3D-Printed Scaffold Functions and Promote Alveolar Bone Defect Repair by Enhancing Angiogenesis. J Pers Med. 2023;13(2).

35. Taghdiri Nooshabadi V, Verdi J, Ebrahimi-Barough S, Mowla J, Atlasi MA, Mazoochi T, et al. Endometrial Mesenchymal Stem Cell-Derived Exosome Promote Endothelial Cell Angiogenesis in a Dose Dependent Manner: A New Perspective on Regenerative Medicine and Cell-Free Therapy. Arch Neurosci. 2019;6(4):e94041.

COMPARATIVE ANALYSIS OF ETHANOL EXTRACTS FROM RHEUM RIBES L. (IŞKIN) ON THE VIABILITY OF TM3 LEYDIG CELLS UNDER NORMOXIC AND HYPOXIC CONDITIONS

NUR ELAGÜL-TOMBUL[1,2], GÜL İPEK GÜNDOĞAN[3], EBRU ÖZDEMİR-NATH[4]

[1]Istanbul Yeni Yüzyıl University, Faculty of Medicine, Department of Histology and Embryology, Istanbul, Turkey, nur.elagultombul@yeniyuzyil.edu.tr

[2]Health Sciences University, Institute of Health Sciences, Department of Histology and Embryology, Istanbul, Turkey, n.elagul1@hotmail.com

[3]Biruni University, Faculty of Medicine, Department of Histology and Embryology, Istanbul, Turkey, gulipekgundogan@gmail.com

[4]Altınbaş University, Faculty of Pharmacy, Department of Pharmaceutical Botany, Istanbul, Turkey, ebru.ozdemir@altinbas.edu.tr

ABSTRACT

Rheum ribes L. (Işkın), from Polygonaceae species, is used in traditional medicine for stomach, kidney, diabetes, and cholesterol disorders and shows antimicrobial, anti-inflammatory, and antioxidant properties. This study compares the effects of 96% and 70% ethanol extracts from Rheum ribes L. stem, root, and seeds on the viability of TM3 Leydig cells under normoxic and hypoxic conditions. Extracts were prepared by drying and macerating plant parts. Cells were cultured and treated with extracts at 0.0025–0.5 mg/mL for 24, 48, and 72 hours, with MTT assay assessing viability. In hypoxia, viability was measured with MTT, with $p<0.05$ as significant. At 48 hours, low doses of 70% EtOH and high doses of 96% EtOH stem extracts significantly increased cell viability. Under hypoxia, both extracts improved viability compared to the hypoxia control, with 96% EtOH extract being more effective. At 48 hours, 70% EtOH root extracts were more effective, but under hypoxia, 96% EtOH significantly increased viability, nearing control levels. For seed extracts, higher doses of 70% EtOH increased viability by more than 96% EtOH at 48 hours. In hypoxia, 70% EtOH extract was more effective than both 96% EtOH and the control. In conclusion, both 70% EtOH and 96% EtOH extracts from Rheum ribes L. stem, root, and seed seem to increase the viability rate significantly compared to control group under hypoxic conditions. However, 96% EtOH seed and root extracts, and 70% EtOH seed extract seem to show antioxidant properties, protecting cells from hypoxia compared to the untreated control group.
Keywords: Cell viability, hypoxia, normoxia, Rheum ribes L., TM3 Leydig cell

INTRODUCTION

Hypoxia is defined as a low oxygen amount in the cell, tissue, or organism. Hypoxia occurs as a result of problems in testicular blood flow such as varicocele or testicular torsion, which are subtypes of male infertility, and as a result, cells are dragged into apoptosis due to increased oxidative stress (1).

Antioxidant natural products have been used in traditional medicine for many years in the treatment of various diseases. Rheum species are important due to the presence of anthracene derivatives in their underground parts (2). *Rheum ribes* L. (Işkın, Işgın) is a rhubarb species belonging to the Polygonaceae family that grows wild in Lebanon, Iraq, Iran, and the Eastern Anatolia Regions of Turkey (3). It is widely consumed both as food and for medicinal purposes among the people. It has been reported that it has benefits such as appetite enhancement, diabetes healing, stomach indigestion relieving and blood pressure balancing (4). In addition, various studies have shown that it has antioxidant and antimicrobial activity and prevents diabetes and cancer (5–9). In a previous study, it was shown that ethanol extracts of *Rheum ribes* L. roots had more effective antioxidant and antimicrobial activity than the aqueous extract (10). In another previous study, it was reported that *Rheum ribes* L. root alcoholic extract strengthened the reproductive system by reducing oxidative stress in male rats (11). Based on the high antioxidative effect of *Rheum ribes* L., in this study, 70% and 96% ethanol (EtOH) extracts were compared in normoxic and hypoxic environments in the TM3 Leydig cell line.

MATERIALS & METHOD

Plant extraction

The roots, seeds, and stem parts of *Rheum ribes* L. species were collected from Erek Mountain in Van. Extraction processes were carried out in Altınbaş University Natural Products R&D Center (DÜAGEM) BB315 laboratory. Root, seed, and stem parts were ground to powder in a grinder. 70% and 96% EtOH solvents were used as 10 parts to solvent and 1 part to plant parts, and macerated for 3 days in a tightly closed container, protected from light, and stirred frequently. After filtering with filter paper, the solvent was evaporated to dryness in a rotary evaporator at 120 RPM at 40 ºC. The dry extract obtained was placed in vials and stored at -80 ºC until analysis.

Cell culture

TM3 mouse Leydig cells were obtained from American Tissue Culture Company, USA. The cells were grown in a 1:1 mixture of Ham's F-12 Medium and Dulbecco's Modified Eagle Medium containing 1.2 g/L sodium bicarbonate, 15 mM HEPES, and 5% penicillin/streptomycin and supplemented with 5% horse serum and 20% fetal bovine serum.

They were maintained in a humidified incubator with 5% CO_2 to ensure complete attachment of cells to the culture dish.

Experimental design

The cells were plated on a 96-well plate at a density of $1x10^4$/well. Then different doses (0.0025-0.005-0.01-0.025-0.05-0.1-0.15-0.2-0.25-0.3-0.4-0.5 mg/mL) of plant extracts were applied for 24h, 48h, and 72h by performing the 3-(4,5-Dimethylthiazol-2-yl)-2,5-Diphenyltetrazolium Bromide (MTT) assay for viability analysis (12). The first concentration at 48h that showed a significant increase compared to the control was applied to cells exposed to a hypoxic environment [200 µM $CoCl_2$ (13)] for 24h and the viability rates (%) were determined by the MTT assay.

For MTT analysis, the medium in the wells was removed and 10 µL of 12 mM MTT stock solution was added to each well and incubated for 4h at 37 °C. Then, 100 µL of DMSO was added to each well and incubated for 10 min at 37 °C, and the absorbance was measured at 540 nm.

Statistical analysis

All data on all tests are the average of triplicate analyses. All analyses were performed using the GraphPad Prism 8.0.2 package program. Significant differences between groups were determined by one-way ANOVA and two-way ANOVA "false discovery rate" tests. A value of $p<0.05$ was considered statistically significant.

RESULTS

The viability results of all extracts at 24, 48, and 72 hours are shown in Figures 1, 2, and 3. To assess the effects of plant extracts in a hypoxic environment, the first concentration that significantly increased viability in the untreated control group at 48 hours was selected as the experimental dose.

The viability rate increased significantly at doses of 0.2 mg/mL and above for the 96% EtOH stem extracts at 48 hours, compared to the untreated control. For the 70% EtOH stem extracts, viability significantly increased at doses between 0.025 and 0.5 mg/mL, except for 0.3 mg/mL, at 48 hours. The 70% EtOH extract at 0.025, 0.1, and 0.15 mg/mL, and the 96% EtOH extract at 0.3, 0.4, and 0.5 mg/mL, led to a more significant increase in viability at 48 hours. Both ethanol extracts significantly increased viability compared to the hypoxia-induced

control group, with the 96% EtOH stem extract showing a greater effect than the 70% EtOH extract. However, in the hypoxic environment, viability was significantly lower in the groups treated with plant extracts compared to the untreated control group (Figure 1).

The viability rate significantly increased at a dose of 0.15 mg/mL and decreased at doses of 0.25 mg/mL and above for the 96% EtOH root extracts at 48 hours, compared to the untreated control group. For the 70% EtOH root extracts, viability significantly increased at doses of 0.005, 0.2, and 0.3 mg/mL, and decreased at doses of 0.15 and 0.5 mg/mL, compared to the untreated control group. The 96% EtOH extracts at doses of 0.01 and 0.15 mg/mL, and the 70% EtOH extracts at doses of 0.05, 0.2, and 0.3 mg/mL, increased the viability rate significantly at 48 hours. Both ethanol root extracts significantly increased viability compared to the hypoxia-induced control group, with the 96% EtOH root extract showing a greater effect than the 70% EtOH extract. In the hypoxic condition, the viability rate was significantly lower in the 70% EtOH root extract group, while no significant difference was observed in the 96% EtOH group compared to the untreated control group (Figure 2).

For the 96% EtOH seed extracts, the viability rate significantly increased at doses between 0.025 and 0.4 mg/mL, except for 0.05 mg/mL, at 48 hours, compared to the untreated control. In the 70% EtOH seed extracts, the viability rate increased at doses between 0.05 and 0.5 mg/mL compared to the untreated control. The 96% EtOH extract at 0.025 mg/mL and the 70% EtOH extract at 0.25 and 0.3 mg/mL increased viability significantly more at 48 hours. In the hypoxic environment, the viability rates for both seed extracts increased significantly compared to the hypoxia-induced and untreated control groups. Additionally, the viability rate in the 70% EtOH seed extract group under hypoxic conditions was significantly higher than in both the 96% EtOH seed extract under hypoxia and the 70% EtOH seed extract groups (Figure 3).

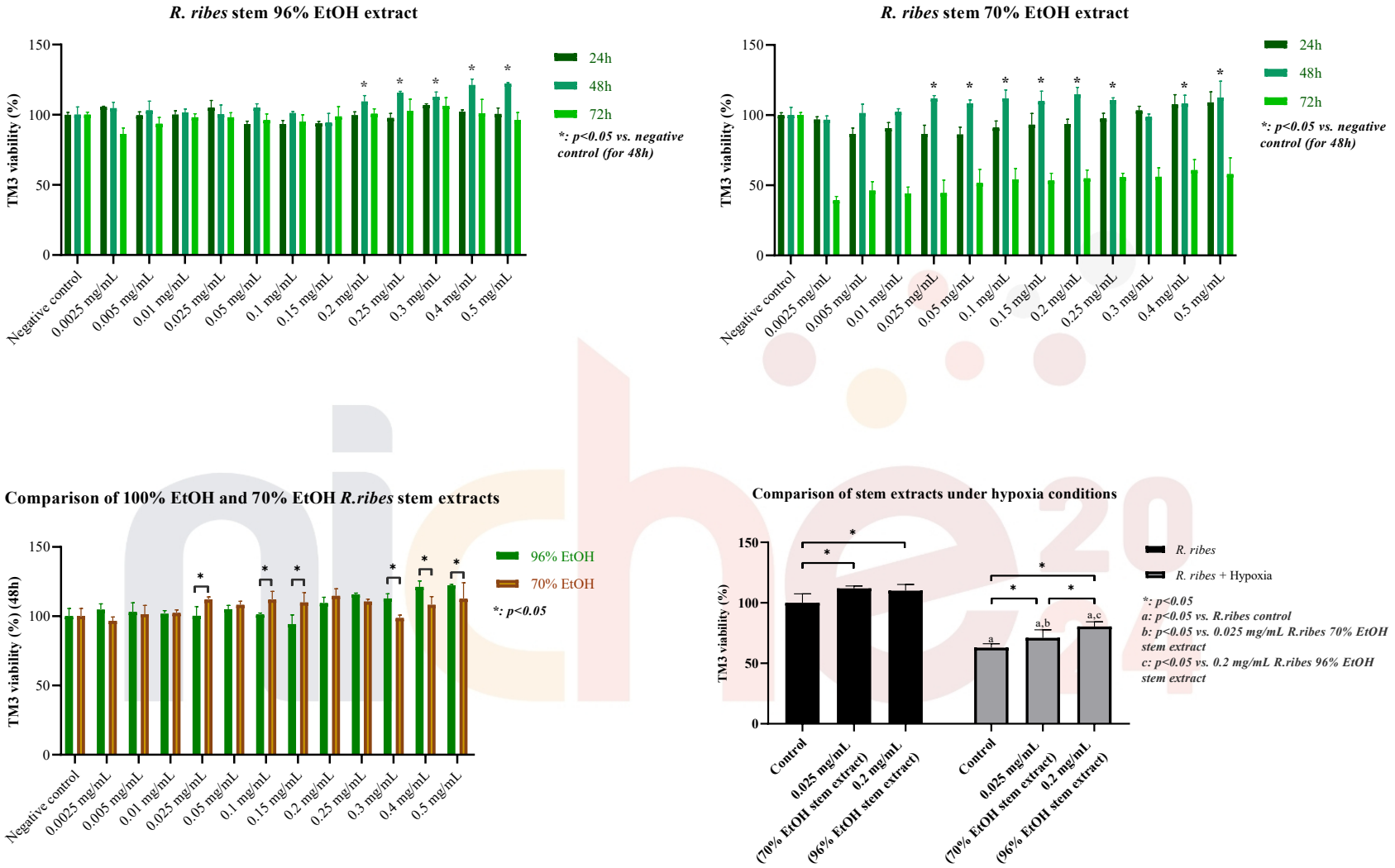

Figure 1. MTT analysis of *Rheum ribes* L. stem extracts

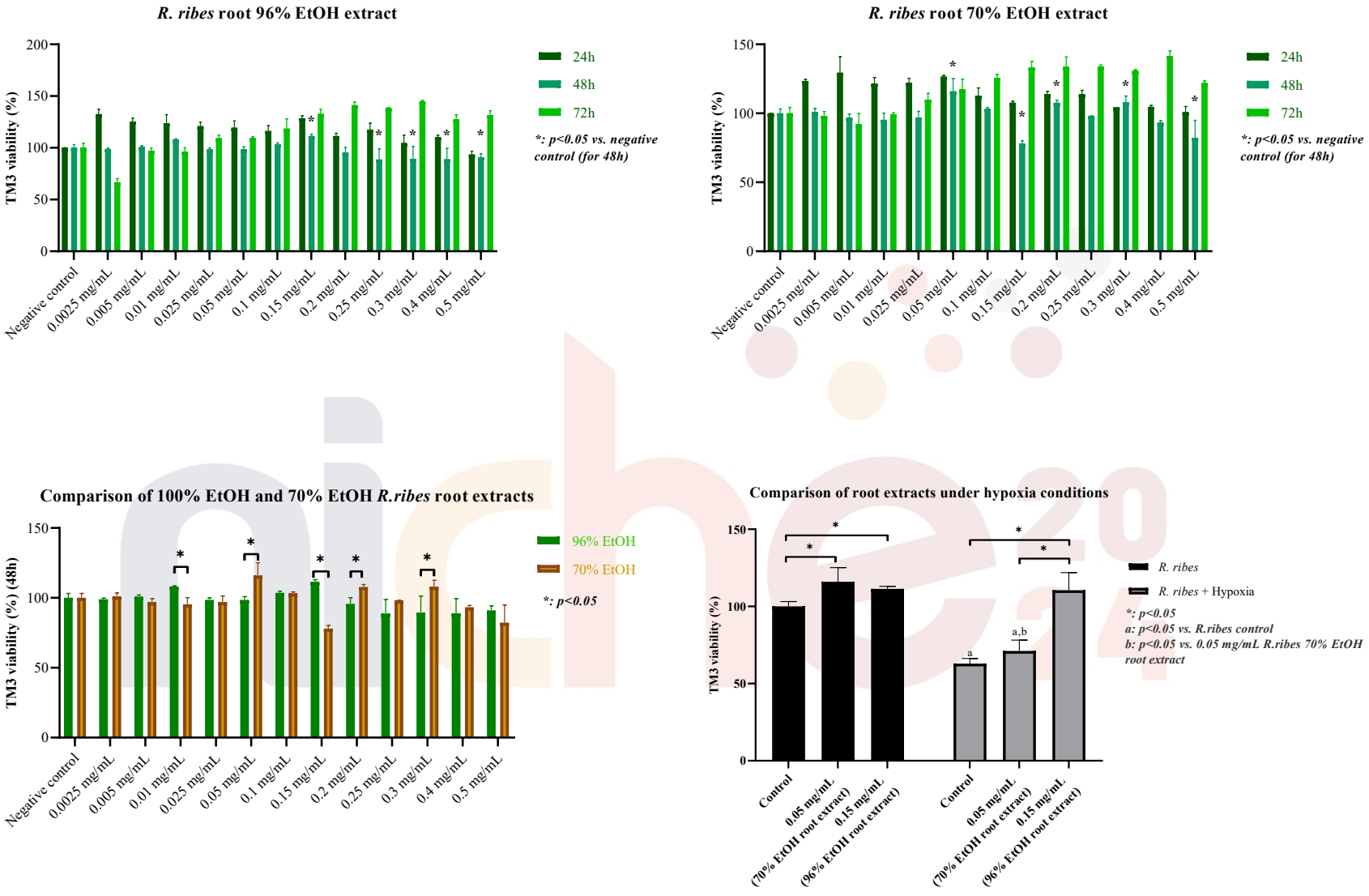

Figure 2. MTT analysis of *Rheum ribes* L. root extracts

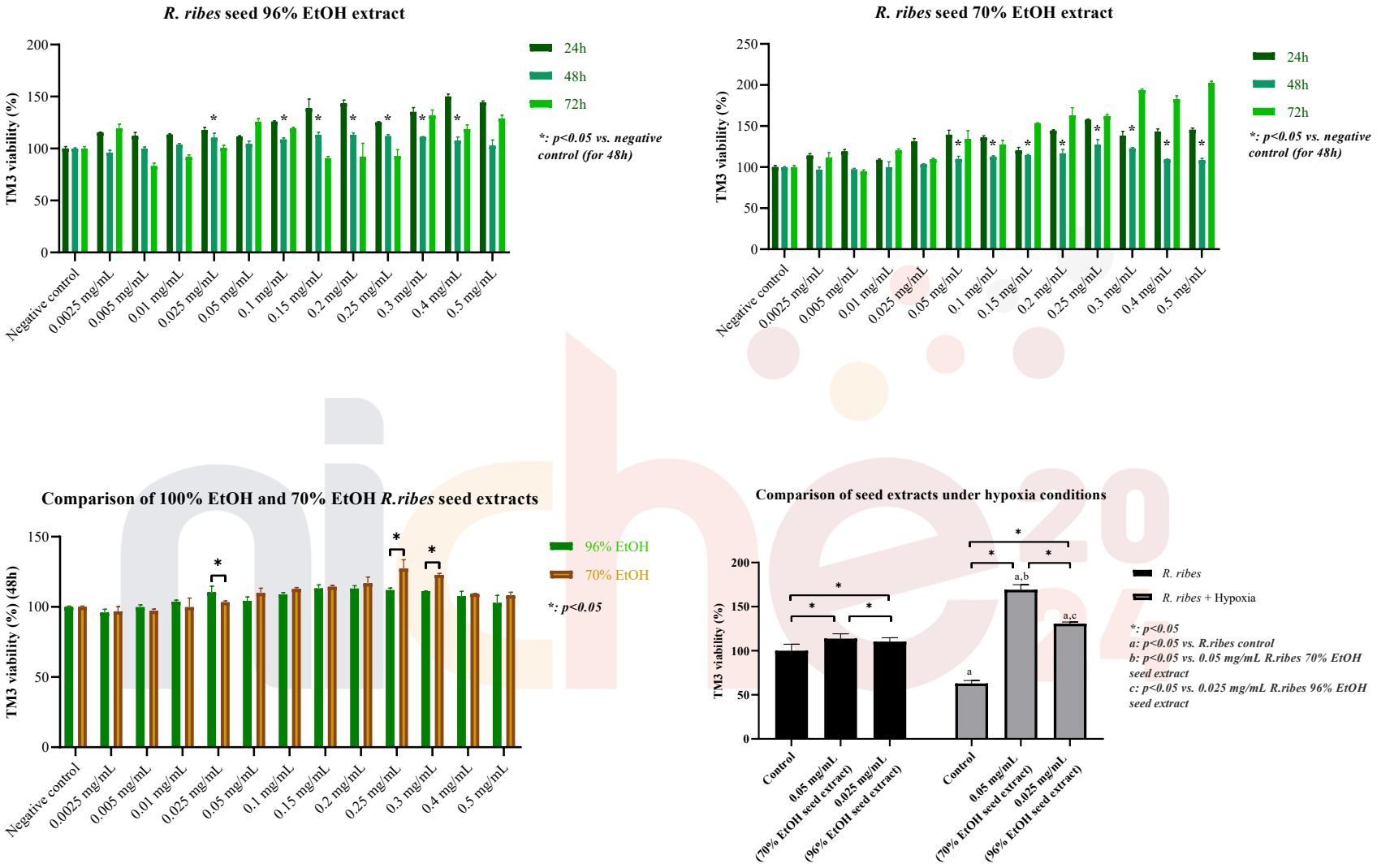

Figure 3. MTT analysis of *Rheum ribes* L. seed extracts

DISCUSSION AND CONCLUSION

It has been reported that most natural products exhibit antioxidative effects due to their high phenolic content, making it important to perform total phenolic content analyses in natural products (9). Some studies have shown that *Rheum ribes* L. consumed both as food and as raw material, possesses strong antioxidative properties (9, 14). It has also been reported that ethanol extracts have higher antioxidant activity compared to aqueous extracts due to their high phenolic content (9, 10, 15). In this study, we compared the effects of 70% and 96% EtOH extracts of *Rheum ribes* L. stem, root, and seed extracts on the viability of TM3 Leydig cells under normoxic and hypoxic conditions. Different doses of ethanol extracts affected the viability at different levels under normoxic conditions. However, it can be said that 0.15 mg/mL 96% EtOH root extract, 0.025 mg/mL 96% EtOH, and 0.05 mg/mL 70% EtOH seed extracts significantly increased the viability rates and may have shown antioxidant activity under hypoxic conditions. Based on the findings obtained, we plan to conduct further analyses such as the effects of *Rheum ribes* L. extracts on cell death and oxidative stress levels. On the other hand, it is a necessity to support this study with more detailed biochemical, histological and molecular studies.

REFERENCES

1. Reyes JG, Farias JG, Henríquez-Olavarrieta S, Madrid E, Parraga M, Zepeda AB, Moreno RD (2012) The hypoxic testicle: Physiology and pathophysiology. Oxid Med Cell Longev. https://doi.org/10.1155/2012/929285
2. Uyar P (2014) Evaluation of in Vitro Antioxidative, Cytotoxic and Apoptotic Activities of Rheum ribes Ethyl Acetate Extracts. Journal of Plant Sciences (Science Publishing Group) 2:339
3. Davis PH (ed) (1967) Flora of Turkey and the East Aegean Islands 2. Edinburgh University Press, Edinburgh
4. Sırrı M, Sırrı G (2020) Hakkâri İlinde Gıda Olarak Tüketilen Yabani Bitki ve Yabancı Ot Türlerinin Güncel Durumu. Avrupa Bilim ve Teknoloji Dergisi 393–409
5. Zahra N, ALI N, MASOUD HT (2019) Evaluation of antioxidant, anti-cancer and anti-inflammatory characteristics of bio-synthesized silver nanoparticles produced by waste extract of Rheum ribes L. 23:241–252
6. Noori S, Kiasat AR, Kolahi M, Mirzajani R, Seyyed Nejad SM (2022) Determination of secondary metabolites including curcumin in Rheum ribes L. and surveying of its antioxidant and anticancer activity. Journal of Saudi Chemical Society 26:101479

7. Meydan I, Burhan H, Gür T, Seçkin H, Tanhaei B, Sen F (2022) Characterization of Rheum ribes with ZnO nanoparticle and its antidiabetic, antibacterial, DNA damage prevention and lipid peroxidation prevention activity of in vitro. Environ Res. https://doi.org/10.1016/J.ENVRES.2021.112363

8. Yildirim M, Degirmenci U, Akkapulu M, Comelekoglu U, Balli E, Metin Ozcan T, Berköz M, Yalin AE, Yalin S (2020) The effect of Rheum ribes L. on oxidative stress in diabetic rats. J Basic Clin Physiol Pharmacol. https://doi.org/10.1515/JBCPP-2020-0058

9. Oktay M, Yildirim Ali, Bilaloglu V, Gulcin I (2010) Antioxidant Activity of Different Parts of Isgin (Rheum ribes L.). Asian Journal of Chemistry 19:3047–3055

10. Khalil K, Taha E, M Rahim S (2014) Phenolic profile, antioxidant, and antibacterial effects of ethanol and aqueous extracts of Rheum ribes L. roots. Pharm Lett 6:201–205

11. Abdalrahim H. Eefan, Saleh M. Rahim (2020) The role of Rheum ribes roots alcoholic extract in reducing the effect of oxidative stress on the reproductive system of male rats. Tikrit Journal of Pure Science 25:22–26

12. Mosmann T (1983) Rapid colorimetric assay for cellular growth and survival: Application to proliferation and cytotoxicity assays. J Immunol Methods. https://doi.org/10.1016/0022-1759(83)90303-4

13. Karimi S, Jalili C, Mansouri K, Bahremand F, Gholami MR (2023) Effect of melatonin on steroidogenesis-related enzymes expression and testosterone synthesis following CoCl2-induced hypoxia in TM3 Leydig cells. Iran J Basic Med Sci 26:1041–1046

14. Öztürk M, Aydoğmuş-Öztürk F, Duru ME, Topçu G (2007) Antioxidant activity of stem and root extracts of Rhubarb (Rheum ribes): An edible medicinal plant. Food Chem 103:623–630

15. Bilgiç Alkaya D, Ayaz Seyhan S, Ozturk B (2019) Influence of extraction method on antioxidant properties of Rheum ribes root extract. Ovidius University Annals of Chemistry 30:44–47

NICOTINAMIDE MONONUCLEOTIDE ALLEVIATES SEPSIS-INDUCED LIVER INJURY IN A RAT MODEL OF CECAL LIGATION AND PUNCTURE

ZELİHA YETİM[1], ERGİN TAŞKIN[2], ÖZLEM DEMİR[3]

1 University of Health Science, Histology and Embriology, İstanbul, Türkiye, zeliha.yetim@sbu.edu.tr

2 Ağrı İbrahim Çeçen University, Medical Biochemistry, Ağrı, Türkiye, etaskin@agri.edu.tr

3 Erzincan Binali Yıldırım University, Histology and Embriology, Erzincan, Türkiye, ozlem.abuc@erzincan.edu.tr

Abstract

Aim: In sepsis, cytokines cause oxidative stress and apoptosis, leading to organ failure such as liver damage. Nicotinamide mono nucleotide (NMN) decreases intracellular NAD+ levels, and protects organs against oxidative stress. In this study, it was investigated whether NMN prevented oxidative stress and liver injury in sepsis.

Material and method: 21 Sprague Dawley rats were divided into 3 groups: Control, Sepsis, Sepsis+NMN. The sepsis model was established with cecal ligation perforation (CLP). The CLP+NMN group were given NMN at a dose of 500 mg/kg intraperitoneally 30 minutes before and 12 hours after sepsis was established. After the experiment, histological and biochemical evaluations were performed.

Results: Sepsis group exhibited increased inflammatory cells and liver injury symptoms were obvious. In sepsis+NMN group, histological alterations were ameliorated. The biochemical parameters increased significantly in sepsis group and decreased in sepsis+NMN group.

Conclusion: The results showed that NMN reduced liver damage in sepsis.

Key Words: Nicotinamide Mononucleotide, liver, sepsis.

1. Introduction

Sepsis causes aberrant inflammatory responses. The cytokines induces apoptosis and cell dysfunction (1). The generation of reactive oxygen species (ROS) is the major feature of sepsis (2). Pathogens, their toxins or inflammatory mediators may lead to liver injury. Pathophysiology of acute liver injury includes oxidative stress, apoptosis, necrosis and inflamation. ROS in sepsis pathogenesis include superoxide, hydroxyl radicals and hydrogen peroxide (3,4).

NAD is a redox coenzyme involved in cellular metabolism, stress resistance, DNA repair (5). For this reason, augmentation of NAD+ levels with its precursors is emerging as a new strategy to counteract inflammation. Nicotinamide mono nucleotide (NMN) is a precursor to NAD+ (6). Therefore, administration of NMN efficiently boosts NAD+ levels, and protects against lots of diseases (6,7). NAD+ is decreased in sepsis (7,8). Therefore, it is possible that NMN may be useful in sepsis. In our study, we aimed to investigated whether treatment with NMN prevented liver injury and oxidative stress in sepsis.

2. Material And Methods

Experimental protocols were confirmed by the animal ethics committee of University of Health Science. Female rats (University of Health Science Experimental Laboratories, Sprague Dawley, body weight 210–230 g) were used. Animals were divided into 3 groups (n=7): control group, sepsis group and sepsis+NMN group. Sepsis model was established by CLP as previously described (9) with little modifications. 30 minutes before and 12 hours after the CLP administration, NMN (500 mg/kg) was administered intraperitoneally to the sepsis+NMN group. 24 hours after the CLP administration, animals were subjected to a painless death with thiopental overdose (50 mg/kg, i.p.) followed by decapitation.

Right liver samples were grinded with liquid nitrogen. They were homogenated (QIAGEN TissueLyser LT, USA) at 35 Hz (15 minutes at 4°C). All homogenates were centrifuged at 1000 g for 10 minutes. Finally supernatants were saved.

Livers (100 mg) were washed with 0.9% NaCl, then centrifuged (+4°C, 3000g, 10 minutes). After that, 10% liver homogenates were prepared by mixing cold 1.15% KCl with 0.01 M Na2HPO4, (pH=7.4). Homogenates were centrifuged (10.000xg) for 20 min at +4°C. Proteins were measured from the supernatants using the Lowry method (10). The superoxide dismutase (SOD) and malondialdehyde (MDH) activity were measured according to previous studies (11,12).

Left livers were fixed in 10 % formalin, dehydrated, cleared, embedded, cut and stained with hematoxylin and eosin.

Descriptive statistical datas were expressed as means ± SEM. One-way ANOVA and Duncan's multiple range was used with SPSS version 20.0.

3. Results

Control group had normal liver tissues. In sepsis group, livers exhibit sinusoidal congestion and haemorrhage, sinusoidal dilation and inflammatory cell infiltration. Apoptotic hepatocytes and ballooning hepatocytes were also available. Histological analysis shows decreased sinusoidal congestion and haemorrhage, sinusoidal dilation and less apoptotic hepatocytes in the liver of NMN treated rats. Inflammatory cells were still available. There was almost no ballooning hepatocytes (Figure 1).

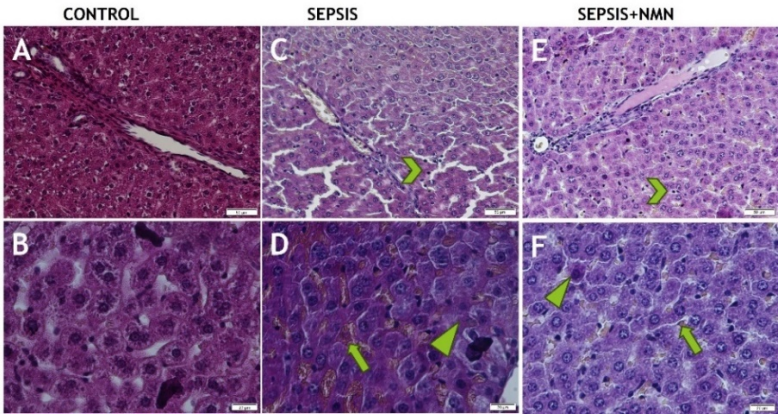

Figure 1. Microscopic images of livers belonging to control, sepsis and NMN treated groups after H&E staining. Control group normal liver parenchyma morphology (A-B). Sinusoidal congestion, hemorrhage, dilatation (arrows) and apoptotic hepatocytes (triangle) are seen in the CLP group (C-D). Lymphocyte infiltration is observed in sepsis (C)and NMN group (arrowheads)(E). Sinusoidal congestion, hemorrhage, dilatation (arrows) and apoptotic hepatocytes (triangle) are less in NMN group (F).

AST, ALT and GGT values increased in rats treated with sepsis ($p<0.001$) and decreased in rats treated with NMN ($p<0.05$). Total protein amount decreased in the sepsis and NMN groups compared to the control group. ($p<0.01$). There is not any differences between the groups in terms values biluribin, ALP and LDH (Figure 2). SOD values decreased in rats treated with sepsis ($p<0.05$) and increased in rats in NMN group ($p<0.01$). There is not any differences between the groups in terms values MDH (Figure 3).

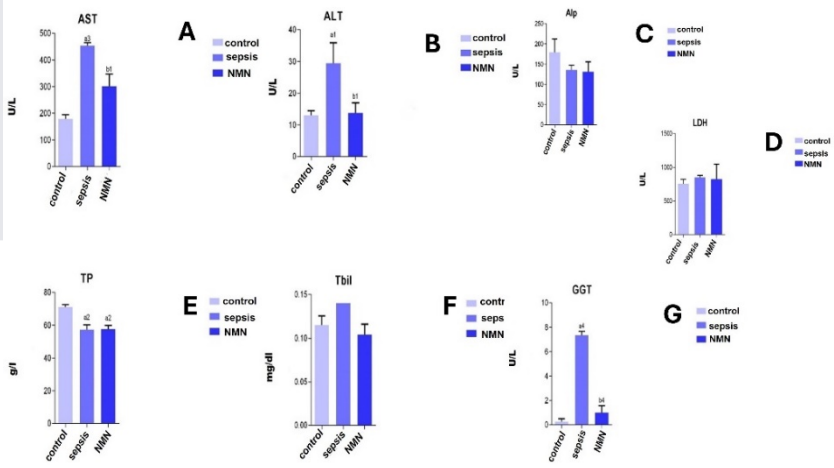

Figure 2. Serum levels. All datas are presented as mean ± SEM (n=7). Statistical difference was defined as $p < 0.05$. A: AST values increased in rats treated with sepsis ($p<0.001$) and decreased in rats treated with NMN ($p<0.05$). B: ALT values increased in rats subjected to sepsis ($p<0.05$) and decreased in rats given NMN ($p<0.05$). C: There is no difference between the groups in terms values ALP. D: There is no difference between the groups in terms of LDH values. E: Total protein amount decreased in the sepsis and NMN groups compared to the control group ($p<0.01$). F: There is no difference between the groups in terms values biluribin. G: While GGT values increased in the sepsis group ($p<0.0001$), GGT values decreased

significantly in the NMN group ($p<0.0001$).

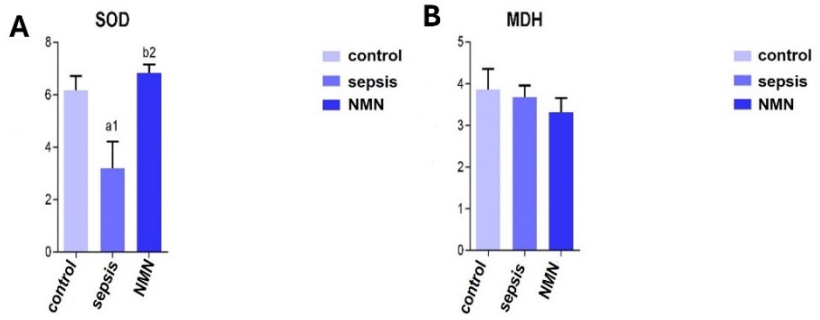

Figure 3. SOD and MDH levels. Datas are presented as mean ± SEM (n=7). A. SOD values decreased in rats treated with sepsis ($p<0.05$) and increased in rats in NMN group ($p<0.01$). B. There is not any differences between the groups in terms values MDH

4. Discussion

The therapeutic approaches to reduce liver injury in sepsis are not enough. In this study, we report that pre-administration of NMN prevented liver injury in septic rats.

In sepsis, following molecular, biochemical, and physiological changes; steatosis and hepatocellular injury occures. This injury is associated with hepatocyte apoptosis, necrosis, and accumulation of neutrophils (13). Our histological findings show that NMN has a hepato-protective effect against sepsis induced liver damage. It decreases harmful effects of sepsis.

In this study SOD values decreased in rats treated with sepsis and increased in rats treated with NMN. Increased levels of SOD in NMN treated group proved the protective effects of NMN in liver injury under septic conditions. However, there is no difference between the groups in terms values MDH.

Increased levels of AST, ALT and bilirubin are considered indicators of liver damage (14). In the diagnosis and treatment of sepsis; criteria such as increased ALP, ALT, AST, GGT serum liver enzymes are considered as indicators of hepatic damage (15). ALT (alanine transaminase) is the predominant hepatocyte enzyme routinely used to detect liver damage (16).

It was shown that NMN treatment and NAD+ supplementation effectively prevented the ethanol-induced increases in ALT and AST plasma levels in liver damage caused by chronic alcohol consumption (17). Another study showed that NMN treatment reduced serum ALT, AST and BUN levels in sepsis (18).

In our study, it was observed that AST and ALT parameters increased and decreased in the groups treated with NMN. However, there is no difference in ALP values between the groups. Additionally, when we looked at the bilirubin level, which is a marker of liver damage, it was revealed that the values in the NMN treatment group were lower than those in the sepsis group. Similarly, while the GGT value studied in the blood increased in the sepsis group, the GGT value decreased significantly in the groups treated with NMN.

LDH activity is considered as a marker of liver damage (19). In our study, LDH activity was not affected by liver damage. In addition, it was observed that the total protein amount decreased in the sepsis and NMN groups compared to the control group.

In a study, it was observed that SOD activity was relatively low in the sepsis group created by CLP applied to rats (20). In our study, while serum SOD activity decreased significantly in the sepsis group, NMN, which has an antioxidant effect, was found to significantly increase serum SOD activity compared to the sepsis group.

MDH activity is an important marker used to measure the severity of liver diseases (21). However, in our study, there was no difference between the groups in terms of MDH activity.

The results of this study provided convincing evidence that NMN reduces injury and inflammation in liver tissue. These findings suggested that NMN can be used for the sepsis-induced liver injury in septic rats.

5. References

1. Fajgenbaum DC, June CH. Cytokine Storm. New England Journal of Medicine. 2020 Dec 3;383(23):2255–73.

2. Margotti W, Goldim MP de S, Machado RS, Bagio E, Dacoregio C, Bernades G, et al. Oxidative stress in multiple organs after sepsis in elderly rats. Exp Gerontol. 2022 Apr 1;160.

3. Woznica EA, Inglot M, Woznica RK, Lysenko L. Liver dysfunction in sepsis. Advances in Clinical and Experimental Medicine. 2018 Apr 1;27(4):547–51.

4. Virdis A, Colucci R, Fornai M, Blandizzi C, Duranti E, Pinto S, et al. Cyclooxygenase-2 Inhibition Improves Vascular Endothelial Dysfunction in a Rat Model of Endotoxic Shock: Role of Inducible Nitric-Oxide Synthase and Oxidative Stress. Journal of Pharmacology and Experimental Therapeutics. 2005 Mar 1;312(3):945–53.

5. Garrido A, Djouder N. NAD+ Deficits in Age-Related Diseases and Cancer. Trends Cancer. 2017 Aug 1;3(8):593–610.

6. Cros C, Margier M, Cannelle H, Charmetant J, Hulo N, Laganier L, et al. Nicotinamide Mononucleotide Administration Triggers Macrophages Reprogramming and Alleviates Inflammation During Sepsis Induced by Experimental Peritonitis. Front Mol Biosci. 2022 Jun 27;9:576.

7. Kwon WY, Suh GJ, Kim KS, Kwak YH. Niacin attenuates lung inflammation and improves survival during sepsis by downregulating the nuclear factor-κB pathway. Crit Care Med. 2011;39(2):328–34.

8. Hong G, Zheng D, Zhang L, Ni R, Wang G, Fan GC, et al. Administration of nicotinamide riboside prevents oxidative stress and organ injury in sepsis. Free Radic Biol Med. 2018 Aug 1;123:125–37.

9. Wichterman KA, Baue AE, Chaudry IH. Sepsis and septic shock—A review of laboratory models and a proposal. Journal of Surgical Research. 1980 Aug 1;29(2):189–201.

10. Waterborg JH. The Lowry Method for Protein Quantitation. 2009;7–10.

11. Nishikimi M, Appaji Rao N, Yagi K. The occurrence of superoxide anion in the reaction of reduced phenazine methosulfate and molecular oxygen. Biochem Biophys Res Commun. 1972 Jan 31;46(2):849–54.

12. Erdelmeier I, Gérard-Monnier D, Régnard K, Moze-Henry N, Yadan JC, Chaudière J. Reactions of 1-Methyl-2-phenylindole with Malondialdehyde and 4-Hydroxyalkenals. Analytical Applications to a Colorimetric Assay of Lipid Peroxidation. Chem Res Toxicol. 1998;11(10):1176–83.

13. Muftuoglu MAT, Aktekin A, Ozdemir NC, Saglam A. Liver Injury in Sepsis and Abdominal Compartment Syndrome in Rats. Surg Today. 2006;36:519–24.

14. Aboyoussef A, Mohammad M, … AASJ of, 2021 undefined. Granisetron attenuates liver injury and inflammation in a rat model of cecal ligation and puncture-induced sepsis. ElsevierAM Aboyoussef, MK Mohammad, AA Abo-Saif, BAS MessihaJournal of Pharmacological Sciences, 2021

15. Al-Hathlol K, Al-Madani A, … SASS medical, 2006 undefined. Ursodeoxycholic acid therapy for intractable total parenteral nutrition-associated cholestasis in surgical very low birth weight infants. smj.org.sgK Al-Hathlol, A Al-Madani, S Al-Saif, B Abulaimoun, K Al-Tawil, A El-DemerdashSingapore medical journal, 2006•smj.org.sg

16. Badia-Tahull MB, Leiva-Badosa E, Llop-Talaverón J, Figueras-Suriol A, Quirante-Cremades A, Tubau-Molas M, et al. Alteraciones de los parámetros hepáticos asociados con la administración de nutrición parenteral en pacientes adultos hospitalizados: incidencia y factores de riesgo. Nutr Hosp. 2012;27(4):1279–85.

17. Assiri MA, Ali HR, Marentette JO, Yun Y, Liu J, Hirschey MD, et al. Investigating RNA expression profiles altered by nicotinamide mononucleotide therapy in a chronic model of alcoholic liver disease. Hum Genomics. 2019 Dec 10 ;13(1):1–13.

19. Cao T, Ni R, Ding W, Ji X, Fan GC, Zhang Z, et al. Nicotinamide mononucleotide as a therapeutic agent to alleviate multi-organ failure in sepsis. J Transl Med. 2023 Dec 1;21(1).

20. Celep NA, Gedikli S. Protective Effect of Silymarin on Liver in Experimental in the Sepsis Model of Rats. Acta Histochem Cytochem. 2023 Feb 2;56(1):9.

21. Tamber SS, Bansal P, Sharma S, Singh RB, Sharma R. Biomarkers of liver diseases. Mol Biol Rep. 2023 Sep 1;50(9):7815–23.

VITEX AGNUS-CASTUS L. OIL MODULATES TLR EXPRESSION IN SK-UT-1 CELL LINE: A PROMISING THERAPEUTIC AVENUE FOR UTERINE LEIOMYOSARCOMA

SEMİH TAN1, SEÇİL TAN2, CEMRE ZEYNEP HARMAN3

[1] *Ordu University, Faculty of Medicine, Department of Histology & Embriyology, Ordu/TÜRKİYE,* tansemih@hotmail.com

[2] *Pamukkale University, Instıtute of Medicine, Department of Cancer Molecular Biology, Denizli/TÜRKİYE,* secilytan@gmail.com

[3] *Ordu University, Faculty of Medicine, Department of Histology & Embriyology, Ordu/TÜRKİYE,* czharman@hotmail.com

ABSTRACT

Introduction:
Uterine leiomyosarcoma (uLMS) is a highly challenging malignancy with complex diagnostic and therapeutic needs. The SK-UT-1 cell line serves as a critical model for exploring the molecular mechanisms of uLMS and testing treatment options. Toll-like receptors (TLRs) play a key role in immune responses by triggering inflammation. Phytochemicals in Vitex agnus-castus (VAC), known for their antioxidant properties, may influence TLR signaling and inflammatory pathways, potentially impacting cancer progression and immune regulation.
Objective:
This study aims to investigate the therapeutic potential of VAC in uLMS by examining its influence on TLR regulation and related pathways through its phytochemical components.
Materials and Methods:
A VAC oil stock was prepared (48.22% VAC, 1% Tween 20) and diluted 100X. SK-UT-1 cells were treated with concentrations ranging from 1% to 100% of the working stock for 24 hours. The IC50 dose of VAC oil was determined using XTT assay. Cells were treated with the effective dose, followed by RNA isolation. TLR (1-10) and Myd expression were analyzed by qRT-PCR. Data were statistically analyzed using GraphPad Prism ($p \leq 0.05$).
Results and Conclusion:
VAC treatment significantly altered TLR expression in SK-UT-1 cells, increasing TLR2 and TLR6 while decreasing TLR4. This suggests a shift towards reduced tumor-promoting inflammation and enhanced immune response. These findings highlight VAC's potential as a therapeutic agent in uLMS by modulating immune pathways and reducing inflammation.
Keywords: Vitex-agnus castus, TLR, SK-UT-1, essential oil, Leiomyosarcoma

Vitex agnus-castus L. Oil Modulates TLR Expression in SK-UT-1 Cell Line: A Promising Therapeutic Avenue for Uterine Leiomyosarcoma

INTRODUCTION

Vitex agnus-castus L. (VAC), commonly known as chasteberry, has been studied for its potential anticancer properties, particularly through its essential oil and various extracts. The essential oil of VAC is rich in bioactive compounds, including flavonoids, iridoid glycosides, and terpenes, which have been shown to exhibit cytotoxic effects against various cancer cell lines. VAC has been noted for its potential to modulate hormonal levels, which may indirectly influence cancer progression, particularly in hormone-sensitive cancers such as breast cancer. The extract has been shown to affect estrogen and progesterone levels in ovariectomized female rats, suggesting a possible role in managing hormone-related cancers (Mazaro-Costa et al., 2010; Rafieian-Kopaei & Movahedi, 2017). Research indicates that the methanol extract of VAC fruits demonstrates selective antiproliferative activity against murine mammary adenocarcinoma cells while exhibiting lower toxicity towards normal rat embryonic fibroblast cells Ribat et al. (2019). This selective cytotoxicity is crucial for developing potential anticancer agents that target malignant cells while sparing healthy tissues. Additionally, the essential oil has been found to contain compounds such as 1,8-cineole and trans-caryophyllene, which have been associated with cytotoxic effects in various cancer models (Ricarte et al., 2020).

VAC has been explored for its potential therapeutic effects in various gynecological conditions. However, direct research specifically targeting leiomyosarcoma, a rare and aggressive form of cancer arising from smooth muscle tissue, is limited. The existing literature on VAC's biological activities and its effects on hormone regulation provides a foundation for understanding its potential role in cancer treatment. In the context of leiomyosarcoma, the hormonal modulation properties of VAC may also play a significant role. VAC is known to influence estrogen and progesterone levels, which can be particularly relevant in hormone-sensitive tumors. The extract has been shown to bind to estrogen receptors, suggesting that it may exert weak estrogenic effects that could potentially modulate the growth of hormone-responsive tumors (Saul, 2017; Jarry et al., 2003).

The SK-UT-1 cell line, derived from human uterine leiomyosarcoma, is primarily utilized in research related to uterine neoplasms rather than hormone-sensitive cancers. This cell line does not exhibit the characteristics typically associated with hormone-sensitive

cancers, such as responsiveness to estrogen or other hormonal therapies. Studies have shown that SK-UT-1 cells do not express significant levels of estrogen receptors, which are crucial for the development and progression of hormone-sensitive cancers, particularly breast and ovarian cancers (Reader et al., 2019). The role of SK-UT-1 in studying drug resistance and tumor biology is significant, but it does not extend to modeling hormone-sensitive cancers. The cell line's lack of estrogen receptor expression and its classification as a uterine leiomyosarcoma model suggest that it is more suitable for exploring the biology of aggressive sarcomas rather than hormone-dependent tumors (Zhao et al., 2015).

Toll-like receptors (TLRs) are a class of pattern recognition receptors that play a pivotal role in the innate immune system. TLR activation can promote both pro-inflammatory and anti-inflammatory responses, depending on the context and the specific TLR involved. Studies have shown that TLRs can enhance the immune response against tumors by promoting the maturation of dendritic cells and the activation of T cells, which are crucial for effective anti-tumor immunity (Cen et al., 2018; Pradère et al., 2013). Their involvement in cancer biology, including uterine leiomyosarcoma (uLMS), has garnered increasing attention. While the specific role of TLRs in uLMS remains underexplored, there is evidence suggesting that TLR signaling may influence tumor progression and immune response in various cancers, including those of the uterus.

Research indicates that the essential oils and phenolic compounds derived from Vitex agnus-castus exhibit antioxidant properties and may influence inflammatory pathways. For instance, the phenolic components of Vitex agnus-castus have been linked to the modulation of oxidative stress, which is known to affect TLR signaling pathways (Katiraee et al., 2015; Berrani et al., 2021). Moreover, the interaction between Vitex agnus-castus and TLRs may extend to its therapeutic effects in conditions characterized by chronic inflammation. In the context of PMS and PCOS, where inflammation is often a contributing factor, the ability of Vitex agnus-castus to modulate TLR activity could enhance its efficacy as a treatment option (Saul, 2017; Arentz et al., 2014).

The objective of this study is to explore the potential therapeutic effects of Vitex agnus-castus (VAC) in the treatment of uterine leiomyosarcoma (uLMS) by investigating its influence on Toll-like receptor (TLR)-mediated pathways. Specifically, the study aims to evaluate how the bioactive compounds found in VAC, including its essential oils and phenolic components, modulate TLR signaling in the context of cancer progression. By elucidating the role of VAC in regulating TLR activity, this research seeks to expand the understanding of its

potential as an adjunct therapy for uLMS, focusing on both its direct anticancer properties and its ability to modulate the immune microenvironment.

MATERIAL-METHOD

Cell Culture

The SK-UT-1 cell line used in this study was obtained from ATCC (American Type Culture Collection). Cell culture was performed using the Dulbecco's Modified Eagle's Medium (DMEM) (Gibco, USA) in the presence of 10% fetal bovine serum (Capricorn, USA), 1% penicillin (100 U/mL)/ streptomycin (100 µg/mL)(Gibco, USA) in a humidified atmosphere containing 5% CO_2, 37 °C.

Determination of cell viability after VAC treatment

The main VAC stock was prepared by dissolving 950 µl of commercially available VAC oil with 20 µl of Tween 20 and adding 1000 µl of DMEM (48.22% VAC, 1% Tween20). The main stock was diluted 100X with DMEM to prepare working stock solution. SK-UT-1 cells were seeded at 10^4 cells/well in 96-well cell culture plates and exposed to different doses of VAC ranging from %0, 1, 5,10, 25,50 and 100 of working stock solution. After 24h of incubation at 37 °C with 5% CO2, the XTT Cell Viability Assay Kit (ab232856, ABCAM) was used to detect cell viability by adding 10 µL of XTT mixture (5 µL XTT Developer Reagent and 5 µL Electron Mediator Solution) into each well containing 100 µl DMEM medium. The plate was then incubated at 37 °C for 2 h according to the kit protocol before being read at 450 nm with an Elisa microplate reader. This process allowed us to determine IC50 dose for SK-UT-1 cells which were subsequently used throughout further experiments.

Total RNA isolation and cDNA synthesis from cell culture

Cells were seeded into 6 well plates and waited to reach 70% confluence. The determined IC50 VAC dose was given to SK-UT-1 cells and incubated for 24 hours. RNA extraction of SK-UT-1 cells was performed with Total RNA Isolation Kit (Lot: 0622-AK-2284, Hibrigen, TR) according to the manufacturer's instruction. The pellet containing total RNA was quickly dried at room temperature and then dissolved in 30 µL of nuclease-free water, followed by a Nanodrop analysis to determine the amount and quality of the RNA. Subsequently, cDNA synthesis from total RNA was performed using cDNA Synthesis Kit (Lot: NG20210223, NucleoGene, TR) according to its protocol instructions for optimal results.

Determination of gene expressions by RT-PCR

Real-time PCR was performed to measure the mRNA expression levels of Toll-like receptor 1-10 and Myd genes (Table 1). Sequences were designed using the OriGene (https://www.origene.com/) online web page and BLAST (Basic Local Alignment Search Tool (https://blast.ncbi.nlm.nih.gov/Blast.cgi) software. The mRNA level expressions of these target genes were determined in SK-UT-1 cells using qPCR Sybr Green Master Mix kit.(Lot: NG20200515, Nucleogen, TR) following the treatment of VAC. A real-time PCR protocol consisting of one cycle at 95 °C for 15 min and 40 cycles at 95 °C for 15 s, followed by 1 min at 60 °C, was applied. Relative changes in gene expressions were calculated through reference gene (β actin) with the formula $2^{-\Delta\Delta Ct}$ before being analyzed. Each experiment on each group was repeated three times to ensure accuracy and reliability.

Tablo 1 Forward and reverse sequences of primers used in RT-PCR

#	Name	Sequence
1	TLR1_F	CAGCGATGTGTTCGGTTTTCCG
2	TLR1_R	GATGGGCAAAGCATGTGGACCA
3	TLR2_F	TTATCCAGCACACGAATACACAG
4	TLR2_R	AGGCATCTGGTAGAGTCATCAA
5	TLR3_F	GGCTAGCAGTCATCCAACAGAA
6	TLR3_R	GCAGTCAGCAACTTCATGGC
7	TLR4_F	CCCTGAGGCATTTAGGCAGCTA
8	TLR4_R	AGGTAGAGAGGTGGCTTAGGCT
9	TLR5_F	CCTTACAGCGAACCTCATCCAC
10	TLR5_R	TCCACTACAGGAGGAGAAGCGA
11	TLR6_F	TTCTCCGACGGAAATGAATTTGC
12	TLR6_R	CAGCGGTAGGTCTTTTGGAAC
13	TLR7_F	CTTTGGACCTCAGCCACAACCA
14	TLR7_R	CGCAACTGGAAGGCATCTTGTAG
15	TLR8_F	ACTCCAGCAGTTTCCTCGTCTC
16	TLR8_R	AAAGCCAGAGGGTAGGTGGGAA
17	TLR9_F	TGAGCCACAACTGCATCTCGCA
18	TLR9_R	CAGTCGTGGTAGCTCCGTGAAT

19	TLR10_F	GGTTAAAAGACGTTCATCTCCACG
20	TLR10_R	CCTAGCATCCTGAGATACCAGG
21	MyD88_F	GAGGCTGAGAAGCCTTTACAGG
22	MyD88_R	GCAGATGAAGGCATCGAAACGC

Statistical analysis of results

The data were analyzed with GraphPad package program. Continuous variables were expressed as the mean ± standard error (SE). The conformity of the data to the normal distribution was examined using the Shapiro–Wilk tests. When parametric test assumptions were provided, "Independent Samples *T* test" were used to compare groups. When parametric test assumptions were not provided, Mann Whitney *U* test was used to compare groups. In all analyzes, $p < 0.05$ was considered statistically significant.

RESULTS AND CONCLUSION

Cell Viability Assay Results

The VAC dose that inhibits SK-UT-1 cell viability by 50% was calculated as 4% concentration of the working stock solution (Figure 1). XTT analysis results reveal the effect of VAC oil on SK-UT-1 viability. The IC50 dose found was selected as the dose to be used in further studies.

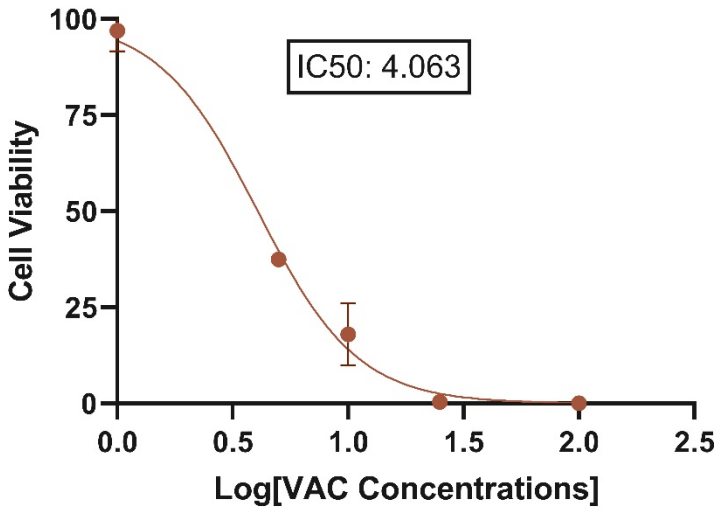

Figure 3 XTT analysis results

VAC oil altered the expression of TLR in SK-UT-1 cells

RT-PCR analyses showed significant changes in the mRNA levels of myeloid differentiation primary response 88 (MYD88) and TLR 1-10 genes in SK-UT-1 cells treated with VAC. Expression of Myd88, TLR3, TLR5, TLR9 and TLR10 was not observed in the control group and treatment group in SK-UT-1 cells. No significant changes were observed in TLR1, TRL7 and TLR8 expression compared to the control group. In the treatment group, TLR2 (1.6-fold) and TLR6 (2.9-fold) were significantly increased compared to the control group, while TLR4 (0.4-fold) expression was decreased (Figure 2).

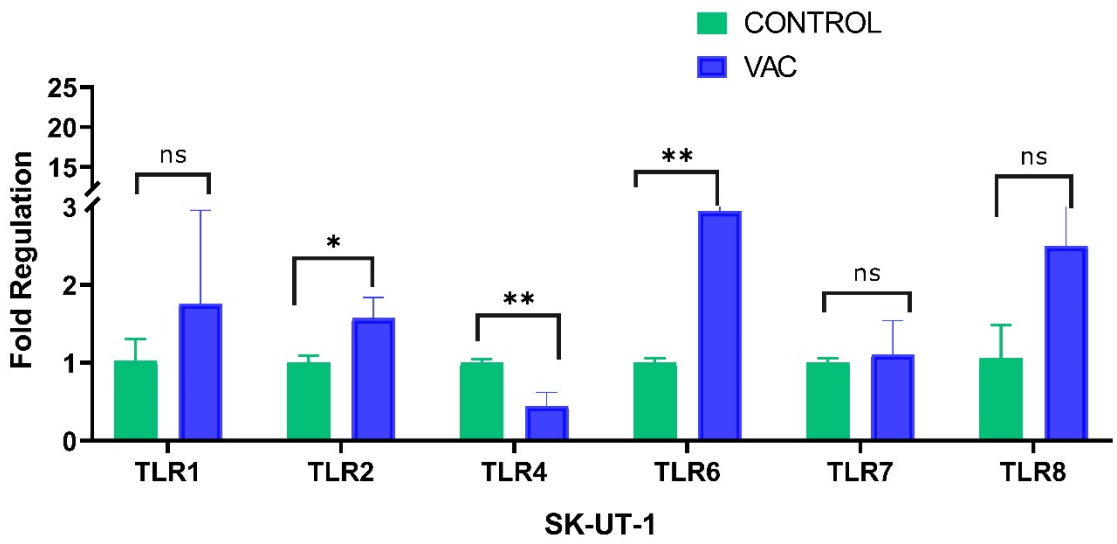

Figure 4 Fold change graph of related genes

The methanol extract of Vitex agnus-castus fruits exhibits antiproliferative activity against cancer cell lines, which is often linked to its ability to reduce inflammation within the tumor microenvironment (Ribat et al., 2019). The flavonoids present in Vitex agnus-castus, such as apigenin, have been identified as key components that exert anti-inflammatory effects by inhibiting the production of pro-inflammatory mediators (Sehmisch et al., 2008). These compounds can modulate signaling pathways associated with inflammation, thereby reducing the expression of inflammatory markers and contributing to the overall therapeutic effects of the herb (Kavaz et al., 2022).

TLR2 and TLR6 often form a heterodimer that recognizes a broad range of ligands, including bacterial components like lipoproteins and peptidoglycan, as well as endogenous ligands released from damaged or dying cells (Akira et al., 2004). An increase in TLR2 and TLR6 might suggest the tumor or surrounding environment is undergoing stress or cell damage (possibly due to the VAC treatment), releasing damage-associated molecular patterns (DAMPs) that trigger these receptors. The VAC treatment may be inducing changes in the tumor or its microenvironment that are more easily detected by TLR2/6, suggesting a shift toward a different immune recognition pathway. TLR4 is most commonly known for recognizing bacterial lipopolysaccharide (LPS), but it also responds to DAMPs (Perrin-Cocon et al., 2017; Nakatomi et al., 2020). The decrease in TLR4 expression could indicate that the VAC treatment is reducing a pro-inflammatory environment that previously supported tumor progression. TLR4 can sometimes promote tumor survival through inflammatory signaling pathways (like NF-κB and cytokine release), so a reduction may signify a less favorable environment for tumor growth (Maroso et al., 2010; Lin et al., 2013). The changes in TLR expression might reflect how the tumor microenvironment is responding to therapy. Upregulated TLR2 and TLR6 could signal an ongoing immune response, while reduced TLR4 might reflect a decrease in tumor-promoting inflammation.

This expression pattern might suggest a therapeutic response where the tumor environment is becoming less supportive of tumor growth (via decreased TLR4-mediated inflammation) while engaging alternative immune recognition pathways (via TLR2/6). This shift could be part of a process aimed at increasing tumor cell clearance and reducing tumor-promoting inflammation.

REFERENCES

Mazaro-Costa, R., Andersen, M., Hachul, H., & Tufik, S. (2010). Medicinal plants as alternative treatments for female sexual dysfunction: utopian vision or possible treatment in climacteric women?. Journal of Sexual Medicine, 7(11), 3695-3714. https://doi.org/10.1111/j.1743-6109.2010.01987.x

Rafieian-Kopaei, M. and Movahedi, M. (2017). Systematic review of premenstrual, postmenstrual and infertility disorders of vitex agnus castus. Electronic Physician, 9(1), 3685-3689. https://doi.org/10.19082/3685

Ribat, Z., Sahib, H., Khamees, A., & Al-Shammari, A. (2019). Effect of vitex agnus castus fruits methanol extract against murine mammary adenocarcinoma cell line (amn3) and rat embryonic fibroblast normal cell line (ref). International Journal of Research in Pharmaceutical Sciences, 10(3). https://doi.org/10.26452/ijrps.v10i3.1393

Ricarte, L., Bezerra, G., Romero, N., Silva, H., Lemos, T., Arriaga, Â., … & Santiago, G. (2020). Chemical composition and biological activities of the essential oils from vitex-agnus castus, ocimum campechianum and ocimum carnosum. Anais Da Academia Brasileira De Ciências, 92(1). https://doi.org/10.1590/0001-3765202020180569

Jarry, H., Spengler, B., Porzel, A., Schmidt, J., Wuttke, W., & Christoffel, V. (2003). Evidence for estrogen receptor β-selective activity ofvitex agnus-castusand isolated flavones. Planta Medica, 69(10), 945-947. https://doi.org/10.1055/s-2003-45105

Saul, S. (2017). Effects of vitex agnes castus on hormonal imbalances in polycystic ovary syndrome. International Journal of Basic & Clinical Pharmacology, 6(8), 2051. https://doi.org/10.18203/2319-2003.ijbcp20173295

Reader, J., Harper, A., Legesse, T., Staats, P., Goloubeva, O., Rao, G., … & Roque, D. (2019). Ep4 and class iii β-tubulin expression in uterine smooth muscle tumors: implications for prognosis and treatment. Cancers, 11(10), 1590. https://doi.org/10.3390/cancers11101590

Zhao, Y., Lützen, U., Fritsch, J., Zuhayra, M., Schütze, S., Steckelings, U., … & Čulman, J. (2015). Activation of intracellular angiotensin at2 receptors induces rapid cell death in human uterine leiomyosarcoma cells. Clinical Science, 128(9), 567-578. https://doi.org/10.1042/cs20140627

Cen, X., Liu, S., & Cheng, K. (2018). The role of toll-like receptor in inflammation and tumor immunity. Frontiers in Pharmacology, 9. https://doi.org/10.3389/fphar.2018.00878

Pradère, J., Dapito, D., & Schwabe, R. (2013). The yin and yang of toll-like receptors in cancer. Oncogene, 33(27), 3485-3495. https://doi.org/10.1038/onc.2013.302

Katiraee, F., Mahmoudi, R., Tahapour, K., Hamidian, G., & Emami, S. (2015). Biological properties of vitex agnus-castus essential oil (phytochemical component, antioxidant and antifungal activity). Biotechnology and Health Sciences, 2(2). https://doi.org/10.17795/bhs-26797

Berrani, A., Marmouzi, I., Bouyahya, A., Kharbach, M., Hamdani, M., Jemli, M., … & Bengueddour, R. (2021). Phenolic compound analysis and pharmacological screening of vitex agnus-castus functional parts. Biomed Research International, 2021, 1-10. https://doi.org/10.1155/2021/6695311

Saul, S. (2017). Effects of vitex agnes castus on hormonal imbalances in polycystic ovary syndrome. International Journal of Basic & Clinical Pharmacology, 6(8), 2051. https://doi.org/10.18203/2319-2003.ijbcp20173295

Arentz, S., Abbott, J., Smith, C., & Bensoussan, A. (2014). Herbal medicine for the management of polycystic ovary syndrome (pcos) and associated oligo/amenorrhoea and hyperandrogenism; a review of the laboratory evidence for effects with corroborative clinical findings. BMC Complementary and Alternative Medicine, 14(1). https://doi.org/10.1186/1472-6882-14-511

Ribat, Z., Sahib, H., Khamees, A., & Al-Shammari, A. (2019). Effect of vitex agnus castus fruits methanol extract against murine mammary adenocarcinoma cell line (amn3) and rat embryonic fibroblast normal cell line (ref). International Journal of Research in Pharmaceutical Sciences, 10(3). https://doi.org/10.26452/ijrps.v10i3.1393

Sehmisch, S., Boeckhoff, J., Wille, J., Seidlová-Wuttke, D., Rack, T., Tezval, M., … & Stuermer, K. (2008). vitex agnus castus as prophylaxis for osteopenia after orchidectomy in rats compared with estradiol and testosterone supplementation. Phytotherapy Research, 23(6), 851-858. https://doi.org/10.1002/ptr.2711

Kavaz, A., Işık, M., Dikici, E., & Yüksel, M. (2022). Anticholinergic, antioxidant, and antibacterial properties of vitex agnus-castus l. seed extract: assessment of its phenolic content by lc/ms/ms. Chemistry & Biodiversity, 19(10). https://doi.org/10.1002/cbdv.202200143

Akira, S., Takeda, K. Toll-like receptor signalling. Nat Rev Immunol 4, 499–511 (2004). https://doi.org/10.1038/nri1391

Perrin-Cocon, L., Aublin-Gex, A., Sestito, S. et al. TLR4 antagonist FP7 inhibits LPS-induced cytokine production and glycolytic reprogramming in dendritic cells, and protects mice from lethal influenza infection. Sci Rep 7, 40791 (2017). https://doi.org/10.1038/srep40791

Nakatomi, K., Ueno, H., Ishikawa, Y., Salim, R. C., Mori, Y., Kanemoto, I., Tancharoen, S., Kikuchi, K., Miura, N., Omori, T., Okuda-Ashitaka, E., Matsumura, K., Imaizumi, H., Motomiya, Y., Maruyama, I., & Kawahara, K. I. (2021). TLR4/MD-2 is a receptor for extracellular nucleophosmin 1. Biomedical reports, 14(2), 21. https://doi.org/10.3892/br.2020.1397

Maroso, M., Balosso, S., Ravizza, T., Liu, J., Aronica, E., Iyer, A., … & Vezzani, A. (2010). Toll-like receptor 4 and high-mobility group box-1 are involved in ictogenesis and can be targeted to reduce seizures. Nature Medicine, 16(4), 413-419. https://doi.org/10.1038/nm.2127

Lin, M., Yiu, W., Li, R., Wu, H., Wong, D., Chan, L., … & Tang, S. (2013). The tlr4 antagonist crx-526 protects against advanced diabetic nephropathy. Kidney International, 83(5), 887-900. https://doi.org/10.1038/ki.2013.11

INVESTIGATION OF THE EFFECT OF ELECTROMAGNETIC FIELD EXPOSURE ON CATSPER GENE EXPRESSION LEVELS

ADEM KOCAMAN[1], BÜLENT AYAS1[2],

1Ondokuz Mayıs University, Faculty of Medicine, Department of Histology and Embryology Samsun, Türkiye, adem.kocaman@omu.edu.tr

2Ondokuz Mayıs University, Faculty of Medicine, IVF Unit, Samsun, Türkiye, ayasb@omu.edu.tr

Abstract

Male infertility is directly related to sperm motility, morphology and sperm count. The most important factors affecting sperm motility are the activation of calcium channels and the mitochondria having sufficient energy supply for energy production. CatSper channels have an important role in the hyperactive state of sperm. The electromagnetic field (EMF) emitted by the mobile phones carried close to the waist area may affect the reproductive organs and have an effect on the sperms that gain mobility with the activation of calcium channels. Although it has been reported in many studies that EMF affects sperm parameters, no enlightening information has been presented at the molecular level. In this study, 50 adult (60 days old) Wistar albino male rats weighing 180-200 g were used and the experimental group was exposed to 2100 MHz EMF for 28 days. In order to determine the possible effects of EMF, calcium channel blocker was also administered in the experimental groups. Total RNA was isolated from the isolated sperm samples and Catsper 1, 2, 3, 4 gene expression analysis was analyzed. In conclusion, it can be suggested that EMF may have an effect on sperm. This effect may increase exponentially as a result of increasing the duration and frequency of exposure to EMF. Therefore, it is important to take necessary precautions and measures against exposure to EMF in daily life and to protect against possible harmful effects.

Keywords: CatSper, electromagnetic field, infertility, sperm.

Introduction

Communication technologies, which provide concrete solutions to the needs arising from globalization, have also become one of the main sources of global pollution by posing a threat to the environment and human life (1). With the widespread use of electrical devices today, electromagnetic field (EMF) has become an important global phenomenon that causes concern in many people (2, 3). In addition to natural sources of EMF, living organisms are exposed to EMF from mobile phones, cell phone base stations, radio stations, computer screens and many other electrical devices commonly used in daily life (4). One of the widely voiced concerns is the discourse and findings that EMF causes infertility. Male patients undergoing infertility treatment are often advised that cell phones and laptops should be used away from the reproductive organs.

Since Ca^{+2} signal transduction plays an important role in cellular functions, under normal conditions cytosolic Ca^{+2} is carefully controlled by membrane calcium channels and intracellular calcium dynamics (5, 6). Dysfunctions of calcium channels or intracellular calcium dynamics may play a role in the pathogenesis of many diseases by disrupting calcium homeostasis (7, 8). The regulatory mechanisms controlling calcium homeostasis are influenced by a number of environmental factors. Among these environmental factors, the presence of ionizing and microwave radiation has attracted scientific attention and encouraged the investigation of the effect of EMF on Ca^{+2} channels. The effect of EMF exposure on calcium ion gating in voltage-dependent calcium channels (VGCC) was investigated using Brownian Dynamics and Finite Element methods. Simulation results showed that EMF increased calcium channel conductance and consequently increased the current of calcium ions (9). VGCC activation and thus the increase in the amount of Ca^{+2} in the cell after EMA exposure has been shown in many studies in living organisms (10, 11, 12, 13).

Ca^{+2} signaling is crucial for successful fertilization. In spermatozoa, an increase in intracellular Ca^{+2} through CatSper (sperm-specific cation channel) results in capacitation, hyperactivation of motility and triggering of the acrosome reaction. The CatSper channel complex consists of four main α-subunits (CatSper1-4) and five subunits. In rats, mutation in any of the four CatSper genes leads to loss of hyperactive motility and male infertility. Despite its vital role in male fertility, little is known about the influence of the EMF in the epididymis and epididymal spermatozoa on CatSper gene expression, channel activity and sperm motility.

A limited number of studies conducted in recent years have revealed the effects of EMF on male infertility. It is thought that EMF may have an effect on sperm motility by

activating calcium channels. The increase in sperm intracellular calcium through the CatSper channel results in capacitation, hyperactivation of motility and triggering of the acrosome reaction. Despite its crucial role in male fertility, little is known about the effect of EMF on CatSper gene expression and sperm motility. In this study, we aimed to investigate the possible effects of EMF on Casper gene expression levels.

Material and Method

Fifty adult (60 days) Wistar albino male rats weighing 180-200 g were included in the study. In the EMF group, EMF at 2100 MHz level was applied for 1 hour daily at the same time every day for 28 days. In the positive control group, amlodipine, a calcium channel blocker (CCB), was administered 1 mg/kg/day by gavage for 28 days. Control, Sham, EMF, EMF+CCB, and CCB groups were formed with 10 subjects in each group.

Total ribonucleic acid (RNA) isolation was performed using the RNeasy Mini Kit, a commercially available kit designed for low levels of RNA (Qiagen, Germany). Before each isolation procedure, work tables and materials were cleaned to prevent RNase contamination. To avoid exceeding the RNA binding capacity of the kit to be used, care was taken to ensure that the number of cells in the sample did not exceed $5x10^6$ cells. Total RNA isolation was carried out following the protocol recommended by the kit with modifications determined in the pilot study. All samples obtained from the subjects were subjected to the isolation protocol without freezing or holding.

The isolated 40 µl volume of total RNA was converted into cDNA. At this stage, cDNA synthesis from single-stranded RNA was performed using the commercially available Quantitect Reverse Transcription Kit (Qiagen, Germany). For each RNA sample in 14 µl volume after genomic DNA elimination, a reverse transcription reaction was performed using a master mix prepared from 1 µl Quantiscript Reverse Transcriptase, 4 µl Quantiscript RT buffer and 1 µl RT Primer Mix. The concentrations of the samples converted to cDNA were converted into quantitative data with NanoDrop 2000® (NanoDrop Technologies, Wilmington, DE, USA).

qRT-PCR was performed using the QuantiTect SYBR Green PCR Kit (Qiagen, Germany) according to the recommended protocol (Table 1 and 2). The primers of the genes to be used in the study were designed using the NCBI primer BLAST program (http://www.ncbi.nlm.nih.gov/tools/primer-blast/).

Table 1. qRT-PCR reaction preparation protocol.

Reaction components	Volume
2xQuantitect SYBR Green PCR Master Mix	25 µl
Forward primer (10 µM)	1.5 µl
Reverse primer (10 µM)	1.5 µl
cDNA (300 ng)	3 µl
RNase free water	19 µl
Total volume	50 µl

Table 2. qRT-PCR cycling conditions.

Steps	Duration	Temperature	
Enzyme activation	15 min.	95°C	
Denaturation	15 sec.	94°C	
Annealing	30 sec.	60°C	40 cycles
Elongation	30 sec.	72°C	
Melting curve	25 measurements at each degree	65-95°C	

The Ct values of the Gapdh gene, which was used as an internal control gene in gene expression analysis, were accepted as reference Ct values and the values of other gene expressions were normalized. Calculations were performed using the delta-delta Ct method ($2^{-\Delta\Delta Ct}$), which is a comparative Ct method (14). Mean Ct values of the reference and target genes in the experimental and control groups were calculated.

Results

A comparison of gene expression rates between the groups revealed a 3.4-fold increase in Catsper1 gene, a 7-fold increase in Catsper2 gene, a 2-fold increase in Catsper3 gene, and a 0.6-fold increase in Catsper4 gene in the EMF group compared to the control group. In addition, the expression levels of Catsper gene, a calcium channel protein, increased in the EMF+CCB and CCB groups compared to the control group.

Discussion

EMF may act on sperm intracellular calcium levels through calcium channel proteins. Changes in intracellular calcium levels may have implications on sperm motility. The increase in Catsper gene expression levels may have occurred to compensate for possible functional impairments caused by EMF exposure. Similarly, the proportional increase in Catsper gene expression levels was also observed in the CCB group. CatSper proteins with

reduced functionality as a result of CCB administration may cause disruption of intracellular balance. This suggests that the increase in gene expression levels may have occurred in order to synthesize more protein subunits with reduced functionality.

The effects of EMF on the quality of sperm parameters according to the way of carrying a mobile phone were studied by Kilgallon and Simmons on a sample of 52 men aged 18-35 years. The results of the study showed that men who carried their mobile phones in their pockets or on their waist belt had lower sperm concentrations than men who did not carry mobile phones or carried them elsewhere (15). In another study, it was reported that men who carried mobile phones in their pants pockets had a lower percentage of sperm motility, although not statistically significant, compared to men who carried their mobile phones in their waistband, shirt pocket or hands (16). Agarwal et al. (2009) reported that carrying a mobile phone in a pants pocket while in talk mode may negatively affect sperm and impair male fertility (17).

Several other studies on mammalian sperm cells have shown that EMF may have a positive or negative effect on sperm motility. It was emphasized that this effect may depend on the characteristics of the applied EMF and the type of sperm used (18, 19, 20). Bernabo et al. (2007) observed decreased sperm motility after applying EMF to mammalian sperm for 1 hour. When the cells were co-incubated with solubilized zona pellucida, a moderate reactivity was observed and a decrease in oocyte penetration ability was also detected. Furthermore, after 2 or 4 hours of incubation, signs of morphological damage at the plasma membrane and acrosomal level appeared (18). The results of this study suggest that prolonged exposure to EMF may have adverse effects on mammalian fertility and reproduction. In our study, a relative decrease in parameters related to sperm motility was observed as a result of exposure to EMF and it is hypothesized that long-term exposure to EMF may increase the degree of this effect.

In conclusion, EMF may affect sperm intracellular calcium levels. Changes in intracellular calcium levels may have repercussions on sperm motility. Relative changes in the level of gene expression in sperm calcium channels may have resulted from these effects. Given that humans may be exposed to EMF for long periods of time, it can be argued that the study findings will reveal exponentially different effects in the long term. It is important for asthenozoospermic individuals diagnosed with infertility related to sperm motility to consider the possible effects of EMF on intracellular calcium levels. It is recommended to be careful and take necessary precautions against possible EMF exposures that may affect the sperm motility parameter, which sperm cells cannot fully replace.

Funding

This project is supported by TÜBİTAK 1002 program.Project number: 219S265

Conflict of interest

None.

References

Milner A, McClure R, De Leo D. (2012). Globalization and suicide: an ecological study across five regions of the World. Arch Suicide Res.,16(3):238-49.

Miclaus S, Calota V. (2010). In Situ Radiofrequency Field Level Assessment in Two Urban Areas in Romania: Open Questions to Electromagnetic Pollution. Environ Eng Manag J., 9(5):713-9.

Stather JW. (1997). Epidemiological studies concerned with exposure to extremely low frequency electromagnetic fields and the risk of cancer. Radiat Prot Dosim., 72(3-4):291-303.

Berg G. (1992). Effect of artificial electromagnetic fields on living organisms. Gematol Transfuziol., 37(4):28.

Mills LR. (1991). Neuron-Specific and State-Specific Differences in Calcium Regulation - Their Role in the Development of Neuronal Architecture. Ann N Y Acad Sci., 639:312-24.

Ross WN. (1989). Changes in Intracellular Calcium during Neuron Activity. Annu Rev Physiol., 51:491-506.

Small DH. (2009). Dysregulation of Calcium Homeostasis in Alzheimer's Disease. Neurochem Res., 34(10):1824-9.

Supnet C, Bezprozvanny I. (2010). The dysregulation of intracellular calcium in Alzheimer disease. Cell Calcium., 47(2):183-9.

Tekieh T, Sasanpour P, Rafii-Tabar H. (2016). Effects of electromagnetic field exposure on conduction and concentration of voltage gated calcium channels: A Brownian dynamics study. Brain Res., 1646:560-9.

Barbier E, Dufy B, Veyret B. (1996). Stimulation of Ca2+ influx in rat pituitary cells under exposure to a 50 Hz magnetic field. Bioelectromagnetics., 17(4):303-11.

Hojevik P, Sandblom J, Galt S, Hamnerius Y. (1995). Ca2+ Ion-Transport through Patch-Clamped Cells Exposed to Magnetic-Fields. Bioelectromagnetics., 16(1):33-40.

Rao VS, Titushkin IA, Moros EG, Pickard WF, Thatte HS, Cho MR. (2008). Nonthermal effects of radiofrequency-field exposure on calcium dynamics in stem cell-derived neuronal cells: Elucidation of calcium pathways. Radiat Res., 169(3):319-29.

Pall ML. (2013). Electromagnetic fields act via activation of voltage-gated calcium channels to produce beneficial or adverse effects. J Cell Mol Med., 17(8):958-65.

Livak KJ, Schmittgen TD. (2001). Analysis of relative gene expression data using real-time quantitative PCR and the 2(-Delta Delta C(T)) Method. Methods. , 25(4):402-8.

Kilgallon SJ, Simmons LW. (2005). Image content influences men's semen quality. Biol Lett., 22;1(3):253-5.

El-Helaly M, Mansour M. (2014). Cell phone usage and semen quality, hospital based study. Sch J Appl Med Sci., 2:1978-82.

Agarwal A, Deepinder F, Sharma RK, Ranga G, Li JB. (2008). Effect of cell phone usage on semen analysis in men attending infertility clinic: An observational study. Fertil Steril., 89(1):124-8.

Bernabò N, Tettamanti E, Pistilli MG, Nardinocchi D, Berardinelli P, Mattioli M. (2007). Effects of 50Hz extremely low frequency magnetic field on the morphology and function of boar spermatozoa capacitated in vitro. Theriogenology., 67:801-15.

Iorio R, Scrimaglio R, Rantucci E, Monache SD, Di Gaetano A, Finetti N. (2007). A preliminary study of oscillating electromagnetic field effects on human spermatozoon motility. Bioelectromagnetics., 28:72-5.

Iorio R, Delle Monache S, Bennato F, Di Bartolomeo C, Scrimaglio R, Cinque B. (2011). Involvement of mitochondrial activity in mediating ELF-EMF stimulatory effect on human sperm motility. Bioelectromagnetics., 32:15-27.

EXPLORING THE THERAPEUTIC POTENTIAL OF MATCHA TEA IN NEUROBLASTOMA: IMPACT ON GAP43 AND MAP2 EXPRESSION

HATİCE HANCI[1], SEMİH TAN[2], SEÇİL TAN[3], CEMRE ZEYNEP HARMAN[4]

1 Ordu University, Faculty of Medicine, Department of Histology & Embriyology, Ordu/TÜRKİYE, haticehancii@gmail.com

2 Ordu University, Faculty of Medicine, Department of Histology & Embriyology, Ordu/TÜRKİYE, tansemih@hotmail.com

3 Pamukkale University, Institute of Medicine, Department of Cancer Molecular Biology, Denizli/ TÜRKİYE, secilytan@gmail.com

4 Ordu University, Faculty of Medicine, Department of Histology & Embriyology, Ordu/TÜRKİYE, czharman@hotmail.com

ABSTRACT

Introduction:
Matcha tea, derived from finely ground Camellia sinensis leaves, is known for its health benefits, especially in cancer therapy. Its cultivation enhances bioactive compounds like catechins, particularly epigallocatechin gallate (EGCG), which has strong antioxidant and anti-cancer properties. GAP43 (Growth-Associated Protein 43) and MAP2 (Microtubule-Associated Protein 2) are essential for neural development, with GAP43 playing a role in neuronal growth and MAP2 supporting microtubule assembly. In neuroblastoma, their interaction is crucial for understanding tumor differentiation and therapy responses.

Objective:
This study investigates the therapeutic potential of Matcha tea in neuroblastoma, focusing on its antioxidant content and its effects on GAP43 and MAP2 expression.

Materials and Methods:
SH-SY5Y neuroblastoma cells were treated with a solution of 1 g Matcha tea in 10 ml distilled water. Cells at 70% confluency were incubated with the solution for 24 hours. Immunocytochemistry (ICC) was performed to analyze GAP43 and MAP2 expression, and results were evaluated using ImageJ software.

Results and Conclusion:
ICC analysis showed a significant reduction in GAP43 and MAP2 expression after Matcha tea treatment. GAP43 is linked to tumor progression and invasiveness, while MAP2 is a marker of neuronal differentiation. The interplay between these proteins is critical in neural cancers, offering potential therapeutic insights and targets for neuroblastoma treatment.

Keywords: Matcha tea, Neuroblastoma, SH-SY5Y, GAP43, MAP2

Exploring the Therapeutic Potential of Matcha Tea in Neuroblastoma: Impact on GAP43 and MAP2 Expression

INTRODUCTION

Matcha tea (MT), derived from the finely ground leaves of *Camellia sinensis*, has attracted considerable attention for its health benefits, particularly in the context of cancer therapy. The unique cultivation process of matcha enhances its bioactive compounds, especially catechins, which are recognized for their potent antioxidant properties. Among these, epigallocatechin gallate (EGCG) is the most extensively studied due to its significant anti-cancer effects (Jakubczyk et al., 2020; Zhang et al., 2012). Research indicates that EGCG can inhibit tumor growth and induce apoptosis in various cancer cell lines, suggesting a potential role in cancer prevention and therapy (Zhang et al., 2012). The antioxidant capacity of matcha is notably higher than that of other green teas, which is attributed to its specific processing methods that preserve these beneficial compounds (Jakubczyk et al., 2020; Herrera et al., 2022).

In addition to its antioxidant properties, MT has been linked to metabolic health benefits, including weight management and glucose regulation. Studies have shown that matcha can significantly lower blood glucose levels and improve lipid metabolism, which may be beneficial for individuals with obesity or metabolic disorders (El-Kholie al., 2022; Wang et al., 2022). For instance, a study demonstrated that a 6% MT solution led to a notable decrease in glucose levels in a high-fat diet model (El-Kholie et al., 2022). Furthermore, matcha's ability to modulate inflammatory markers, such as IL-6, has been explored, although results have varied across studies (El-Elimat et al., 2022; Wang et al., 2022). This suggests that while matcha may have anti-inflammatory effects, further research is needed to clarify its impact on specific cytokines and overall inflammation.

The interaction of matcha's bioactive compounds with neural development proteins, such as GAP43 and MAP2, provides an intriguing avenue for research, particularly in the context of neuroblastoma. GAP43 plays a crucial role in neuronal growth and pathfinding, while MAP2 is essential for microtubule stability and neurogenesis (Zhang et al., 2012). Their expression levels can serve as prognostic markers in neuroblastoma, potentially guiding therapeutic strategies (Zhang et al., 2012). The modulation of these proteins by compounds found in matcha, particularly EGCG, could offer insights into novel treatment approaches for neuroblastoma and other cancers, highlighting the importance of further investigation into the neuroprotective and anti-cancer properties of matcha (Sasagawa et al., 2021; Zhang et al., 2012).

MT represents a promising functional food with potential health benefits, particularly in cancer therapy and metabolic health. Its rich composition of catechins, especially EGCG, contributes to its antioxidant and anti-inflammatory properties, while its effects on neural development proteins like GAP43 and MAP2 open new research pathways in cancer treatment. Continued exploration of matcha's bioactive compounds and their mechanisms of action will be essential in establishing its role in health and disease management.

MATERIAL-METHOD

Cell Culture

The SH-SY5Y cell line used in this study was obtained from ATCC (American Type Culture Collection). Cell culture was performed using the Dulbecco's Modified Eagle's Medium (DMEM) (Gibco, USA) in the presence of 10% fetal bovine serum (Capricorn, USA), 1% penicillin (100 U/mL)/ streptomycin (100 µg/mL)(Gibco, USA) in a humidified atmosphere containing 5% CO_2, 37 °C.

Preparation Of MT And İts Application To Cells

The MT dose was selected based on existing literature (Dickson et al., 2020). A solution of 1 g MT in 10 ml distilled water was stirred at 70°C for 1 hour, then sterilized using a 0.22 µm filter. A 50 µl aliquot of this solution was mixed with 450 µl DMEM and applied to cells at 70% confluency in 12-well plates, followed by 24 hours of incubation.

Evaluation Of GAP43 And MAP2 Expression Changes By İmmunocytochemical Analysis

The following protocol was applied for immunocytochemical staining of SH-SY5y cells.

- Cells were fixed with pure methanol by incubating 10m at -20°C
- Wash the cells 3 times with PBS
- Block the cells by incubating cells 2h at room temperature in the blocking buffer
- Incubate the samples in the 1/400 diluted GAP43 and MAP2 primary antibodies, overnight at 4°C.
- Wash the slides three times with PBS
- Incubate the samples in the seconder antibody for 1 h at room temperature.
- Wash the slides three times with PBS

- Countersatain the cells with DAB at room temperature until the desired color is observed.
- Wash the slides three times with PBS
- Background staining was done with hematoxylin by waiting at room temperature for 15 min.
- Samples covered with PBS and placed directly under inverted microscope.

For ICC staining, cells were stained in 6 wells in three repetitions as control and treatment groups. After ICC staining, photographs were taken from 50 systematically randomly selected areas from each well and immunohistochemical evaluation was performed using the ImageJ Color deconvolution tool. The measurements were evaluated with the Mann-Whitney test using the Graphpad Prism package program. $P<0.05$ was accepted as the significance level in the results.

RESULTS AND CONCLUSION

ICC analysis revealed a significant reduction in GAP43 (Figure 1) and MAP2 (Figure 2) expression (Figure 3). In the evaluation made after staining, it was also seen that there was a decrease in the number of neurites in the MT groups(Figure 1).

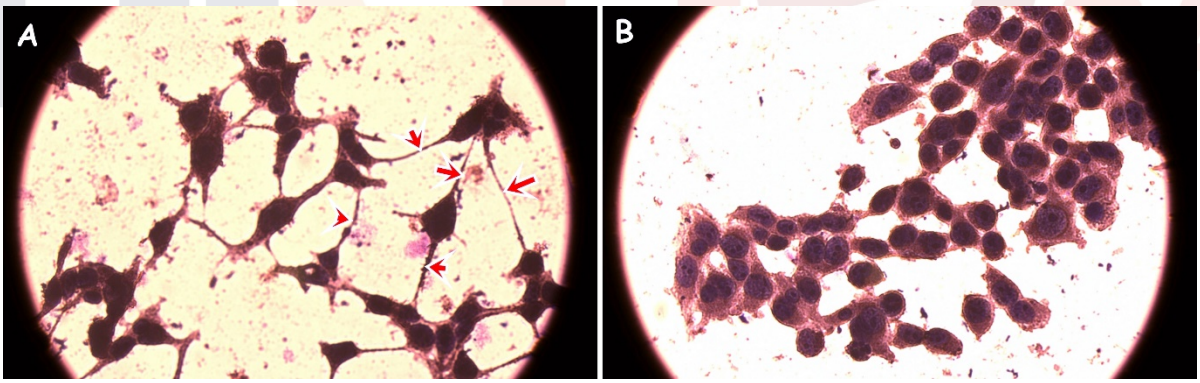

Figure 5 GAP 43 ICC staining of SH-SY5Y cells. Magnification 400x A) Kontrol group B) MT group. Arrows show neurites.

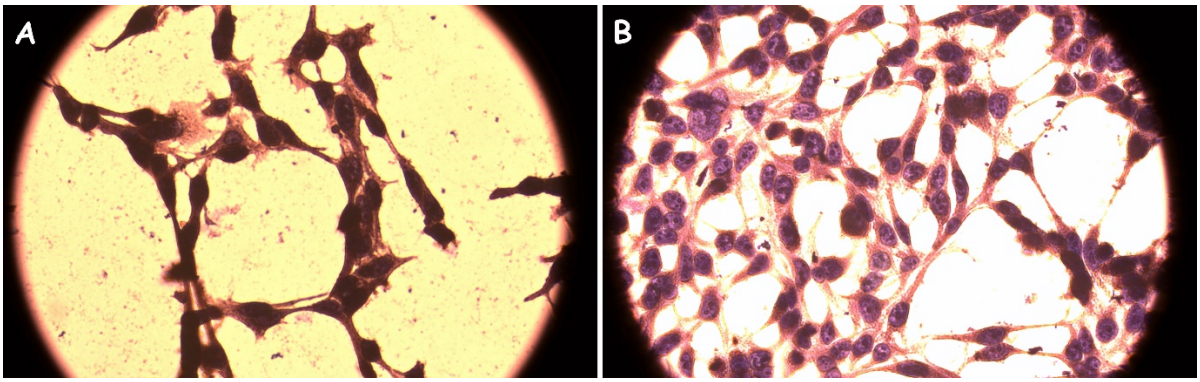

Figure 6 MAP 2 ICC staining of SH-SY5Y cells. Magnification 400x A) Kontrol group B) MT group.

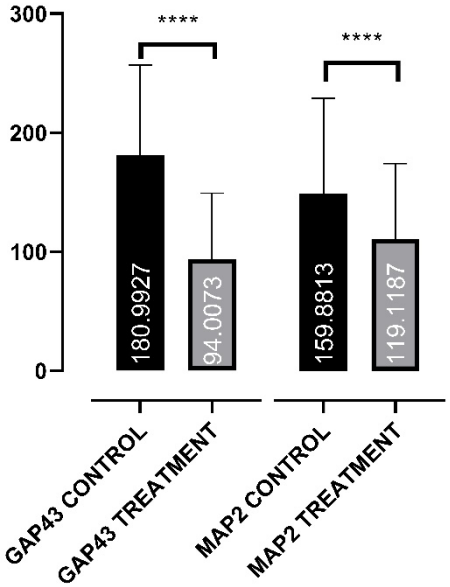

Figure 7 Ranks plot: Mann-Whitney test of GAP43 and MAP2

Neurite outgrowth is a crucial process in both normal neuronal development and in neuroblastoma, a pediatric cancer characterized by the proliferation of neuroblasts. The expression of specific proteins, such as Growth Associated Protein 43 (GAP43) and Microtubule-Associated Protein 2 (MAP2), plays a significant role in regulating neurite morphology and growth in these contexts. In normal neurons, GAP43 is a well-established marker of neuronal growth and plasticity. It is primarily expressed in the growth cones of developing neurons and is involved in promoting neurite outgrowth and synaptic plasticity Banks et al. (2017). GAP43 facilitates the assembly of the cytoskeleton, particularly by influencing actin dynamics, which is essential for the extension and stabilization of neurites

(Jansen et al., 2021). Studies have shown that increased GAP43 expression correlates with enhanced neurite branching and elongation, indicating its critical role in neuronal development (Баранов et al., 2018). Additionally, MAP2 is another important protein that stabilizes microtubules in dendrites, contributing to the structural integrity required for proper neurite formation (Yu et al., 2015). The balance between GAP43 and MAP2 expression is crucial, as GAP43 promotes growth and plasticity, while MAP2 supports the stability of established neurites. In neuroblastoma, the expression of GAP43 is often used as a marker to assess the differentiation state of the cells. Neuroblastoma cells that undergo differentiation, such as those treated with retinoic acid, show increased GAP43 levels, which correlates with enhanced neurite outgrowth (Lee et al., 2015). This suggests that GAP43 not only serves as a marker but also actively participates in the neurite outgrowth process in neuroblastoma, similar to its role in normal neurons. Conversely, MAP2 expression in neuroblastoma cells can indicate the maturation of neurites, as higher levels of MAP2 are associated with more stable and differentiated neuritic structures (Guha et al., 2016). The interplay between GAP43 and MAP2 in neuroblastoma cells reflects the complex regulatory mechanisms that govern neurite formation and stabilization. Moreover, the relationship between these proteins and neurite morphology is evident in various studies. For instance, GAP43 has been shown to promote the formation of filopodia and lamellipodia, structures essential for the initial stages of neurite outgrowth (Monroe & Heathcote, 2013). In contrast, MAP2's role in stabilizing microtubules is critical for maintaining the structure of mature neurites, thus facilitating their function in neuronal signaling (Lopez et al., 2023). The dynamic expression of these proteins during neuroblastoma cell differentiation highlights their importance in both normal neuronal development and cancer biology.

The treatment of SH-SY5Y neuroblastoma cells with matcha tea has been observed to lead to the downregulation of GAP43 and MAP2 expression, as well as a decrease in neurite number. This phenomenon can be interpreted through several interconnected biological mechanisms influenced by the components of matcha tea. GAP43 (Growth Associated Protein 43) and MAP2 (Microtubule-Associated Protein 2) are crucial proteins involved in neuronal growth and differentiation. The downregulation of these proteins suggests a potential inhibitory effect of matcha on neuronal development and plasticity. Research indicates that the components of matcha, particularly catechins, can exert neuroprotective effects, but they may also modulate signaling pathways that affect neuronal growth negatively under certain conditions. For instance, while matcha has been shown to have antioxidant properties and can enhance cognitive functions, its effects can vary based on dosage and the specific cellular

context (Igarashi et al., 2022; Zhou et al., 2020). Moreover, the decrease in neurite number could be linked to the modulation of oxidative stress pathways. Excessive reactive oxygen species (ROS) production can lead to apoptosis and inhibit neurite outgrowth in neuroblastoma cells (Harato et al., 2012; Zhang et al., 2019). Matcha tea, while rich in antioxidants, may also induce stress responses that could paradoxically lead to reduced neurite outgrowth if the cellular environment becomes unfavorable for growth (Dickson et al., 2020). This duality in the effects of matcha highlights the complexity of its bioactive compounds, which can both protect and impair neuronal function depending on the context. Additionally, the role of the JAK2/STAT3 signaling pathway in inflammation and neuroprotection should be considered. Matcha has been reported to modulate this pathway, which is involved in various neurodegenerative processes (Zhou et al., 2020). If matcha tea alters the balance of this signaling pathway, it could lead to a reduction in the expression of growth-related proteins like GAP43 and MAP2, thereby affecting neurite formation. In summary, the downregulation of GAP43 and MAP2 expression and the decrease in neurite number in SH-SY5Y cells treated with matcha tea may reflect a complex interplay of neuroprotective and neuroinhibitory effects mediated by its bioactive compounds. The findings underscore the necessity for further research to elucidate the specific mechanisms through which matcha influences neuronal growth and health.

REFERENCES

El-Elimat, T., Qasem, W., Al-Sawalha, N., AbuAlSamen, M., Munaiem, R., Al-Qiam, R., … & Sharie, A. (2022). A prospective non-randomized open-label comparative study of the effects of matcha tea on overweight and obese individuals: a pilot observational study. Plant Foods for Human Nutrition, 77(3), 447-454. https://doi.org/10.1007/s11130-022-00998-9

Herrera, M., Viera, I., & Roca, M. (2022). Hplc–ms2 analysis of chlorophylls in green teas establishes differences among varieties. Molecules, 27(19), 6171. https://doi.org/10.3390/molecules27196171

Jakubczyk, K., Kochman, J., Kwiatkowska, A., Kałduńska, J., Dec, K., Kawczuga, D., … & Janda, K. (2020). Antioxidant properties and nutritional composition of matcha green tea. Foods, 9(4), 483. https://doi.org/10.3390/foods9040483

Sasagawa, K., Domon, H., Sakagami, R., Hirayama, S., Maekawa, T., Isono, T., … & Terao, Y. (2021). Matcha green tea exhibits bactericidal activity against streptococcus pneumoniae and inhibits functional pneumolysin. Antibiotics, 10(12), 1550. https://doi.org/10.3390/antibiotics10121550

Wang, Y., Yu, Y., Ding, L., Xu, P., & Zhou, J. (2022). Matcha green tea targets the gut–liver axis to alleviate obesity and metabolic disorders induced by a high-fat diet. Frontiers in Nutrition, 9. https://doi.org/10.3389/fnut.2022.931060

Zhang, M., Li, L., Liu, P., & Holman, C. (2012). Green tea for the prevention of cancer: evidence of field epidemiology. Functional Foods in Health and Disease, 2(10), 339. https://doi.org/10.31989/ffhd.v2i10.79

El-Kholie, E., Afifi, T., & Abdelal, N. (2022). Potential Anti-Obesity Effects of Matcha Tea in Rats Fed on a High Fat Diet. *Journal of Home Economics - Menofia University*, *32*(1), 94-108. https://doi.org/10.21608/mkas.2021.97722.1082

Dickson, A., Cooper, E., Fakae, L. B., Wang, B., Chan, K. L. A., & Elsheikha, H. M. (2020). In Vitro Growth- and Encystation-Inhibitory Efficacies of Matcha Green Tea and Epigallocatechin Gallate Against Acanthameoba Castellanii. Pathogens (Basel, Switzerland), 9(9), 763. https://doi.org/10.3390/pathogens9090763

Banks, D., Dahal, A., McFarland, A., Flowers, B., Stephens, C., Swack, B., … & Hinton, S. (2017). Mk-styx alters the morphology of primary neurons, and outgrowths in mk-styx overexpressing pc-12 cells develop a neuronal phenotype. Frontiers in Molecular Biosciences, 4. https://doi.org/10.3389/fmolb.2017.00076

Guha, I., Slámová, I., Chun, S., Clegg, A., Golos, M., Thrasivoulou, C., … & Al-Shawi, R. (2016). The effects of short-term jnk inhibition on the survival and growth of aged sympathetic neurons. Neurobiology of Aging, 46, 138-148. https://doi.org/10.1016/j.neurobiolaging.2016.06.016

Jansen, J., Scott, M., Amjad, E., Stumpf, A., Lackey, K., Caldwell, K., … & Park, H. (2021). Bcl-xl is required by primary hippocampal neurons during development to support local energy metabolism at neurites. Biology, 10(8), 772. https://doi.org/10.3390/biology10080772

Lee, T., Tumanov, S., Villas-Bôas, S., Montgomery, J., & Birch, N. (2015). Chemicals eluting from disposable plastic syringes and syringe filters alter neurite growth, axogenesis and the microtubule cytoskeleton in cultured hippocampal neurons. Journal of Neurochemistry, 133(1), 53-65. https://doi.org/10.1111/jnc.13009

Lopez, J., Yamamoto, A., Vecchi, J., Hagen, J., Lee, K., Sonka, M., … & Lee, A. (2023). Caldendrin represses neurite regeneration and growth in dorsal root ganglion neurons. Scientific Reports, 13(1). https://doi.org/10.1038/s41598-023-29622-9

Monroe, J. and Heathcote, R. (2013). Protein phosphatases regulate the growth of developing neurites. International Journal of Developmental Neuroscience, 31(4), 250-257. https://doi.org/10.1016/j.ijdevneu.2013.01.005

Yu, H., Sun, D., Wang, N., Wang, M., Lan, Y., Fan, W., … & Zhu, X. (2015). Headless myo10 is a regulator of microtubule stability during neuronal development. Journal of Neurochemistry, 135(2), 261-273. https://doi.org/10.1111/jnc.13238

Баранов, С., Baranova, O., Yablonska, S., Suofu, Y., Vazquez, A., Kozai, T., … & Friedlander, R. (2018). Mitochondria modulate programmed neuritic retraction. Proceedings of the National Academy of Sciences, 116(2), 650-659. https://doi.org/10.1073/pnas.1811021116

Dickson, A., Cooper, E., Fakae, L., Wang, B., Chan, K., & Elsheikha, H. (2020). In vitro growth- and encystation-inhibitory efficacies of matcha green tea and epigallocatechin gallate against acanthameoba castellanii. Pathogens, 9(9), 763. https://doi.org/10.3390/pathogens9090763

Harato, M., Huang, L., Kondo, F., Tsunekawa, K., Feng, G., Fan, J., … & Okada, S. (2012). Bupivacaine-induced apoptosis independently of wdr35 expression in mouse neuroblastoma neuro2a cells. BMC Neuroscience, 13(1). https://doi.org/10.1186/1471-2202-13-149

Igarashi, K., Takagi, M., & Fukushima, Y. (2022). The effects of matcha and decaffeinated matcha on learning, memory and proteomics of hippocampus in senescence-accelerated (samp8) mice. Nutrients, 14(6), 1197. https://doi.org/10.3390/nu14061197

Zhang, H., Wang, W., & Du, Q. (2019). <p>andrographolide attenuates bupivacaine-induced cytotoxicity in sh-sy5y cells through preserving akt/mtor activity</p>. Drug Design Development and Therapy, Volume 13, 1659-1666. https://doi.org/10.2147/dddt.s201122

Zhou, J., Lin, H., Xu, P., Yao, L., Xie, Q., Mao, L., … & Wang, Y. (2020). Matcha green tea prevents obesity-induced hypothalamic inflammation via suppressing the jak2/stat3 signaling pathway. Food & Function, 11(10), 8987-8995. https://doi.org/10.1039/d0fo01500h

THE ROLE OF HIPPO SIGNALING PATHWAY AND CELL POLARITY IN VARICOCELE-INDUCED APOPTOSIS

SİMLA SU AKKAN [1], EZGİ GOLAL[2], NURAY ACAR AYDEMİR[3]

Akdeniz University, Faculty of Medicine, Department of Histology and Embryology, Antalya, Turkey (akkansimla@gmail.com)

Akdeniz University, Faculty of Medicine, Department of Histology and Embryology, Antalya, Turkey (ezgigolal@hotmail.com)

Akdeniz University, Faculty of Medicine, Department of Histology and Embryology, Antalya, Turkey (nurayacar@akdeniz.edu.tr)

ABSTRACT

Varicocele is known as the abnormal dilation of the testicular veins in pampiniform plexus. The increase in reactive oxygen species and nitric oxide in varicocele leads to changes cytoskeleton organisation in Sertoli cells, especially affecting the structure of blood-testicular barrier(BTB). This condition causes disruptions in translocation of germ cells during spermatogenesis. Hippo pathway is known to regulate proliferation and apoptosis, as well as being activated by various internal-external signals such as polarity. In this study, we aimed to investigate the effects of varicocele on the expression of Scribble, a polarity protein involved in BTB, and YAP, TEAD, CTGF, key components of the Hippo pathway.

This study was conducted using 42 male Sprague Dawley rats, which were randomly assigned to three groups:Control(n=14), Sham(n=14), and Varicocele(n=14). Thirteen weeks after establishing the experimental model, the animals were sacrificed. The tissues were stained with Hematoxylin-Eosin. The expression levels of Scribble, YAP, TEAD, and CTGF were demonstrated using WesternBlot and Immunohistochemistry. One-way ANOVA was applied to analyze the differences between the groups.Our analyses revealed a significant increase in seminiferous tubule degeneration in the experimental group. Additionally, a significant decrease in Scribble protein levels($p<0.05$) and a marked increase in YAP, TEAD, and CTGF compared to the control group were observed($p<0.05$).

The decrease in scribble expression in varicocele group led us to think that varicocele disrupts cell polarity in seminiferous epithelium and that the Hippo pathway also plays a role in this process. More detailed studies are needed to clarify relationship between increased apoptosis and impaired cell polarity in varicocele.

KEYWORDS

Varicocele, Cell Polarity, Hippo Pathway, Apoptosis

1.INTRODUCTION

A varicocele refers to the abnormal enlargement and dilation of the pampiniform plexus veins in the scrotum. Studies shows have linked varicocele to adverse effects on testicular histology, semen quality, sperm function, and reproductive hormones [1]. In this study, we focused on the negative impact of varicocele on testicular histology. While the pathogenesis of varicocele is multifactorial, oxidative stress appears to play a key role [2]. However, the potential mechanisms underlying varicocele-induced infertility remain the subject of various theories. In varicocele, the increase in reactive oxygen species (ROS) and nitric oxide (NO) causes changes in adhesion molecules and cytoskeleton organisation in Sertoli cells, especially affecting the structure of the blood-testicular barrier [3]. This condition causes disruptions in the translocation of germ cells during spermatogenesis and can affect fertility.

Cell polarity refers to the differences in shape, structure, and function that almost every cell establishes within itself as a result of the asymmetric organization of various cellular components, such as the cytoskeleton or intracellular molecules [4]. Sertoli cells exhibit distinct cell polarity in the seminiferous epithelium during spermatogenesis. In the testis, cell polarity plays a crucial role in spermatogenesis and germ cell maturation. Its key functions include: 1. Formation of the blood-testis barrier, 2. Regulation of spermatogenesis, and 3. Facilitating cell-cell interactions. The apico-basal polarity established by Sertoli cells is supported by three well-known “Cell Polarity Protein Complexes.” These are the PAR, Crumbs (CRB), and Scribble protein complexes [5].

The Hippo signaling pathway is a signaling pathway that controls organ size and cell number. It restricts cell growth and proliferation while triggering apoptosis **(6).** The Hippo signaling pathway is known to regulate proliferation, apoptosis, and differentiation, as well as being activated by various internal and external signals such as cell-cell contact, stress signals, and cell polarity [7, 8, 9].

While many studies on varicocele mechanisms have concentrated on changes in adhesion molecules, the role of polarity proteins -key structural elements of the Sertoli

cell cytoskeleton- and the associated cellular pathways remain relatively unexplored. The exact pathophysiology behind the adverse effect of varicocele on cell polarity remains uncertain. This study aims to identify the extrinsic and intrinsic cellular factors, such as polarity, that regulate the Hippo signaling pathways involved in varicocele-induced apoptosis. And our hypothesis is, that varicocele-induced disruption of cell polarity triggers apoptosis through the Hippo pathway.

2.MATERIALS AND METHODS

This study was conducted with a total of 42 male Sprague Dawley rats obtained from the Akdeniz University Experimental Animal Application and Research Center (ADAM). The rats were randomly divided into three groups: Control (n=14) Sham (n=14), Varicocele (n=14). Thirteen weeks after the establishment of the experimental model, animals were sacrificed.

The left spermatic vessel diameter was measured and analysed. The tissues were stained with Hematoxylin-Eosin and examined under a microscope to detect seminiferous tubule degeneration. The expression levels of Scribble, YAP, TEAD, and CTGF were demonstrated using Western Blot and Immunohistochemistry methods.

The statistical analysis of the results was performed using one-way ANOVA and post-hoc analyses. Values with $p<0.05$ were considered statistically significant. The statistical analyses were conducted using GraphPad Prism version 9.

3.RESULTS

While no significant difference was found in the diameters of the right spermatic veins between groups, a significant increase in the left spermatic vein diameters was observed in the varicocele-induced group compared to the control and sham groups ($p < 0.0001$) (Fig1).

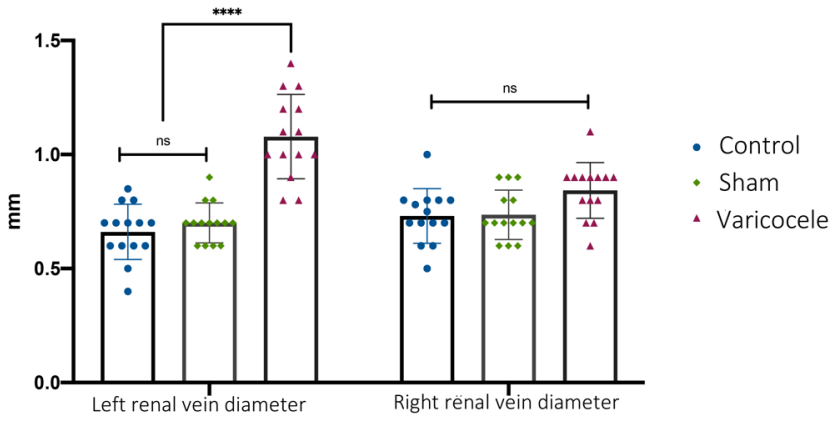

Figure 1. Evaluation of the diameters (mm) of the left and right spermatic veins ($p < 0.0001$)

According to our morphological evaluations of testicular tissue using Hematoxylin and Eosin staining, the seminiferous tubule epithelial structures in the control and sham groups exhibited normal morphological characteristics. However, we observed significant disruption of epithelial organization, detachment from the basal membrane, and shedding of germ cells into the lumen in a lot of seminiferous tubules from the varicocele group (Fig.2 A-C).

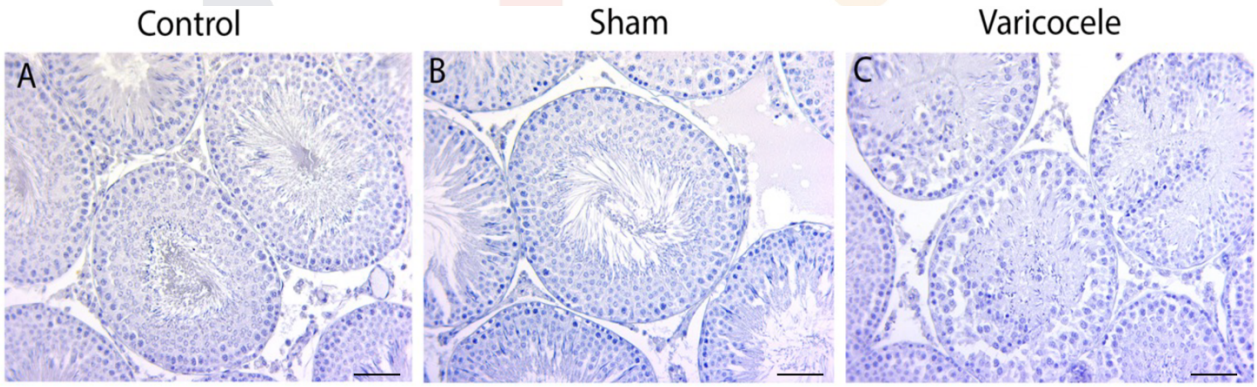

Figure 2. Hematoxylin & Eosin Staining of Control (A), Sham (B), and Varicocele (C) Groups (Scale Bar:50um)

According to the results of immunohistochemistry and Western blot analysis, a significant decrease in the protein level of Scribble was observed in the varicocele group (Fig.3C, F, G) compared to the control (Fig.3A, F, G) and sham groups (Fig.3B, F, G) ($p<0.05$).

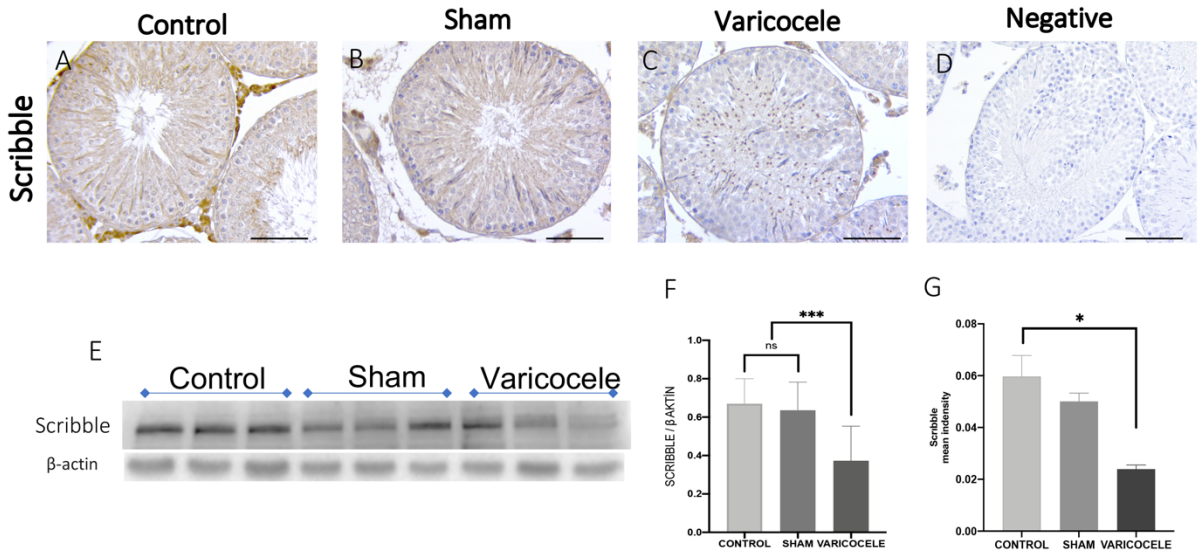

Figure 3. The results of the immunohistochemistry and Western blot analyses of Scribble protein levels are shown (*; $p<0.05$, ***; $p=0.0008$) β-Actin was used as a positive control. (Scale Bar: 50µm)

The protein levels of YAP, a transcriptional coactivator in the Hippo signaling pathway, and TEAD, which forms a complex with YAP and is involved in proliferation and apoptosis, were analyzed. A significant increase in the levels of both proteins was observed in the varicocele groups (Fig.4C, G, I, J, M, N) ($p<0.05$).

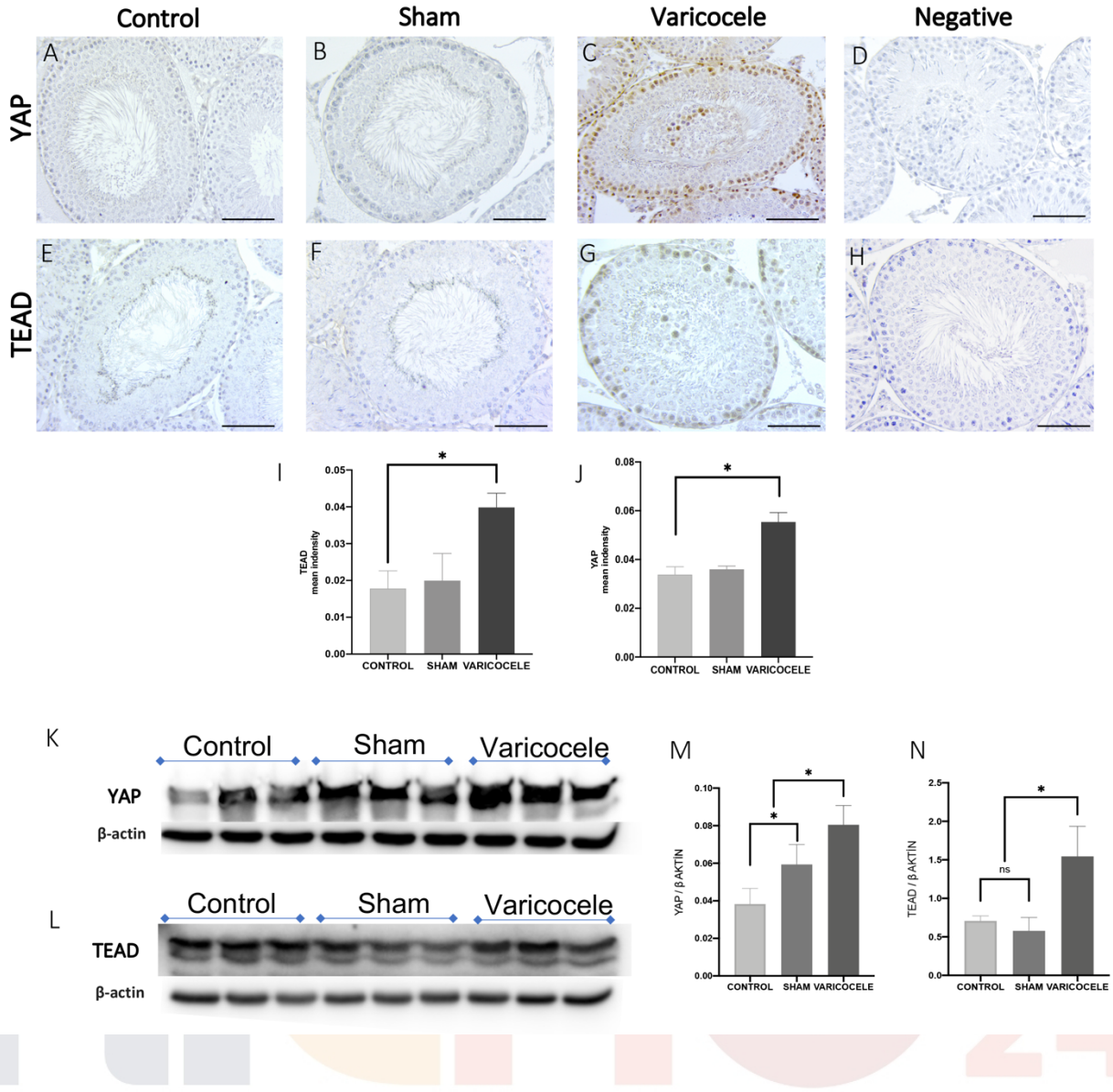

Figure 4. The results of the immunohistochemistry and Western blot analyses of YAP and TEAD protein levels are presented (*; p<0.05). β-Actin was used as a positive control. (Scale Bar: 50 µm)

Intergroup comparisons revealed a significant increase in connective tissue growth factor (CTGF) protein levels in the varicocele group (Fig.5C, F, G) compared to the control (Fig.5A, F, G) and sham (Fig.5B, F, G) groups (p<0.05).

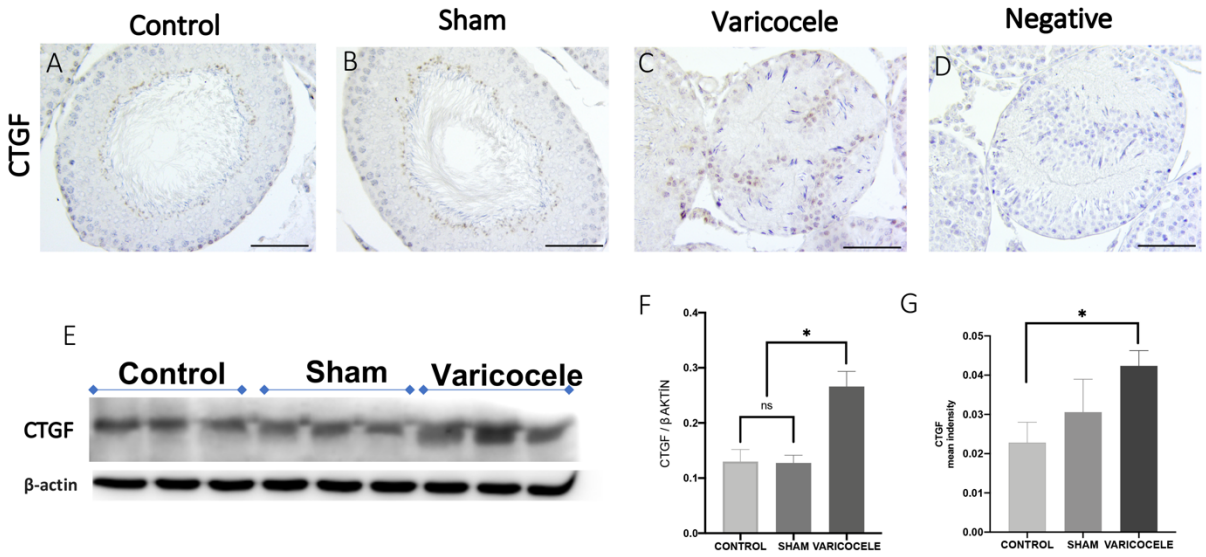

Figure 5. The results of the immunohistochemistry and Western blot analyses of CTGF protein levels are shown (*; $p<0.05$). β-Actin was used as a positive control. (Scale Bar: 50 µm)

4.DISCUSSION

Mammalian Scribble (SCRIB) which plays a role in cell polarity, facilitates the activation of MST and LATS kinases in mammalian epithelial cells and inhibits the nuclear activities of YAP/TAZ. Loss of Scribble disrupts the association of TAZ with the core Hippo kinases MST and LATS [10]. The dephosphorylated YAP/TAZ complex enters the nucleus and, together with TEAD, induces the pro-apoptotic process.

Our findings demonstrated a decrease in Scribble protein levels and an increase in YAP, TEAD, and CTGF levels in the presence of varicocele. These results suggest that, in addition to the disruptions in the blood-testis barrier and spermiation mechanism caused by the reduction in Scribble expression under varicocele conditions, the elevated levels of YAP and TEAD may enhance pro-apoptotic activity in the nucleus, triggering varicocele-induced apoptosis. This study aimed to link cell polarity to the Hippo pathway and provide a mechanistic basis for understanding how varicocele-induced apoptosis might affect spermatogenesis. However, these results still need further examination because we do not fully know some aspects of the relationship between varicocele and cell polarity.

5.REFERENCES

1. Jensen CFS, Østergren P, Dupree JM, Ohl DA, Sønksen J, Fode M. (2017). Varicocele and male infertility. Nat Rev Urol, 14(9):523-533.

2.Agarwal A, Hamada A, Esteves SC. (2012). Insight into oxidative stress in varicocele-associated male infertility: part 1. Nat Rev Urol, 9(12):678-90.

3. Ha HK, Park HJ, Park NC. (2011) Expression of E-cadherin and α-catenin in a varicocele-induced infertility rat model. Asian J Androl, 13(3):470-5.

4. Piroli ME, Blanchette JO, Jabbarzadeh E. (2019) Polarity as a physiological modulator of cell function. Front Biosci (Landmark Ed), 24(3):451-462.

5. Li L, Li H, Wang L, Wu S, Lv L, Tahir A, Xiao X, Wong CKC, Sun F, Ge R, Cheng CY. (2020). Role of cell polarity and planar cell polarity (PCP) proteins in spermatogenesis. Crit Rev Biochem Mol Biol, 55(1):71-87.

6. Zhang L, Yue T, Jiang J. (2009). Hippo signaling pathway and organ size control. Fly (Austin), 3(1):68-73.

7. Wada K, Itoga K, Okano T, Yonemura S, Sasaki H. (2011). Hippo pathway regulation by cell morphology and stress fibers. Development, 138(18):3907-14.

8. Wang M, Dai M, Wang D, Xiong W, Zeng Z, Guo C. (2021). The regulatory networks of the Hippo signaling pathway in cancer development. J Cancer.,12(20):6216-6230.

9. Mo JS, Park HW, Guan KL. (2014). The Hippo signaling pathway in stem cell biology and cancer. EMBO Rep, 15(6):642-56.

10. Cordenonsi M, Zanconato F, Azzolin L, Forcato M, Rosato A, Frasson C, Inui M, Montagner M, Parenti AR, Poletti A, Daidone MG, Dupont S, Basso G, Bicciato S, Piccolo S. (2011). The Hippo transducer TAZ confers cancer stem cell-related traits on breast cancer cells. Cell, 147(4):759-72.