Okajimas Folia Anat. Jpn., **79**(5): 159–162, December, 2002

A Rare Multiple Variation of the Greater Omentum

By

Tuncay ÇOLAK*, Cannur DALÇIK*, Aydın ÖZBEK*, Serdar FİLİZ, Murat ŞAHİN* and Hakkı DALÇIK****

*Department of Anatomy, **Department of Histology and Embryology, Faculty of Medicine, University of Kocaeli, Derince Kocaeli, Turkey

– Received for Publication, August 12, 2002 –

Key Words: Peritoneum, Greater omentum, Peritoneal folds, Variation, Anomaly

Summary: In a dissection performed in our department, we observed multiple variations of the greater omentum. The ununusual attachments of the greater omentum were identified. While the right upper part combined with ligamentum teres hepatis, the left upper part had connection with the anterolateral abdominal wall. In addition, the free lower margin of the greater omentum was bound to the front of the abdomen wall. These ununusual attachments contained vessels and nerves. The greater omentum is used in reconstructive surgery of the chest wall. And its ligaments are important in abdominal surgery. Therefore, it is important to keep in mind the different attachments of the greater omentum, so that caution is required during intraabdominal surgery and also in appropriately interpreting the radiographs.

The peritoneum, is the largest and the most complex serous membrane of the body and it's largest fold is called the greater omentum. The greater omentum has multiple ligaments that are already defined (lig.gastrolienale, lig.lienorenale, lig.gastrocolica). By means of these ligaments the greater omentum divides the peritoneal cavity into a series of compartmants. Peritoneal cavity and its ligaments is particular important, because this region is frequently interfered within pathological states.

Case Report

While dissecting a 78 year old male cadaver we found that the free lower margin of the greater omentum was bound to the front of the abdomen wall from its mid-line. It was continuous along the median umbilical fold (Fig. 1, 3). The upper part which attaches to the great curvature of the stomach was combined with the ligamentum teres hepatis at the liver (Fig. 2, 3). Besides at the level of the splanic flexura we found another connection with the anterolateral wall (Fig. 2, 3). In the present case there were no anomaly such as malrotation nor diaphragmatic hernia.

Tissues of the ununusual attachments were dehydrated and embedded in paraffin. Dewaxed, 5 mm thick sections were stained with hematoxylin and eosin. Slides were examined under the light microscope (Olympus BX50). Many variable sized arteries between the loose connective tissue was visualized. In addition, great amount of smooth muscle fibers, adipose tissue and nerve plexus was also recognized (Fig. 4).

Discussion

Peritonal cavity and its ligaments are common sites for infection, neoplasia and trauma[1]. Therefore, the specifies of the peritoneal cavity and its ligaments especially the cavities formed by greater omentum and its ligaments should be precisely evaluated[2]. Many work has been done to get a better knowledge on the normal structures and to allow correct radiological interpretations[1–5]. No variations were reported in the previous related studies. Although, primary anomalies of the peri-

Proofs requests: Dr. Aydın Özbek, Department of Anatomy, Faculty of Medicine, University of Kocaeli, Derince Kocaeli, Turkey, E-mail: aydinoz@superonline.com



Fig. 1. Photagraph of the inferior connection of the greater omentum with the median umbilical fold.
fa: the attachment of the free lower margin of the greater omentum to the median umbilical fold, **m**: median umbilical fold, **me**: medial umbilical fold, **o**: greater omentum.

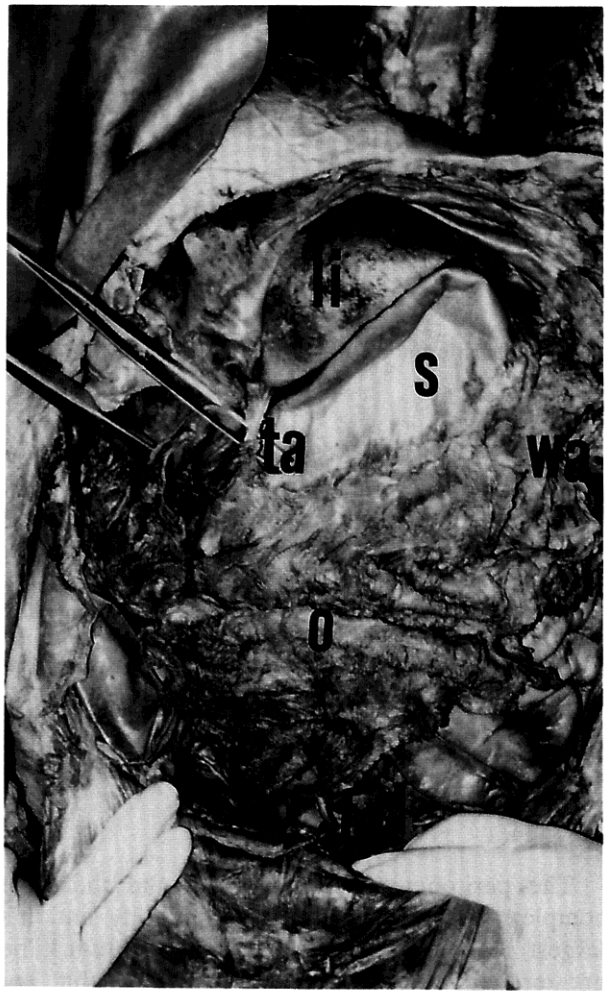

Fig. 2. Photagraph of the total attachment of the greater omentum.
fa: the attachment of the free lower margin of the greater omentum to the median umbilical fold, **wa**: the upper attachment to the abdominal wall, **ta**: the upper attachment to the ligamentum teres hepatis, **o**: greater omentum, **s**: stomach, **li**: liver.

toneum and greater omentum are very rare, secondary anomalies due to infection, trauma and neoplasia are seen quite frequently[5]. Development stages of the greater omentum and the peritoneum were studied in animals[6–7]. Similar studies were also done in human fetuses[8–9]. In neither of these studies there were no variation of the omentum that resembled the one in the present study.

In some cases, greater omentum that covers ascending colon binds to the abdominal wall, and this is refered to as jackson's membrane[10]. Normally, the right aspect of the greater omentum is free[11]. In some cases this membrane, especially in neonatals, thickens and binds to the iliac crest. By means of this connection, it supports the relatively big liver during development. In this case, it is called sustantenaculum hepatis. It was also reported that the greater omentum in some cases makes ligamentous binding to the abdominal wall on the left side[10–11]. Same condition was also demonstrated in our case. In addition, other duodenal variations were also reported (lig.cystoduodenale, lig.cystogastrocalica)[11–12]. The ligament in our case had no connection with the gall bladder but had a direct connection to the lig.teres hepatis. There is no reported multiple variation resembling to our case report. In addition, there is no reported plica connection to the abdominal front wall nor

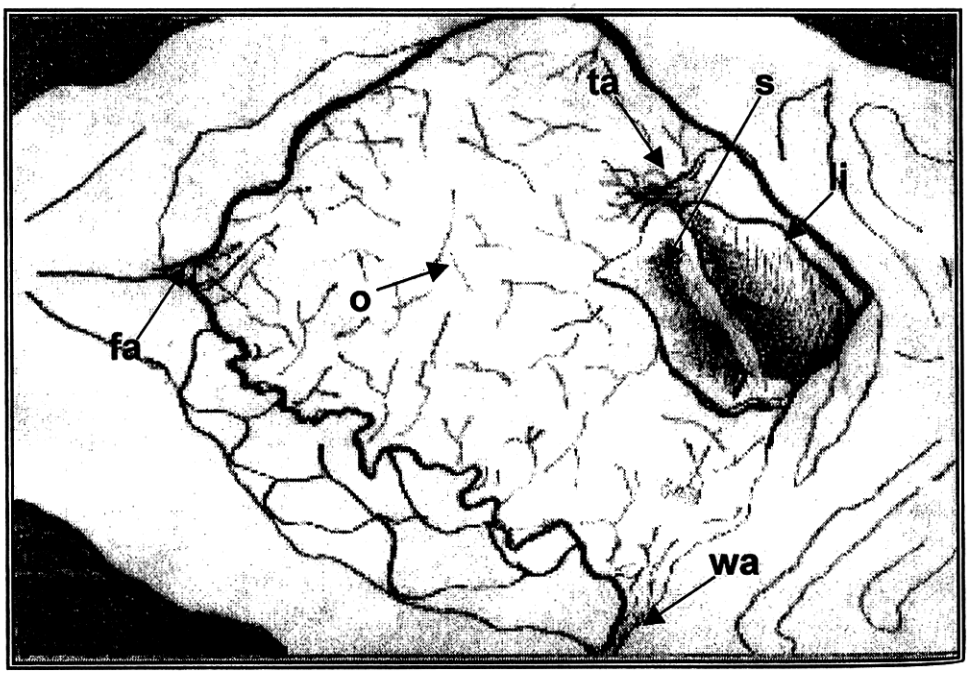

Fig. 3. Drawing of Fig. 2.
fa: the attachment of the free lower margin of the greater omentum to the median umbilical fold, **wa**: the upper attachment to the abdominal wall, **ta**: the upper attachment to the ligamentum teres hepatis, **o**: greater omentum, **s**: stomach, **li**: liver.

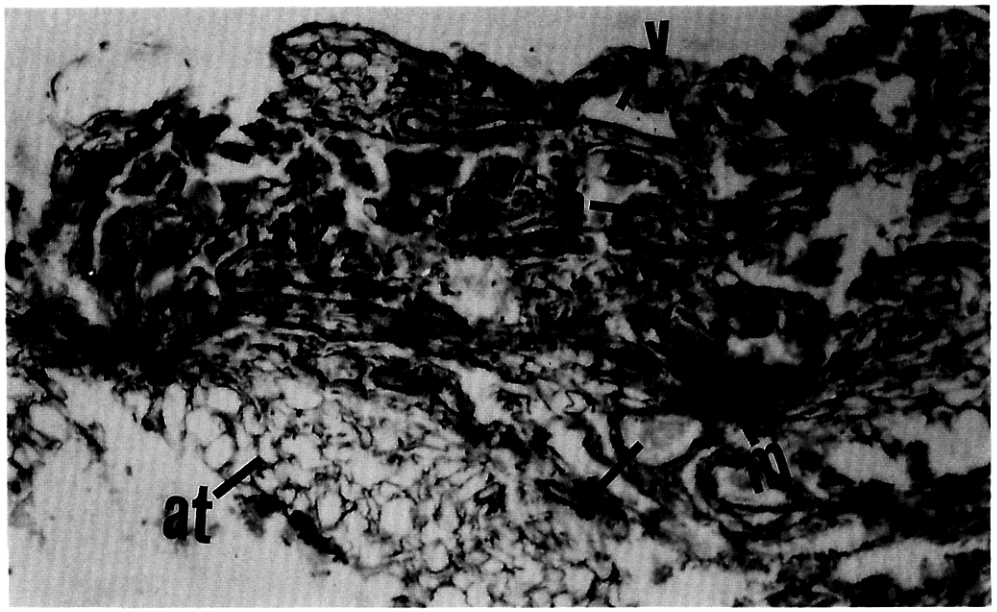

Fig. 4. Light micrograph of the attachment of the greater omentum with the median umbilical fold.
n: nerves, **v**: vessels, **m**: smooth muscle fibers, **at**: adipose tissue.

to the lig.teres hepatis. Because the adhesions contained vessels, smooth muscle fibers and nerves (see Fig. 4). It is not a result of previous surgery or intra-abdominal infections. One possible embryological explanation for the variable attachment of the greater omentum could be as follows: during development, the expansion of the pleuroperitoneal canals approximates the two ducts to each other along the dorsal aspect of the primitive gut; they will be separeted only by splanchnic mesoderm through which vessels and nerves reach the gut. The median sagittal septum of mesoderm that suspends the primitive gut along its entire length is the common dorsal mesentery. Around the midgut and the hindgut, the left and right pleuroperitoneal canals approximate ventrally to each other. As their walls contact each other on the ventral aspect of the gut, they form the ventral mesentery. This mesentery, however, conveys no vessels or nerves and rapidly disappears. But the ventral mesentery of the foregut retains a permanent connection (the lesser omentum and the falciform ligament) between the ventral abdominal wall and foregut. In addition, unlike the ventral mesentery of the midgut, hindgut, the ventral mesentery of the foregut conveys blood vessels and nerves. But in our case, some parts of the ventral mesentery of the midgut, hindgut may retain a permanent connection between the ventral abdominal wall and the dorsal mesentery (because greater omentum is derived from the dorsal mesentery). Very interestingly, these connections contained vessels and nerves. Therefore, these connections may not have derived from the ventral mesentery of the midgut or hindgut. They may have derived from the dorsal mesentery and abnormally extended to the ventral abdominal wall.

Conclusively, there are many studies the have been done to evaluate the abdominal cavity which is a frequent site of pathological incidences. The vascular complexes in these abnormal connection may be very important. As the greater omentum is used in reconstructive surgery of the chest wall, the variations of this area are of great importance [13–15]. In addition, these vessels may be functionally important in the portal hypertension cases.

References

1) Sivit CJ. CT scan of mesentery-omentum peritoneum. Radiologic Clinics of North America 1996; **34**(4):863–864.
2) Bennet HF and Balfe DM. MR imaging of the peritoneum and abdominal wall. Magnetic Resonance Imaging Clinics of North America 1995; **3**(1):99–120.
3) Oliphant M and Berne AS. CT of the subperitoneal space: demonstration of direct spread of intraabdominal disease. Journal of Computer Assisted Tomography 1982; **6**(6):1127–37.
4) Ceuterick L, *et al.* CT diagnosis of primary torsion of greater omentum. Journal of Computer Assisted Tomography 1987; **11**(6):1083–1084.
5) Ruess L, Frazier AA and Sivit CJ. CT of the mesentery, omentum and peritoneum children. Radiographics 1995; **15**(1):89–104.
6) Martin E, *et al.* Development of the genital peritoneal folds in sheep. Anatomia Histologia Embriyologia 1996; **25**(3):187–195.
7) Martin E, *et al.* Changes in the peritoneum during the development of the testis, epididymis, and ductus deferens in the pig. Anatomia Histologia Embriyologia 1993; **22**(3):201–211.
8) Grzybiak M. Peritoneal folds and recesses of the intestinal surface of the anterior abdominal wall in fetuses and neonates. Folia Morphologica 1975; **34**(1):43–51.
9) Seidl W. Development of the intestines. Human embryos. Acta Morphologica Neerlando-Scandinavica 1976; **14**(4):299–318.
10) Williams PL, Bannister LH and Berry MM. Gray's Anatomy. 38. British ed. p 1744 Churchill Livingstone, Newyork, 1995.
11) Rosse C and Rosse PG. Textbook of Anatomy. 5. Ed. Newyork. pp 534–535, 1997.
12) Low VH, Davis SJ and Yoong MF. Anomalous peritoneal folds of the duodenum – a normal variant simulating disease. Australasian Radiology 1992; **36**(2):135–136.
13) d'Udekem Y, Lengele B, Noirhomme, *et al.* Radical debridement and omental transposition for post sternotomy mediastinitis. Cardiovascular Surgery 1998; **6**:415–418.
14) Jurkiewicz MJ and Arnold PG. The omentum: An account of its use in the reconstriction of the chest wall. Annals of Surgery 1977; **185**:548–554.
15) Goldsmith H. The omentum; research and clinical application. Springer Verlag, New York, 1988.