BMC Ophthalmology

CASE REPORT Open Access

Trigeminal sensory neuropathy developing as a late complication after the treatment of surgically induced necrotizing scleritis following pterygium surgery: a case report and literature review

Buğra Karasu[1], Nilay Kandemir Beşek[2], Enes Kesim[3] and Büşra Yılmaz Tuğan[3*]

Abstract

Background Surgically induced necrotizing scleritis (SINS) is an immune-mediated disease that occurs infrequently after ocular procedures, with latency ranging from days to years. There are various early and late complications that can negatively affect quality of life after SINS. This case report aims to present late trigeminal sensory neuropathy (TSN), corresponding in this patient to painful post-traumatic trigeminal neuropathy (ICHD-3 13.1.2.3), as a complication in a patient who developed SINS after pterygium surgery (PS).

Case presentation A 31-year-old woman was admitted to our clinic for cosmetic surgical removal of bilateral pterygium. She had an unremarkable medical history. Following the 10th postoperative day in the right eye, the patient complained of eye irritation, visual impairment, and hypersensitivity to light. On biomicroscopic examination, the conjunctival autograft on the sclera had melted, and a choroidal reflex was visible. A multi-layered amniotic membrane graft was applied to the erosion during our initial repair; however, the graft deteriorated within one week. Conjunctival covering surgery with a pericardial patch was performed on the patient's area of scleral melting. Rheumatological evaluation was unremarkable, with no evidence of an underlying systemic disease. The patient, who had been undergoing systemic pulse steroid treatment and topical cyclosporine/steroid treatment for scleritis, was diagnosed with painful post-traumatic trigeminal neuropathy in the neurology department 3 months after her third surgery. This diagnosis was based on persistent symptoms (photophobia, dental pain, and headache) that did not respond to systemic and topical treatments for SINS. The patient who was treated for TSN responded to oral gabapentin treatment.

Conclusion To the best of our knowledge, this is the first report of painful post-traumatic trigeminal neuropathy as a late complication of SINS following pterygium surgery. Physicians should consider this diagnosis in patients with persistent neuropathic pain after SINS.

*Correspondence:
Büşra Yılmaz Tuğan
busrayilmaz87@hotmail.com

Full list of author information is available at the end of the article

© The Author(s) 2026. **Open Access** This article is licensed under a Creative Commons Attribution-NonCommercial-NoDerivatives 4.0 International License, which permits any non-commercial use, sharing, distribution and reproduction in any medium or format, as long as you give appropriate credit to the original author(s) and the source, provide a link to the Creative Commons licence, and indicate if you modified the licensed material. You do not have permission under this licence to share adapted material derived from this article or parts of it. The images or other third party material in this article are included in the article's Creative Commons licence, unless indicated otherwise in a credit line to the material. If material is not included in the article's Creative Commons licence and your intended use is not permitted by statutory regulation or exceeds the permitted use, you will need to obtain permission directly from the copyright holder. To view a copy of this licence, visit http://creativecommons.org/licenses/by-nc-nd/4.0/.

Keywords Trigeminal sensory neuropathy, Surgically induced necrotizing scleritis, Pterygium excision, Scleral necrosis, Painful post-traumatic trigeminal neuropathy

Introduction

Scleral inflammation and necrosis can impair ocular surgical recovery and result in sight threatening consequences [1]. Scleral necrosis and/or melting are uncommon complications that can occur after pterygium surgery (PS). Infection, ischemia and autoimmune response are potential causes that induce scleral necrosis after PS [2]. Autoimmunity is now widely regarded as an underlying cause of surgically induced necrotizing scleritis (SINS). Immune complexes have been discovered in and around episcleral veins endothelium using immunofluorescence staining, and systemic/topical immunosuppressive treatments have proven efficient outcomes in the therapy of SINS [3].

The trigeminal nerve innervates the face, mucous membranes, and other parts of the head via its three branches: the ophthalmic, maxillary, and mandibular [4]. The intensity of the inflicted damage determines the ensuing complications of nerve injury. The consequences of nerve injury can range from minor issues such as transitory hypoesthesia to worsening quality of life consequences like trigeminal sensory neuropathy (TSN) [5]. When such neuropathy is painful and follows an identifiable traumatic event, it is classified as painful post-traumatic trigeminal neuropathy (ICHD-3 13.1.2.3), which is the form observed in our patient [6]. Reports of TSN after eye surgery are limited [7–9]. This report aimed to present a case of late TSN in a patient who developed scleral necrosis following PS.

Case report

A 31-year-old female patient with an unremarkable medical history presented with bilateral pterygium for five years, requesting cosmetic removal. Except for bilateral pterygium (type 1 pterygium) involving both corneas up to 2 mm nasally, the medical history and the eye examination were normal. The pterygium excision was performed on the right eye under topical anesthesia (oxybuprocaine hydrochloride 0.4% eye drops) using a conjunctival autograft. One free conjunctival autograft was obtained from the superotemporal bulbar conjunctiva of the right eye, with no underlying Tenon's capsule, to overlie the bare sclera. To secure the graft in the right eye, mild cauterization with bipolar forceps, without mitomycin C (MMC), was performed, and 8 – 0 Vicryl absorbable sutures and fibrin glue were used. The patient was given a moxifloxacin/dexamethasone eye ointment the following day. Ten days later, the patient complained of right eye irritation, impaired vision, and light hypersensitivity. Her examination revealed that she had a best-corrected visual acuity (BCVA) of 20/32 in her right eye due to irregular astigmatism (baseline BCVA was 20/20 in her right eye) and an ischemic, melting conjunctival graft and underlying nasal sclera associated with conjunctival hyperemia (Fig. 1a). The choroidal reflex was also seen. No intraocular inflammation was detected, and the graft bed in the right eye showed no signs of inflammation. A negative Gram stain and scleral scrapings revealed no bacterial growth, thereby ruling out an infectious origin. The conjunctival autograft began to melt rapidly, as did the scleral bed; the choroidal reflex became visible. Biomicroscopic examination revealed prominent scleral erosion. On postoperative day 14, a multi-layered amniotic membrane graft was applied to the erosion during our initial repair; however, it deteriorated within one week. Eyelashes and debris continued to accumulate at the base of the nearly exposed uvea, prompting us to return to the operating room for a more intricate repair. Methylprednisolone was administered intravenously preoperatively (one day prior to surgery). On postoperative day 22, surgery was performed at the site of scleral erosion using a Tutoplast pericardium allograft (Innovative Ophthalmic Products Inc, Costa Mesa, CA). A Tutoplast pericardium graft, which is thinner than the sclera yet resembles it in color and opacity, was positioned over this region and secured to the sclera using 8/0 Vicryl sutures. The conjunctiva was sutured using interrupted 7/0 Vicryl sutures facilitated by an existing conjunctival bridge and subsequently protected with a double layer of amniotic membrane. Conjunctival covering with a pericardial patch was applied to the area of scleral melting in the patient (Fig. 1b and c). Further investigation was carried out. The rheumatology department consulted the patient during these procedures.

Laboratory assessments were conducted to investigate the potential inflammatory, autoimmune, or infectious causes of the necrotizing scleritis. Laboratory evaluations included the following components: scrapings from the graft surface for smear and culture analysis; standard blood tests, including complete blood count, erythrocyte sedimentation rate (ESR), C-reactive protein (CRP), and serum uric acid; comprehensive blood screenings for autoimmune disorders, including tests for rheumatoid factor; perinuclear and cytoplasmic anti-neutrophil cytoplasmic antibodies; antinuclear antibodies; anti-DNA antibodies; antinuclear antigen antibodies; and complement and thyroid antibodies; serological tests for human immunodeficiency virus types 1 and 2, varicella-zoster virus, hepatitis B virus, hepatitis C virus, the Venereal Disease Research Laboratory test, and the Treponema pallidum hemagglutination assay; chest X-ray; and a

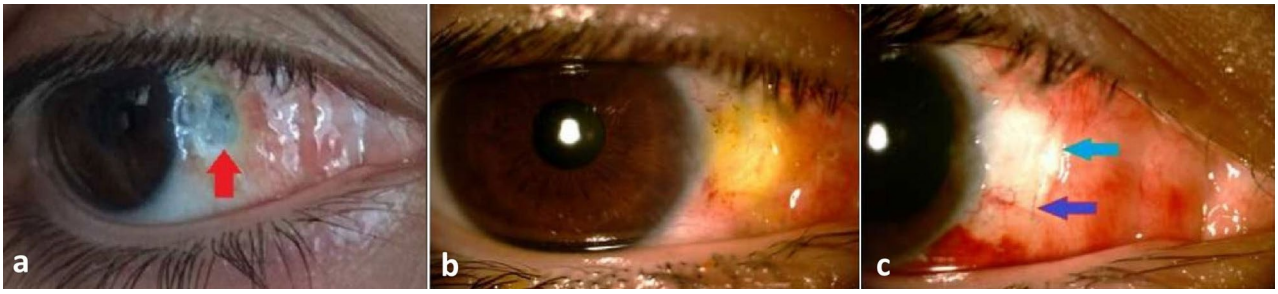

Fig. 1 **(a)** The red arrow indicates area of scleral melting, where the choroidal reflex is also visible. (**b)** The pericardial patch covering the scleral defect is visible under fluorescein staining. (**c)** The light blue arrow shows the healed scleral patch two months after surgery, and the dark blue arrow indicates the sutures of the patch

Mantoux test for tuberculosis. All of these investigations were negative, and no evidence of an underlying systemic rheumatological disease was identified.

The rheumatological assessment found no clinical or laboratory evidence of systemic lupus erythematosus, sarcoidosis, rheumatoid arthritis or other rheumatological conditions associated with ocular involvement. The patient did not have any systemic disease, such as diabetes mellitus or hypertension, that would preclude systemic prednisolone treatment. During these procedures, the patient also received outpatient systemic pulse steroid therapy and topical cyclosporine/steroid therapy for scleritis. Under this treatment the scleral inflammation gradually subsided and the patch remained stable. In the second month after the pericardial patch surgery, approximately three months after the initial pterygium excision, the patient developed severe, excruciating, and persistent ipsilateral dental pain and headache in addition to ocular pain, all of which continued despite treatment of the SINS. The dental pain was localized to the ipsilateral maxillary teeth and was continuous rather than paroxysmal, with a deep, aching quality and superimposed exacerbations, described as severe, and no cutaneous trigger zone was identified. The headache was ipsilateral, frontotemporal and periorbital, described as pressing, continuous rather than paroxysmal and severe, and was accompanied by marked photophobia. Because the pain involved the maxillary region, the patient underwent dental evaluation, which revealed no odontogenic pathology that could account for the symptoms.

The patient was referred to the neurology department 3 months after conjunctival cover surgery with a pericardial patch, approximately 4 months after the initial surgery. Cranial computed tomography and magnetic resonance imaging were performed and revealed normal findings, with no demyelinating lesion or mass lesion along the course of the trigeminal nerve. She was diagnosed with painful post-traumatic trigeminal neuropathy, the ICHD-3 criteria being satisfied by unilateral facial pain in the distribution of the trigeminal nerve, a history of an identifiable traumatic event to the nerve territory, onset of pain within six months of that event, and persistence for longer than three months [6]. Oral gabapentin was started at that visit, and her pain resolved one month later. The final follow-up visit was at 6 months, at which the scleral patch remained intact and the patient was free of pain (Fig. 2).

Literature search

A PubMed/MEDLINE search was performed in April 2026, with no restriction on publication date or article type and limited to publications in English. Terms for trigeminal nerve pathology (trigeminal sensory neuropathy, trigeminal neuropathy, trigeminal neuralgia, trigeminal nerve injury, neuropathic pain) were combined with terms for ocular surgery and scleral disease (ocular surgery, ophthalmic surgery, eye surgery, pterygium, scleritis, scleral necrosis), yielding 59 records. After screening of titles and abstracts and review of the full texts, five patients reported in three articles were identified as describing trigeminal neuropathic pain following ocular surgery, and these are summarized in Table 1 [7–9]. A second, focused search combining surgically induced necrotizing scleritis, scleral necrosis and scleral melting with trigeminal, neuralgia and neuropathic pain retrieved two records, neither of which was relevant. No previously reported case of trigeminal neuropathy following surgically induced necrotizing scleritis was identified.

Discussion

Scleral necrosis represents a rare yet serious variant of scleritis that poses a significant risk to both vision and the structural integrity of the eye. This condition has been documented after various types of ocular surgeries, with pterygium excision being the most frequently associated procedure [2, 10, 11]. Postoperative infection may be a cause of scleritis following surgical procedures. Nevertheless, like numerous cases documented in the literature, both smears and cultures yielded negative results in this study [12, 13].

Surgical necrotizing scleritis may be seen after uneventful eye surgery and may occur with a latent

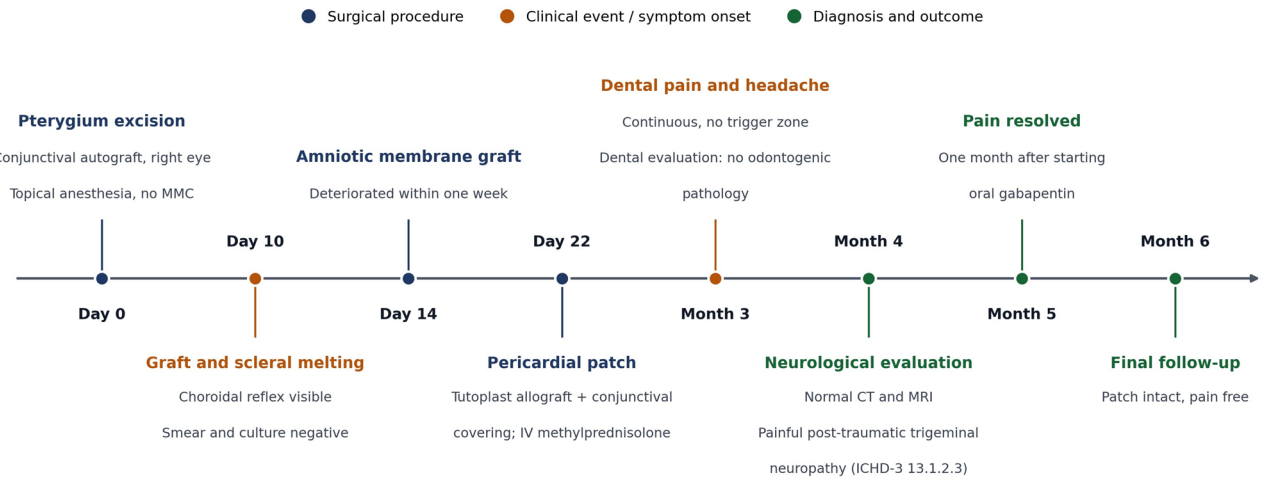

Fig. 2 Timeline of the clinical course. Surgical procedures are shown in blue, clinical events and symptom onset in orange, and diagnostic milestones and outcome in green. Time points up to day 22 are given relative to the initial pterygium excision (day 0); subsequent time points are given in months from the same reference. MMC, mitomycin C; ICHD-3, International Classification of Headache Disorders, third edition

period ranging from one day to 40 years [3]. Scleral melting occurs near the surgical wound location, with the potential to involve the whole anterior ocular region [3, 14]. It could potentially be the first sign of a systemic autoimmune disorder [15]. The etiological factors leading to SINS are autoimmunity and hypersensitivity. This is due to immunofluorescence staining that revealed immune complexes in and around episcleral veins walls, as well as yielding therapy with systemic and/or topical immunosuppressives [14]. Importantly, the patient in this study experienced scleral necrosis in the absence of MMC use or intraoperative irradiation, and microbiological tests were negative. Considering the lack of these possible contributing factors, the diagnosis of SINS was established [3, 11, 16].

For patients who are unresponsive to topical medication, medical management of SINS after PS includes immunosuppression with the oral steroids + cyclophosphamide or tacrolimus [17]. Furthermore, surgical intervention in the form of sclera, cornea, or amniotic membrane patch grafts has been documented [3]. Since our patient's scleral erosion was severe, a pericardial patch was implanted after amnion surgery, and systemic steroid and topical immunosuppressive treatments were applied simultaneously.

Trigeminal nerve injury produces a clinical spectrum that ranges from painless sensory loss, in which unilateral or bilateral numbness (hypoesthesia) predominates, to persistent neuropathic pain accompanied by burning, tingling and allodynia [5]. When pain follows an identifiable traumatic event and develops within six months of it, the presentation is classified as painful post-traumatic trigeminal neuropathy (ICHD-3 13.1.2.3) [6]. Our patient falls at this painful end of the spectrum. Trigeminal neuropathic pain following eye surgery has been reported very rarely. In all previously described patients — the three cases of Lucena et al. [7], the patient of Jacobs-El and Shaikh [8] and that of Moses [9] -the pain was paroxysmal and reproducibly evoked by innocuous stimuli, and the diagnosis was trigeminal neuralgia (ICHD-3 13.1.1); all followed intraocular procedures, with a latency ranging from the night of surgery to twenty days. The present case differs on each of these points: the pain was continuous with no identifiable trigger zone, the causative procedure was extraocular surface surgery, and the latency was measured in months (Table 1). In 2018, the authors published a case series of three patients who underwent phaco-vitrectomy for epiretinal membrane + cataract, primary corneal repair + necrotic iris removal for penetrating corneal injury, and lensectomy + vitrectomy (removal of a lens luxateds into the vitreous humor) after blunt trauma. In all three cases in the study, triggerable electric-type unilateral facial pain developed shortly after various ophthalmic surgeries and was diagnosed with trigeminal neuralgia based on clinical criteria. The third edition of the International Classification of Headache Disorders (ICHD-3) [6] does not specify diagnostic criteria for TSN after ophthalmic surgery. Although Lucena et al. [7] applied the ICHD-3 criteria for painful post-traumatic trigeminal neuropathy, all three of their patients were ultimately classified as having trigeminal neuralgia (ICHD-3 13.1.1) on the basis of paroxysmal, electric shock-like pain reproducibly evoked by innocuous stimuli, as were the patients of Jacobs-El and Shaikh [8] and of Moses [9]. Our patient's pain differed phenotypically: it was continuous and unremitting rather than paroxysmal, and no cutaneous trigger zone was identified. This continuous phenotype, together with an identifiable traumatic event, a latency of approximately three months from the initial surgery and a response to gabapentin, is

Table 1 Reported cases of trigeminal neuropathic pain following ocular surgery, compared with the present case

Study / Patient	Diagnosis (Outcome)	Ocular Event / Surgery	Onset and Characteristics of Symptoms	Additional Findings / Imaging	Treatment and Course
Lucena et al. [7] Patient 1	Trigeminal neuralgia with ophthalmic branch involvement (TN diagnosis was based on 4 out of 9 clinical criteria of the IHS)	Phaco-vitrectomy for left eye epiretinal membrane + cataract	On postoperative day 20; sudden, shock-like, unilateral facial pain, triggered by numerous stimuli	Normal findings on both CT and MRI	TN diagnosis followed neurology/anesthesia consultation; treatment with tramadol and morphine was started. Good response was observed. There were a few more attacks in the first 2 months, no new attacks were observed in the 1-year follow-up.
Lucena et al. [7] Patient 2	Trigeminal neuralgia (TN diagnosis was based on 4 out of 9 clinical criteria of the IHS)	Right eye perforating injury; primary corneal repair + excision of necrotic iris	On postoperative day 6, severe, disabling lacerating pain in the right side of his face activated by numerous facial stimuli, rated it as a 10/10	Normal findings on both CT and MRI	Treatment with tramadol, pregabalin, and B12 complex was started; chlorpromazine and carbamazepine were added and his course evolved with sporadic pain.
Lucena et al. [7] Patient 3	Trigeminal neuralgia with ophthalmic branch involvement (TN diagnosis was based on 4 out of 9 clinical criteria of the IHS)	Vitrectomy for lens luxated into the vitreous following blunt trauma	On postoperative day 7, severe, excruciating pain in the right side of his face, predominantly in his right eye, triggered with Valsalva's maneuver	Normal findings on both CT and MRI	Treatment with tramadol, pregabalin, and B12 complex was started. A good response to medical treatment was observed.
Jacobs-El et al. [8] One patient	Trigeminal neuralgia	Retrobulbar anesthesia for dropped lens fragments + 23G pars plana vitrectomy, endolaser, fluid-air exchange	Same night; intermittent "lancinating" pain lasting 30 s around the eye; became unbearable on postop day 1	Normal neurological examination, no vascular compression on MR/MRA	Gabapentin after TN diagnosis; pain decreased on day 3, resolved completely in 2 weeks; maintenance with medication, dose reduction attempts unsuccessful
Moses et al. [9] One patient	Trigeminal neuralgia	Unspecified surgery type	Severe, paroxysmal, neuralgic pains in and about his eye	Not reported	Diphenylhydantoin
Present case One patient	Painful post-traumatic trigeminal neuropathy (ICHD-3 13.1.2.3)	Pterygium excision with conjunctival autograft, complicated by SINS; amniotic membrane graft; conjunctival covering with pericardial patch	Approximately 3 months after the third surgery; continuous, severe periocular and dental pain with photophobia and headache; no identifiable trigger zone	Normal findings on both CT and MRI; rheumatological, serological and microbiological work-up negative; odontogenic causes excluded	Systemic pulse corticosteroid and topical cyclosporine/steroid for SINS, without relief of pain; pain remitted after oral gabapentin

characteristic of painful post-traumatic trigeminal neuropathy rather than of classical trigeminal neuralgia, and it is on this basis that the diagnosis was established.

A closer consideration of the surgical anatomy helps to explain why a lesion of a few square millimeters produced such disproportionate trigeminal morbidity. The anterior sclera, limbus and cornea are innervated by the nasociliary branch of the ophthalmic division (V1) through the long ciliary nerves, which run forward in the suprachoroidal space along the horizontal meridians and terminate in a dense perilimbal plexus, the entry zone for the nerve supply of the most densely innervated tissue of the human body [18, 19]. In our patient, excision, autograft harvesting, bipolar cauterization, suture placement and the subsequent scleral melting were all confined to this nasal perilimbal region. The surgical trauma may thus be regarded as a first hit, in which axonal transection was compounded by thermal destruction of the episcleral vascular plexus and the vasa nervorum accompanying the ciliary nerves. Notably, neither mitomycin C nor beta-irradiation was used and only topical anesthesia was administered, which localizes the injury to the ocular surface and distinguishes our case from the patient reported by Jacobs-El and Shaikh, in whom retrobulbar needle trauma was the presumed trigger [8].

The second and, in our view, decisive hit was the sustained immune-inflammatory environment of SINS. Necrotizing scleritis is characterized by immune complex deposition with occlusive microangiopathy of episcleral vessels and by marked upregulation of matrix metalloproteinases and pro-inflammatory cytokines [14, 20]. Loss of the episcleral microvascular supply may produce ischemic axonal degeneration analogous to vasculitic neuropathy, while proteolytic degradation of the scleral

matrix leaves denuded nerve endings exposed for months to a milieu rich in tumor necrosis factor-α, interleukin-1β, interleukin-6 and nerve growth factor, all of which drive peripheral sensitization [5, 21]. Sustained injury of this kind produces the neuroplastic changes that define painful post-traumatic trigeminal neuropathy: redistribution of voltage-gated sodium channels, ectopic discharge from microneuromas, upregulation of the α2δ-1 calcium channel subunit, and activation of satellite glial cells within the trigeminal ganglion [5, 21, 22]. Glial-mediated cross-excitation between neurons of different trigeminal divisions offers a plausible explanation for the maxillary (V2) distribution of our patient's dental pain despite an injury restricted to V1 territory [22, 23], and sensitization of the trigeminovascular pathway in the trigeminal nucleus caudalis accounts for the coexistence of photophobia and headache [24]. Once established, such changes render the pain largely independent of the inflammation that initiated it, which explains the otherwise paradoxical course in our patient: the scleral disease was controlled by corticosteroid and immunosuppressive therapy, whereas the pain remitted only after gabapentin, an α2δ ligand acting on neuropathic rather than inflammatory mechanisms, was introduced [5, 25].

We acknowledge that this mechanistic reconstruction remains inferential, and this constitutes the principal limitation of the present report. Sensory testing of the trigeminal territory was not formally documented, so the diagnosis rests on the pain phenotype, the temporal relationship to surgery and the treatment response rather than on objectively demonstrated sensory disturbance. Quantitative sensory testing, trigeminal reflex studies and in vivo confocal microscopy of the sub-basal nerve plexus, which can demonstrate nerve fiber loss and microneuromas in ocular neuropathic pain, were not performed, nor was the excised necrotic sclera examined histopathologically for nerve fiber degeneration [21, 25]. We therefore suggest that these investigations be considered in future cases of persistent pain following SINS, since they would allow the peripheral and central contributions proposed here to be demonstrated directly rather than inferred from the clinical course. It should also be noted that the absence of evidence for a systemic rheumatological disorder at the time of presentation does not exclude one that may declare itself later in the course, and continued follow-up is therefore warranted.

To the best of our knowledge, and on the basis of the literature search described above, this is the first report of painful post-traumatic trigeminal neuropathy arising as a late complication of SINS following PS. Although trigeminal neuropathic pain after ocular surgery has been described previously, all reported cases were paroxysmal and trigger-evoked, were classified as trigeminal neuralgia, and followed intraocular procedures (Table 1). Post-traumatic trigeminal neuropathy itself is well recognized after oral and maxillofacial procedures [4, 5]; what is novel here is its occurrence after extraocular surface surgery complicated by a sustained scleritic process. Physicians should be vigilant and consider this diagnosis in patients with persistent neuropathic pain following SINS, in addition to other complications known to date.

Abbreviations

SINS	Surgically induced necrotizing scleritis
TSN	Trigeminal sensory neuropathy
PS	Pterygium surgery
BCVA	Best corrected visual acuity
ESR	Erythrocyte sedimentation rate
CRP	C-reactive protein
ICHD-3	International classification of headache disorders, 3rd edition
MMC	Mitomycin-C
TN	Trigeminal neuralgia

Acknowledgements
None.

Author contributions
BK, NKB and BYT analyzed the patient data. BK, BYT, EK and interpreted findings. BK, NKB and BYT were major contributors in writing the manuscript. All authors read and approved the final manuscript.

Funding
Not applicable.

Data availability
All data supporting the results and conclusions of this study have been included in the manuscript. No additional datasets were generated or analyzed in this study. However, further details may be made available by the corresponding author upon reasonable request and subject to institutional and ethical approval, where applicable.

Declarations

Ethics approval and consent to participate
Ethics committee approval is not required for single case reports at our institution. The study was conducted in accordance with the principles of the Declaration of Helsinki, and written informed consent to participate was obtained from the patient.

Consent for publication
Written informed consent was obtained from the patient for the publication of her personal and clinical details, as well as any accompanying identifying images in this case report.

Competing interests
The authors declare no competing interests.

Author details
[1]Department of Ophthalmology, Derince Research and Educational Hospital, Kocaeli, Türkiye
[2]Department of Ophthalmology, University of Health Sciences, Beyoglu Eye Training and Research Hospital, Istanbul, Türkiye
[3]Department of Ophthalmology, Faculty of Medicine, Kocaeli University, Kocaeli, Türkiye

Received: 11 August 2026 / Accepted: 30 September 2026
Published online: 08 October 2026

References

1. Lyne AJ, Lloyd-Jones D. Necrotizing scleritis after ocular surgery. Trans Ophthalmol Soc U K (1962). 1979;99(1):146–9.
2. Jain V, Shome D, Natarajan S, Narverkar R. Surgically induced necrotizing scleritis after pterygium surgery with conjunctival autograft. Cornea. 2008;27(6):720–1. https://doi.org/10.1097/QAI.0b013e31815d2f27.
3. O'Donoghue E, Lightman S, Tuft S, Watson P. Surgically induced necrotising sclerokeratitis (SINS)--precipitating factors and response to treatment. Br J Ophthalmol. 1992;76(1):17–21. https://doi.org/10.1136/bjo.76.1.17.
4. Jerjes W, Upile T, Shah P, et al. Risk factors associated with injury to the inferior alveolar and lingual nerves following third molar surgery—revisited. Oral Surg Oral Med Oral Pathol Oral Radiol Endodontology. 2010;109(3):335–45. https://doi.org/10.1016/j.tripleo.2009.10.010.
5. Eliav T, Benoliel R, Korczeniewska OA. Post-Traumatic Trigeminal Neuropathy: Neurobiology and Pathophysiology. Biology. 2024;13(3):167. https://doi.org/10.3390/biology13030167.
6. Headache Classification Committee of the International Headache Society (IHS). The International Classification of Headache Disorders, 3rd edition. Cephalalgia. 2018;38(1):1–211. https://doi.org/10.1177/0333102417738202.
7. Lucena MDP, Furno Sola F, Torres Soriano ME, Gerster FA. Trigeminal neuralgia associated with ophthalmic surgery: a case series. J Med Case Rep. 2018;12(1):256. https://doi.org/10.1186/s13256-018-1795-8.
8. Jacobs-El NB, Shaikh S, RETINAL, SURGERY–INDUCED TRIGEMINAL, NEURALGIA. RETINAL Cases Brief Rep. 2013;7(1):67–8. https://doi.org/10.1097/ICB.0b013e318263d418.
9. Moses L. Postoperative trigeminal neuralgia–case report. Ophthalmic Surg. 1980;11(2):131–2.
10. Morley AMS, Pavesio C. Surgically induced necrotising scleritis following three-port pars plana vitrectomy without scleral buckling: a series of three cases. Eye. 2008;22(1):162–4. https://doi.org/10.1038/sj.eye.6702708.
11. Yamazoe K, Shimazaki-Den S, Otaka I, Hotta. Shimazaki. Surgically induced necrotizing scleritis after primary pterygium surgery with conjunctival autograft. OPTH Published online November 2011:1609. https://doi.org/10.2147/OPTH.S24885.
12. Gregory ME, Weir CR, Ramaesh K. Excision of Granulation Tissue and Free Conjunctival Autograft in the Management of Necrotizing Scleritis. Cornea. 2010;29(5):577–9. https://doi.org/10.1097/ICO.0b013e3181b532e5.
13. Rachitskaya A, Mandelcorn ED, Albini TA. An update on the cause and treatment of scleritis. Curr Opin Ophthalmol. 2010;21(6):463–7. https://doi.org/10.1097/ICU.0b013e32833f1060.
14. Galanopoulos A, Snibson G, O'Day J. Necrotising anterior scleritis after pterygium surgery. Aust N Z J Ophthalmol. 1994;22(3):167–73. https://doi.org/10.1111/j.1442-9071.1994.tb01712.x.
15. De La Maza MS, Foster CS. Necrotizing Scleritis after Ocular Surgery. Ophthalmology. 1991;98(11):1720–6. https://doi.org/10.1016/S0161-6420(91)32062-1.
16. Díaz-Valle D, Del Castillo JMB, Castillo A, Sayagués O, Bañares A, García-Sánchez J. Immunologic and Clinical Evaluation of Postsurgical Necrotizing Sclerocorneal Ulceration. Cornea. 1998;17(4):371. https://doi.org/10.1097/00003226-199807000-00005.
17. Beardsley RM, Suhler EB, Rosenbaum JT, Lin P. Pharmacotherapy of scleritis: current paradigms and future directions. Expert Opin Pharmacother. 2013;14(4):411–24. https://doi.org/10.1517/14656566.2013.772982.
18. Marfurt CF, Cox J, Deek S, Dvorscak L. Anatomy of the human corneal innervation. Exp Eye Res. 2010;90(4):478–92. https://doi.org/10.1016/j.exer.2009.12.010.
19. Müller LJ, Marfurt CF, Kruse F, Tervo TMT. Corneal nerves: structure, contents and function. Exp Eye Res. 2003;76(5):521–42. https://doi.org/10.1016/S0014-4835(03)00050-2.
20. Di Girolamo N, Lloyd A, McCluskey P, Filipic M, Wakefield D. Increased expression of matrix metalloproteinases in vivo in scleritis tissue and in vitro in cultured human scleral fibroblasts. Am J Pathol. 1997;150(2):653–66.
21. Rosenthal P, Borsook D. Ocular neuropathic pain. Br J Ophthalmol. 2016;100(1):128–34. https://doi.org/10.1136/bjophthalmol-2014-306280.
22. Hanani M, Spray DC. Emerging importance of satellite glia in nervous system function and dysfunction. Nat Rev Neurosci. 2020;21(9):485–98. https://doi.org/10.1038/s41583-020-0333-z.
23. Rosenthal P, Borsook D, Moulton EA. Oculofacial Pain: Corneal Nerve Damage Leading to Pain Beyond the Eye. Invest Ophthalmol Vis Sci. 2016;57(13):5285. https://doi.org/10.1167/iovs.16-20557.
24. Burstein R, Noseda R, Fulton AB. Neurobiology of Photophobia. J Neuroophthalmol. 2019;39(1):94–102. https://doi.org/10.1097/WNO.0000000000000766.
25. Dieckmann G, Goyal S, Hamrah P, Neuropathic Corneal Pain. Ophthalmology. 2017;124(11):S34–47. https://doi.org/10.1016/j.ophtha.2017.08.004.

Publisher's note

Springer Nature remains neutral with regard to jurisdictional claims in published maps and institutional affiliations.